

GASTRO-PROTECTION OF ATORVASTATIN IN INDOMETHACIN-INDUCED ULCER: ROLE OF TUMOR NECROSIS FACTOR-ALPHA AND PROSTAGLANDINSAZZA A.K. EL-SHEIKH¹, MOHAMED A. EL-MOSELHY *^{2,3}

1. Department of Pharmacology, Faculty of Medicine, Minia University, Egypt
 2. Department of Pharmacology and Toxicology, Ibn Sina National College for Medical Studies , Jeddah, Kingdom of Saudi Arabia
 3. Department of Pharmacology and Toxicology, Faculty of Pharmacy, Minia University, Egypt (Permanent address)
- * Author for correspondence: m_moselhy64@yahoo.com

This paper is available online at www.jprhc.in

ABSTRACT:

Using non-steroidal anti-inflammatory drugs as over-the-counter pain-killers may predispose to gastric ulcer as a side effect. The objective of this study is to investigate the possible benefit of a common statin used in hyperlipidemic patients; atorvastatin (AtoR), in ameliorating the ulcerogenic effect of indomethacin (IndoM), and to explore the possible mechanisms involved. AtoR (10 mg/kg/day) was administered orally for 7 days. At day 7, gastric ulcer was induced by a single dose of IndoM (40 mg/kg i.p.), with or without AtoR pre-treatment. IndoM induced gastric ulcer as evident by notable gastric ulceration in histopathological sections compared to normal control. Gastric tissue in rats receiving IndoM showed significantly higher oxidative stress markers as lipid peroxidation represented by increased malondialdehyde (MDA) content, with significant decrease in gastric tissue nitric oxide (NO) and prostaglandin E₂ (PGE₂) levels, as well as reduction in catalase and superoxide dismutase antioxidant enzymatic activities. In addition, IndoM induced inflammatory signs as shown by the significant increase in tumor necrosis factor-alpha (TNF- α) level assessed via ELISA. Pre-administration of AtoR significantly decreased ulcer index (16 \pm 1) compared to that of IndoM alone (34 \pm 2). In addition, AtoR restored normal gastric histological structure and reverted oxidative and inflammatory markers tested. AtoR confers gastro-protection against IndoM-induced ulceration via reducing gastric oxidative stress and increasing gastric NO and PGE₂ levels, as well as decreasing the inflammatory marker; TNF- α .

KEY WORDS: Atorvastatin, Indomethacin, Gastric ulcer, ProstaglandinE₂, TNF-

INTRODUCTION:

Gastric mucosa is considered as one of the first line barriers protecting the body from the hazards of ingested exogenous xenobiotics and microbes. One of the main factors that cause erosion of the epithelium lining the stomach, and eventually gastric ulceration, is the administration of non-steroidal anti-inflammatory drugs (NSAIDs) widely used as over-the-counter pain-killers¹. Nearly quarter of the chronic users of NSAIDs develop gastric ulceration², with higher incidence of gastric ulceration in patients using NSAIDs that non-selectively inhibit cyclooxygenase enzymes, as indomethacin (IndoM). One of the mechanisms through which IndoM can induce gastric ulceration is via oxidative stress caused by increased production of reactive oxygen species and lipid peroxidation products³. Other mechanisms for IndoM-induced gastric injury include suppressing the formation of prostaglandins, which trigger different gastric mucosal defense mechanisms, including stimulating mucus and bicarbonate secretion, elevating mucosal blood flow, increasing epithelial cell resistance to cytotoxic injury and suppress recruitment of leucocytes into mucosa⁽¹⁾. Prostaglandins can also inhibit the release of inflammatory mediators, as tumor necrosis factor (TNF)- α which promotes gastric epithelial cell apoptosis⁴.

Atorvastatin (AtoR) is a well-tolerated cholesterol-lowering statin, whose mechanism of action involves inhibiting 3-hydroxy-3-methylglutaryl coenzyme A (HMG-CoA) reductase, thus reducing cholesterol production via the mevalonate pathway⁵. We have previously shown that AtoR possess antioxidant and anti-inflammatory effects against doxorubicin-induced hepato-renal damage⁶. In the present study, we aim at investigating the possible gastro-protective effects of AtoR against IndoM-induced gastric ulceration, and to explore the possible mechanisms involved.

MATERIALS AND METHODS**Chemicals**

Atorvastatin was kindly provided by Eipico (Egypt). Indomethacin was purchased from Nile Co. (Egypt). Kits for the estimation of catalase (CAT) and superoxide dismutase (SOD) enzymatic activities were purchased from Biodiagnostic (Egypt). Prostaglandin E₂ (PGE₂) ELISA- kit was obtained from Cayman (USA) while TNF- α ELISA kit was purchased from WKEA-Med supplies Corp. (China). All other chemicals were of analytical grade and were obtained from commercial source.

Experimental procedures

Twenty four male Albino rats (180–200 g) were purchased from the National Research Centre, Giza, Egypt. Throughout the experiments, rats were housed in the standard animal facility (3 or 4 animals/cage) under normal laboratory conditions, with free access to standard rodent chow and water. All experimental procedures were conducted in accordance with the Institutional Animal Ethics Committee guidelines for animal care and use, Faculty of Medicine, Minia University, Egypt.

Animals were left to acclimatize for one week, after which they were divided into 3 groups (n=8 each). The first group served as the control group. In the second group, gastric ulcer was induced using a single intra-peritoneal (I.P.) dose of IndoM of 40 mg/kg⁷. The third group also received IndoM at the same described dose, but with prior administration of oral AtoR as a single daily dose of 10 mg/kg/day for 7 days by oral route (gastric gavage)⁶.

Macroscopic and microscopic examinations

The animals were sacrificed 3 hrs after IndoM treatment. Stomach tissues were excised, washed with ice-cold saline, opened along the greater curvature, re-washed by cold saline to remove gastric contents and blood clots. The macroscopical mucosal lesions was evaluated using gastric ulcer index (UI), where gastric mucosal lesions were counted, using a $\times 5$ magnifier lens to assess the formation of ulcers, and the mean lesion score for each group was calculated⁸. The gastric tissue was then divided into two parts. One part was kept frozen for biochemical evaluation of gastric injury assays in the scraped mucosa. The other portion was fixed in 10% buffered neutral formalin solution, dehydrated in gradual ethanol (70-100%), cleared in xylene, and embedded in paraffin. Five- μ m thick paraffin sections were prepared and then stained with hematoxylin and eosin (H&E) dyes for histological examinations.

Analysis of gastric mucosa biochemical parameters

Gastric scraped mucosal tissue content of lipid peroxides was determined by biochemical assessment of thiobarbituric acid reacting substance through spectrophotometric measurement of color at 535 nm (Beckman DU-64 UV/VIS spectrophotometer), using 1,1,3,3-tetramethoxypropane as standard⁹. The results were expressed as equivalents of malondialdehyde (MDA) in tissue homogenate in nmol/g tissue. Mucosal content of NO was also spectrophotometrically determined in tissue homogenate as described⁽¹⁰⁾ using copper-cadmium alloy as a reducing agent that reduces nitrate into stable nitrite (Gries reaction). The results were expressed as nmol/g tissue. Assessment of catalase antioxidant enzymatic activity was determined in tissue homogenate from the rate of decomposition of H₂O₂ at 510 nm by colorimetric kit. The results were expressed as unit/g tissue. Gastric mucosal SOD enzymatic activities were quantified according to the manufacturers' guidelines. The assay depended on the ability of SOD enzyme to inhibit the phenazine methosulphate-mediated reduction of nitroblue tetrazolium dye. The change in absorbance at 560 nm was measured over 5 min. SOD activity results were expressed in U/0.1 g tissue.

Evaluation of PGE₂ and TNF- level in gastric mucosal tissue

Production of PGE₂ in gastric tissue homogenate supernatant was determined using ELISA kit according to the manufacturer's instructions. Briefly, PGE₂ was converted into its stable derivative (Bicyclo PGE₂) which was measurable by the kit. The tissue supernatant and standards were added to a 96-well plate, pre-coated with goat polyclonal anti-mouse IgG. After incubation period with PGE₂ acetylcholinesterase conjugated with the PGE₂ Tracer, Ellman's reagent was applied for 60 min, yielding a distinct yellow color, which was measured using ELISA plate reader at 412 nm. Results were calculated using the standard curve which was expressed as pg/mg tissue. TNF- was also evaluated using a commercial ELISA kit according to manufacturer's instructions. Briefly, 10 μ l of tissue homogenate was dispensed in 40 μ l of sample diluent solution, mixed and incubated for 30 min at 37°C. The plate was washed for five times with 30-fold diluted wash buffer and dried. To each well, 50 μ l enzyme conjugate was added, incubated then washed as previously described. After drying the plate, 50 μ l of each of substrate A and B were added to each well and the plate was incubated for 15 min at 37°C. The reaction was stopped by adding 50 μ l stop solution. The plate was then read using ELISA plate reader at 450 nm.

Statistical analysis

The data was analyzed by one way ANOVA followed by Dunnett Multiple Comparison Test. The values are represented as means \pm S.E.M. All statistical analysis was done using GraphPad Prism (GraphPad Prism software, 2011). The differences were considered significant when the calculated P value is less than 0.05.

RESULTS:

Effect of atorvastatin on histological picture and gastric ulcer index in indomethacin-treated rats

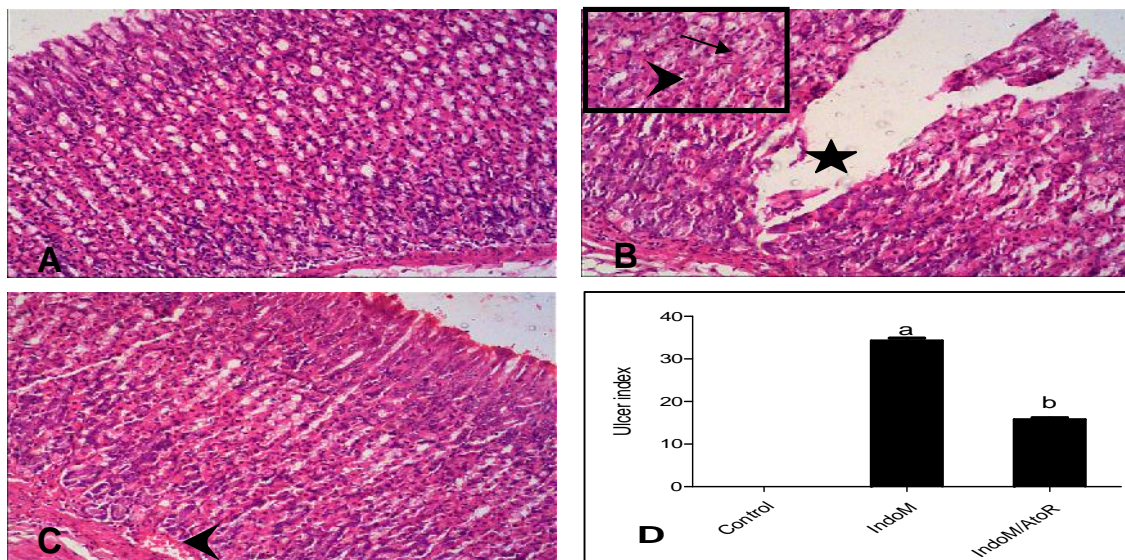
Control group showed no gastric ulceration, with normal gastric epithelial lining and lacked any vascular congestion or erythrocytic extravasation (Figure 1A). On the other hand, animal group receiving IndoM showed alteration in microscopic histological gastric architecture, with irregular thin gastric mucosa, vascular congestion, inflammatory cellular infiltration and erythrocyte extravasation (Figure 1B). Microscopic examination of gastric ulcers in this group showed disruption in gastric mucosal membrane continuity, with profound ulceration in gastric epithelium extending deep into the glandular layer. Pre-treatment with AtoR succeeded in restoring normal gastric histological structure (Figure 1C). The macroscopic picture

reflected similar results, where IndoM caused induction of gastric ulceration as shown by the significant increased in UI (34±2) compared to control (Figure 1D). Pre-administration of AtoR significantly decreased ulcer index (16±1) compared to animals receiving IndoM alone (P < 0.05).

Effect of atorvastatin on gastric oxidative stress markers in indomethacin-treated rats

In rats receiving IndoM alone, oxidative stress was evident in gastric mucosal tissue, as indicated by the significant increase of the lipid peroxidation product content (MDA), with significant decrease in gastric tissue NO levels, as well as diminished antioxidant enzymatic activities of catalase and SOD compared to control (Table 1). Pre-treatment with AtoR significantly reversed all oxidative stress markers tested compared to the group receiving IndoM alone (P < 0.05).

Figure 1: Effect of atorvastatin (AtoR) on histopathology of gastric tissues in indomethacin (IndoM)-induced gastric ulcer in rats



Microscopic picture of the stomach stained with hematoxylin and eosin (×100) showing: A- control group with normal gastric mucosa. B- IndoM-treated group with profound ulceration disrupting gastric surface epithelium and extending deep into the glandular layer (star). Areas without ulceration (insert) show irregular thin gastric mucosa, vascular congestion, inflammatory cellular infiltration (arrow) and erythrocyte extravasation (arrowhead). C- Combined IndoM/AtoR-treated group showing regular gastric mucosa, with mild erythrocyte extravasation (arrowhead). D- Graph showing ulcer index. The results are mean ± SEM for 8 animals/group. ^a Significant difference compared to control. ^b Significant difference compared from IndoM-treated group. Significant difference is reported when P < 0.05.

Table 1: Effect of atorvastatin (AtoR) on gastric catalase, superoxide dismutase (SOD) malondialdehyde (MDA) and nitric oxide (nitrite/nitrate) levels in rats exposed to indomethacin (IndoM).

	Control	IndoM	IndoM/AtoR
Catalase (U/g.tissue protein)	73.1 ± 3.6	37.8 ± 2.6 ^a	62.6 ± 3.2 ^b
SOD (U/g.tissue protein)	58.1 ± 2.7	30.4 ± 1.6 ^a	52.5 ± 1.9 ^b
MDA (nmol/g.tissue protein)	9.3 ± 0.6	35.8 ± 2.6 ^a	16.1 ± 1.6 ^b
Nitrite/nitrate(nmol/g.tissue protein)	26.9 ± 2.1	8.8 ± 0.8 ^a	20.9 ± 1.1 ^b

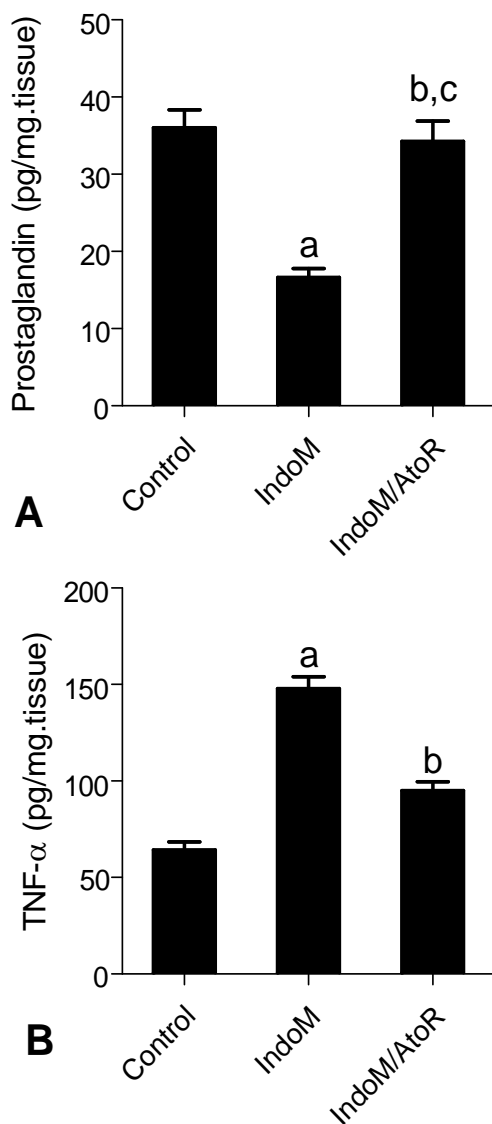
Values are represented as means ± SEM of 8 observations. ^a Significant difference compared to control, ^b significant difference compared to IndoM-treated group. Significant difference is reported when P < 0.05.

Effect of atorvastatin on gastric levels of PGE₂ and TNF- in indomethacin-treated rat

The IndoM-treated group showed induction of inflammatory signs as shown by the significant decrease in gastric tissue levels of PGE₂, accompanied by an increase in gastric TNF- concentration compared to control group (Figure 2).

Administration of AtoR prior to IndoM challenge significantly increased PGE₂, with decreasing TNF- compared to the group receiving IndoM alone (P < 0.05).

Figure 2: Effect of atorvastatin (AtoR) on tissue concentration of prostaglandin and tumor necrosis factor (TNF)- in indomethacin (IndoM)-induced gastric ulcer in rats.



The results are mean \pm SEM for 8 animals/group. ^a Significant difference compared to control. ^b Significant difference compared from IndoM-treated group. ^c No significant difference compared control untreated group. Significant difference is reported when P < 0.05.

DISCUSSION:

The NSAIDs; IndoM, is used to ameliorate pain, inflammation and hyperpyrexia, as well as to treat patent ductus arteriosus in neonates.¹¹ IndoM is also claimed to have some anticancer activity.¹² Despite its numerous advantages, IndoM causes upper gastrointestinal irritation amounting to ulcerations, which hinders its use. Due to its known gastric ulcerogenic effect, IndoM has been routinely applied to induce experimental animal model of acute gastric ulcer.^{2,3,7} In concurrence with previous studies, here, IndoM caused an increase in ulcer index and induced gastric oxidative stress, manifested by the increase in tissue lipid peroxidation product; MDA, with a decrease in gastric mucosal NO level, as well as SOD and catalase antioxidant enzymatic activity.¹³⁻¹⁷ In addition, in agreement with previous studies, IndoM stimulated gastric mucosal inflammatory pathways, evident by the decrease in PGE₂.^{18,19} and the increment of TNF- level.^{20,21}

In a previous study, we showed that the anti-hyperlipidemic drug; AtoR, possessed antioxidant and anti-inflammatory effects against doxorubicin-induced hepato-renal damage.⁶ Here, we confirm our findings, as AtoR, through antioxidant and anti-inflammatory mechanisms, conferred gastro-protective effects against IndoM-induced gastric ulcer. Interestingly, one previous study contradicted our findings, and showed that AtoR did not confer gastro-protection, but rather increased ulcer index.²² The reason for such discrepancy is probably due to the use of two- to four-folds higher doses of AtoR in the latter study than the dose used in the present study. Indeed, at higher doses, AtoR has been reported to cause gastrointestinal bleeding and may even induce colon carcinogenesis.²³ Antioxidant properties of AtoR has been reported to be beneficial to multiple vital organs, not only in conditions characterized by hypercholesterolemia²⁴ but also during normal lipid profile cases, where AtoR's antioxidant features may delay cardiac aging²⁵, ameliorate neuropathic pain²⁶ and protect the kidney and liver against cytotoxic drug-induced toxicity⁶. Another mechanism by which AtoR performs its pharmacological effects is through induction of NO synthesis by inducible form of nitric oxide synthase enzyme (iNOS), as seen in the heart²⁷ Here, we show for the first time that NO level in the gastric mucosa have been increased after AtoR pre-treatment, succeeding to significantly reversing the decreased NO level caused by IndoM. Some recent studies implicated that AtoR also had anti-inflammatory properties^{6,28}. AtoR was reported to ameliorate inflammatory pathways, as that of TNF- /NF- B in the diabetic patients²⁹ and high fat diet-induced stress³⁰. To date, the effect of AtoR on gastric mucosal pro-inflammatory cytokine; TNF-, has not yet been elucidated. Here, we showed that AtoR significantly decreased tissue level of TNF- in gastric mucosa.

Prostaglandins, especially PGE₂, are essential for mediating gastro-protective effects, and their production is thought to be downstream to induction of iNOS and the resultant increased NO formation.³¹ To our best knowledge, the current study is the first to report that AtoR administration causes increase in gastric mucosal PGE₂. Interestingly, AtoR seems to have

differential effect on PGE₂, as it was reported to decrease elevated PGE₂ in patients with coronary artery disease patients³² and Sjögren's syndrome³³, while it increased PGE₂ in the myocardium³⁴. The cross-talk between various antioxidant, nitrosative and anti-inflammatory mechanistic pathways is not easy to explain³⁵, indicating a multi-factorial reasons for AtoR-induced gastro-protection.

CONCLUSION:

AtoR confers gastro-protection against IndoM-induced ulcerations through different mechanisms, including ameliorating oxidative stress, increasing mucosal NO and PGE₂, as well as decreasing the pro-inflammatory cytokine; TNF- .

Conflicts of interest: None.

The abstract of the present work was accepted for poster presentation at the Annual Meeting of the Egyptian Society of Pharmacology and Experimental Therapeutics (ESPET) conference, British University, El-Sherouk, Egypt, 13 April 2013. The abstract was published at: Azza A.K. El-Sheikh, Mohamed A. El-Moselhy. Gastro-protection of Atorvastatin in Indomethacin-induced Ulcer: Role of Tumor Necrosis Factor-alpha and Prostaglandins. *Egyptian Journal of Basic and Clinical Pharmacology*, 3(1): 29, 2013.

REFERENCES:

1. Mohamed A. Morsy and Azza A.K. El-Sheikh. Prevention of Gastric Ulcers. In: Peptic Ulcer Disease. Chai J (Ed.), InTech, Croatia, 2011. ISBN 978-953-307-976-9 <http://www.intechopen.com/articles/show/title/prevention-of-gastric-ulcers>.
2. Lanza FL, Chan FK, Quigley EM. Guidelines for prevention of NSAID-related ulcer complications. *Am J Gastroenterol*. 2009;104:728-738.
3. Morsy MA, Ashour OM, Fouad AA, Abdel-Gaber SA. Gastroprotective effects of the insulin sensitizers rosiglitazone and metformin against indomethacin-induced gastric ulcers in Type 2 diabetic rats. *Clin Exp Pharmacol Physiol*. 2010;37:173-177.
4. Abdelwahab SI. Protective mechanism of gallic acid and its novel derivative against ethanol-induced gastric ulcerogenesis: Involvement of immunomodulation markers, Hsp70 and Bcl-2-associated X protein. *Int Immunopharmacol*. 2013;16:296-305.
5. Athyros VG, Tziomalos K, Karagiannis A, Mikhailidis DP. Atorvastatin: safety and tolerability. *Expert Opin Drug Saf*. 2010;9:667-674.
6. El-Moselhy MA, El-Sheikh AA. Protective mechanisms of atorvastatin against doxorubicin-induced hepato-renal toxicity. *Biomed Pharmacother*. 2014;68:101-110.
7. El-Moselhy MA, Abdel-Hamid NM, Abdel-Raheim SR. Gastroprotective effect of nicorandil in indomethacin and alcohol-induced acute ulcers. *Appl Biochem Biotechnol*. 2009;152:449-459.
8. Peskar BM, Ehrlich K, Peskar BA. Role of ATP-sensitive potassium channels in prostaglandin-mediated gastroprotection in the rat. *J Pharmacol Exp Ther*. 2002;301:969-974.
9. Buege JA, Aust SD. Microsomal lipid peroxidation. *Methods Enzymol*. 1978;52:302-310.
10. Sastry KV, Moudgal RP, Mohan J, Tyagi JS, Rao GS. Spectrophotometric determination of serum nitrite and nitrate by copper-cadmium alloy. *Anal Biochem*. 2002;306:79-82.
11. Pacifici GM. Clinical pharmacology of indomethacin in preterm infants: implications in patent ductus arteriosus closure. *Paediatr Drugs*. 2013;15:363-376.
12. Hull MA, Gardner SH, Hawcroft G. Activity of the non-steroidal anti-inflammatory drug indomethacin against colorectal cancer. *Cancer Treat Rev*. 2003;29:309-320.
13. Olaleye SB, Farombi EO. Attenuation of indomethacin- and HCl/ethanol-induced oxidative gastric mucosa damage in rats by kolaviron, a natural biflavonoid of *Garcinia kola* seed. *Phytother Res*. 2006;20:14-20.
14. Bhattacharya S, Banerjee D, Bauri AK, Chattopadhyay S, Bandyopadhyay SK. Healing property of the Piper betel phenol, allylpyrocatechol against indomethacin-induced stomach ulceration and mechanism of action. *World J Gastroenterol*. 2007;13:3705-3713.
15. Ajeigbe KO, Olaleye SB, Oladejo EO, Olayanju AO. Effect of folic acid supplementation on oxidative gastric mucosa damage and acid secretory response in the rat. *Indian J Pharmacol*. 2011;43:578-581.
16. Morsy MA, El-Moselhy MA. Mechanisms of the protective effects of curcumin against indomethacin-induced gastric ulcer in rats. *Pharmacology*. 2013;91:267-274.
17. Moustafa YM, Khoder DM, El-Awady EE, Zaitone SA. Sildenafil citrate protects against gastric mucosal damage induced by indomethacin in rats. *Eur Rev Med Pharmacol Sci*. 2013;17:179-188.
18. Takeuchi K. Pathogenesis of NSAID-induced gastric damage: importance of cyclooxygenase inhibition and gastric hypermotility. *World J Gastroenterol*. 2012;18:2147-2160.
19. Chatterjee A, Chatterjee S, Das S, Saha A, Chattopadhyay S, Bandyopadhyay SK. Ellagic acid facilitates indomethacin-induced gastric ulcer healing via COX-2 up-regulation. *Acta Biochim Biophys Sin (Shanghai)*. 2012;44:565-576.
20. Moustafa YM, Khoder DM, El-Awady EE, Zaitone SA. Sildenafil citrate protects against gastric mucosal damage induced by indomethacin in rats. *Eur Rev Med Pharmacol Sci*. 2013;17:179-188.
21. Abbas AM, Sakr HF. Effect of selenium and grape seed extract on indomethacin-induced gastric ulcers in rats. *J Physiol Biochem*. 2013;69:527-537.
22. Ozbakis-Dengiz G, Hekimoglu A, Kandemir N, Kurcer Z. Effects of statins in an indomethacin-induced gastric injury model in rats. *Turk J Gastroenterol*. 2012;23:456-462.

23. Guan F, Liu AB, Li G, Yang Z, Sun Y, Yang CS, Ju J. Deleterious effects of high concentrations of (-)-epigallocatechin-3-gallate and atorvastatin in mice with colon inflammation. *Nutr Cancer*. 2012;64:847-855.
24. Amin KA, Abd El-Twab TM. Oxidative markers, nitric oxide and homocysteine alteration in hypercholesterolemia rats: role of atorvastatin and cinnamon. *Int J Clin Exp Med*. 2009;2:254-265.
25. Han L, Li M, Liu Y, Han C, Ye P. Atorvastatin may delay cardiac aging by upregulating peroxisome proliferator-activated receptors in rats. *Pharmacology*. 2012;89:74-82.
26. Pathak NN, Balaganur V, Lingaraju MC, Kant V, Latief N, More AS, Kumar D et al. Atorvastatin attenuates neuropathic pain in rat neuropathy model by down-regulating oxidative damage at peripheral, spinal and supraspinal levels. *Neurochem Int*. 2014;68:1-9.
27. Atar S, Ye Y, Lin Y, Freeberg SY, Nishi SP, Rosanio S, Huang MH et al.. Atorvastatin-induced cardioprotection is mediated by increasing inducible nitric oxide synthase and consequent S-nitrosylation of cyclooxygenase-2. *Am J Physiol Heart Circ Physiol*. 2006;290:H1960-H1968.
28. Ghaisas MM, Dandawate PR, Zavar SA, Ahire YS, Gandhi SP. Antioxidant, antinociceptive and anti-inflammatory activities of atorvastatin and rosuvastatin in various experimental models. *Inflammopharmacology*. 2010;18:169-177.
29. Mandosi E, Fallarino M, Gatti A, Carnovale A, Rossetti M, Lococo E, Buchetti B et al. Atorvastatin downregulates monocyte CD36 expression, nuclear NFkappaB and TNFalpha levels in type 2 diabetes. *J Atheroscler Thromb*. 2010;17:539-545.
30. Kesh SB, Sikder K, Manna K, Das DK, Khan A, Das N, Dey S. Promising role of ferulic acid, atorvastatin and their combination in ameliorating high fat diet-induced stress in mice. *Life Sci*. 2013;92:938-949.
31. El-Abhar HS. Coenzyme Q10: a novel gastroprotective effect via modulation of vascular permeability, prostaglandin E(2), nitric oxide and redox status in indomethacin-induced gastric ulcer model. *Eur J Pharmacol*. 2010;649:314-319.
32. Gomez-Hernandez A, Sanchez-Galan E, Ortego M, Martin-Ventura JL, Blanco-Colio LM, Tarin-Vicente N, Jimenez-Nacher JJ et al.. Effect of intensive atorvastatin therapy on prostaglandin E2 levels and metalloproteinase-9 activity in the plasma of patients with non-ST-elevation acute coronary syndrome. *Am J Cardiol*. 2008;102:12-18.
33. Reina S, Passafaro D, Sterin-Borda L, Borda E. Atorvastatin inhibits the inflammatory response caused by anti-M(3) peptide IgG in patients with primary Sjogren's syndrome. *Inflammopharmacology*. 2012;20:267-275.
34. Birnbaum Y, Ye Y, Rosanio S, Tavackoli S, Hu ZY, Schwarz ER, Uretsky BF. Prostaglandins mediate the cardioprotective effects of atorvastatin against ischemia-reperfusion injury. *Cardiovasc Res*. 2005;65:345-355.
35. Taye A, El-Sheikh AA. Lectin-like oxidized low-density lipoprotein receptor 1 pathways. *Eur J Clin Invest*. 2013;43:740-745.

Contribute your research to Asian J Pharmaceut Res Health Care

- No publication fees/processing fees collected from authors/institutes.
- Articles are repositied in DOAJ and Bielefeld Academic Search Engine.
- Strict adherence to international guidelines on editorial processes and ethics.
- This is RoMEO green publisher(Authors can archive their published PDF)