

# Full Mouth Rehabilitation of a Patient with Restorative Space Issues - A Case Report

**Narendra Basutkar<sup>1\*</sup>, Renad Khalid Alamoudi<sup>2</sup> and Reem Mohammed Alharbi<sup>2</sup>**

<sup>1</sup>Assistant Professor, Prosthodontics Division, Department of Oral and Maxillofacial Rehabilitation, Ibn Sina National College for Medical Studies, Jeddah – 22421, Saudi Arabia; docnaren28feb@ibnsina.edu.sa

<sup>2</sup>Dental Intern, Dentistry Program, Ibn Sina National College for Medical Studies, Jeddah – 22421, Saudi Arabia; renad.k.alamoudi@gmail.com, dr.reem.alharbii@gmail.com

## Abstract

Restorative space refers to the amount of space needed vertically and horizontally between the occluding surface of the teeth and between the crest of the residual ridge so that the prosthesis (fixed and/or removable) can be fabricated without compromising their strength and esthetics. Inadequate restorative space can result in prosthetic rehabilitation with poor esthetics, inadequate contours, and decreased stability. Therefore the amount of available restorative space must be carefully assessed prior to initiating prosthetic treatment. Optimal restoration of a patient with restorative space issues depends on several interdependent factors such as the amount of restorative space available, amount of restorative space required for the proposed dental restorations and prosthesis, quality, and quantity of remaining dentition and residual alveolar ridge and esthetic and functional patient demands. Accurate clinical and radiographic examinations, careful determination of VDO and systematic treatment planning using a diagnostic wax-up is key to predictable and successful treatment for patients with restorative space issues. This case report presented here to discuss the challenges and management of a patient with inadequate restorative space.

**Keywords:** Full Mouth Rehabilitation, Restorative Space, Teeth Wear, Treatment Planning, Vertical Dimension

## 1. Introduction

Restorative space refers to the amount of space needed vertically and horizontally between the occluding surface of the teeth and between the crest of the residual ridge so that the restorations (fixed and/or removable) can be fabricated without compromising their strength and esthetics. Amount of available restorative space must be carefully assessed prior to initiating prosthetic treatment.

In fixed prosthodontics, the restorative space can be related to the commonly used term interocclusal clearance which refers to the amount of reduction achieved during tooth preparation to provide for the adequate thickness of restorative material<sup>1</sup>. In removable prosthodontics restorative space could be closely related

to the term interalveolar space/interarch distance/inter-ridge distance which refer to the vertical distance between the maxillary and mandibular dentate or edentulous arches under specified conditions<sup>1</sup>.

Reduced restorative space can be seen in patients showing the gradual wearing of teeth wherein compensatory eruption of teeth and alveolar processes occur to maintain occlusal contact resulting in no loss of vertical dimension of occlusion (VDO)<sup>3,4</sup>. Occlusal wear can be physiologic resulting in gradual minimum attrition during the lifetime of the patient. Pathological wear can be attributed to congenital anomalies (like amelogenesis imperfecta, dentinogenesis imperfecta) and parafunctional habits (bruxism, abrasion, erosion etc.). Pathologic wear can result in severe occlusal wear, pulpal pathology, occlusal

\*Author for correspondence

disharmony, impaired function, and esthetics. Growing consensus can be seen among researchers that tooth wear may be a result of a combination of etiological factors<sup>2</sup>. If diagnosed early, most of the occlusal wear cases require minimal intervention and monitoring for life may be sufficient. Active restorative intervention may be required for severe wear cases with esthetic and functional problems.

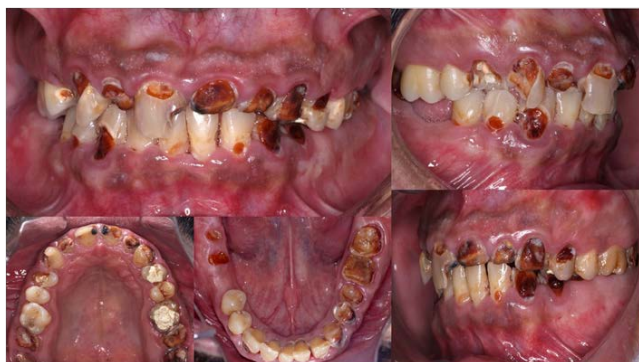Optimal rehabilitation of a patient with restorative space issues depends on several interdependent factors such as the amount of restorative space available, amount of restorative space required for the proposed dental restorations and prosthesis, quality, and quantity of remaining dentition and residual alveolar ridge and esthetic and functional patient demands.

According to the three categories described by Turner and Missirilian<sup>5</sup> for patients presenting with generalized tooth wear. Category 1 – excessive wear with loss of vertical dimension of occlusion, Category 2 – excessive wear without loss of vertical dimension, but with restorative space available, and Category 3 – excessive wear without loss of vertical dimension, but with limited restorative space.

Accurate clinical and radiographic examinations, careful determination of VDO and systematic treatment planning using a diagnostic wax-up is key to predictable and successful treatment for patients with restorative space issues. This case report presented here discusses the challenges and management of a patient with inadequate restorative space.

## 2. Case Presentation

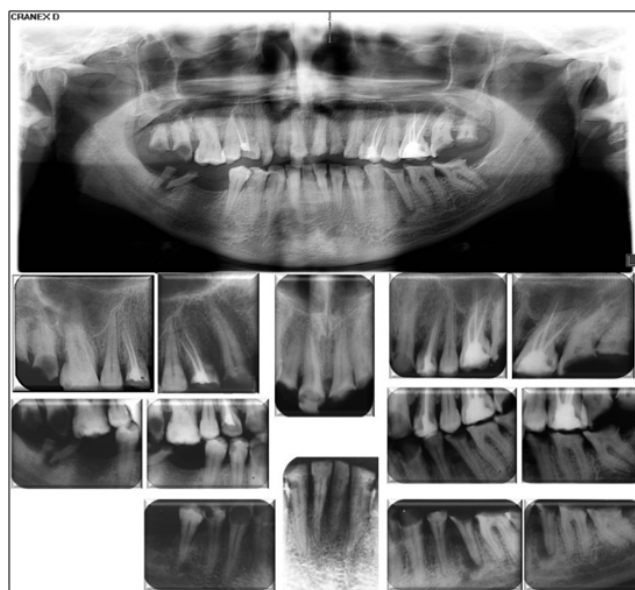
A 32-year-old male patient presented to comprehensive care clinics at Ibn Sina National College for medical studies, Jeddah, Saudi Arabia. The patient complained



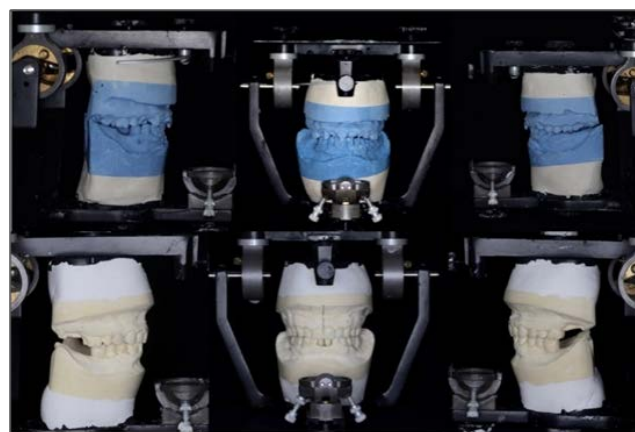
**Figure 1.** Pre-operative intra oral pictures.

of poor esthetics and reduced mastication ability. The patient gave a history of a car accident resulting in a crown fracture in some of his maxillary anterior teeth. He sought dental treatment at private clinics but left it as he could not afford it. He neglected his oral hygiene for many years and the situation progressed to the current condition. His pre-operative condition can be seen in (Figure 1).

OPG and Full mouth periapical radiographs can be seen in (Figure 2). The diagnostic cast was generated and mounted on Hanau semi adjustable articulator using face bow (Figure 3). Inadequate restorative space in the 3<sup>rd</sup> quadrant was obvious on the cast due to continued eruption of worn and carious mandibular molars 36 and 37.



**Figure 2.** OPG and Intra oral periapical radiographs.



**Figure 3.** Diagnostic casts and wax up.

The patient was motivated for good oral hygiene practices. A preliminary treatment plan was formulated and discussed with the patient. Informed patient consent was taken. Treatment was rendered according to phases.

Preliminary phase involved extraction of Teeth numbers 18,17,27,28,47 as they were grossly decayed with no remaining coronal tooth structure. Teeth numbers 36 and 37, which were worn down to gingival crest level along supra eruption were also considered for extraction because of non-restorability. Along with extraction alveoloplasty was planned to provide restorative space for the planned removable prosthesis for the lower arch (Figure 4).

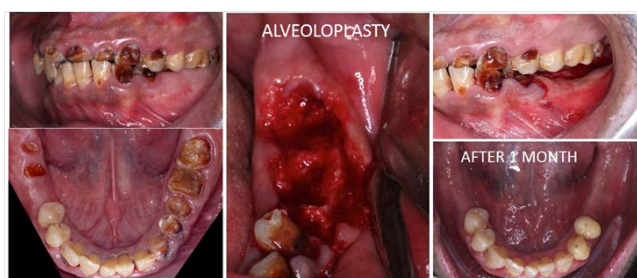

Figure 4. Extraction and Alveoloplasty.

Non-surgical phase (Phase I) was started 4 weeks after extraction. It consisted of scaling and root planning and non-surgical periodontal management using antimicrobial therapy with chlorhexidine mouth wash. Caries control, glass ionomer cement temporization was done and a transient removable acrylic partial denture was fabricated.

Surgical phase (Phase II) consisted of Non-surgical root canal treatment for teeth number #11,12,13,14,21,22,23,24,26,33 and 43. Periodontal surgical lengthening of maxillary anterior teeth was performed to achieve adequate ferrule and zenith correction to achieve pleasing esthetics was done (Figure 5).

Restorative phase (Phase III) consisted of Fiber post (3M) and composite core build up (Multicore, Ivoclar) for teeth number #11,12,13,14,21,22,23,33,34 (Figure 6). Crown preparation with teeth number 11,12,13,14,21,22,23 and 24 was done to receive All-ceramic (E max) crowns (Figure 7). All-ceramic crowns were cemented using resin cement (Relyx, 3M). Teeth number 33 and 34 were prepared to receive porcelain fused to metal surveyed crown. Mandibular metal removable

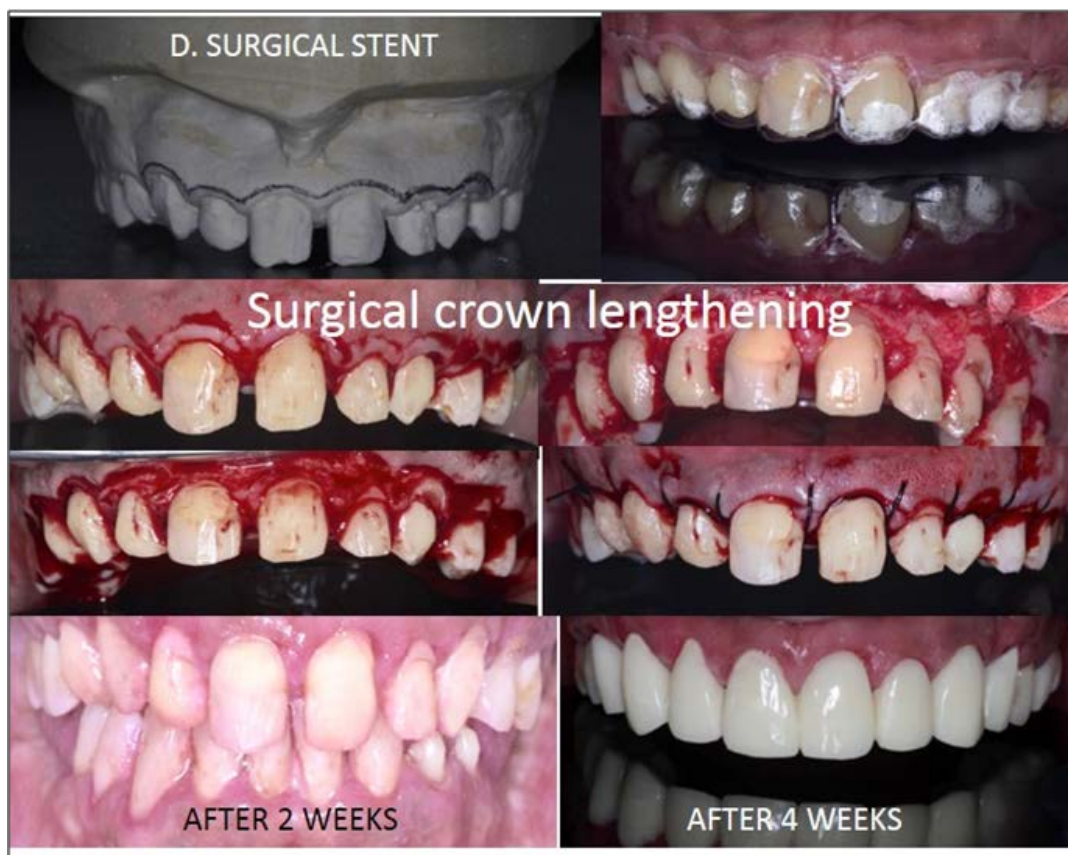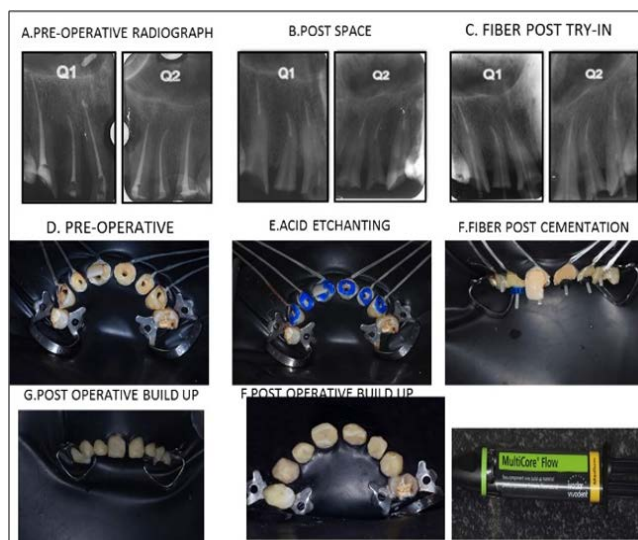


Figure 5. Surgical Crown lengthening.

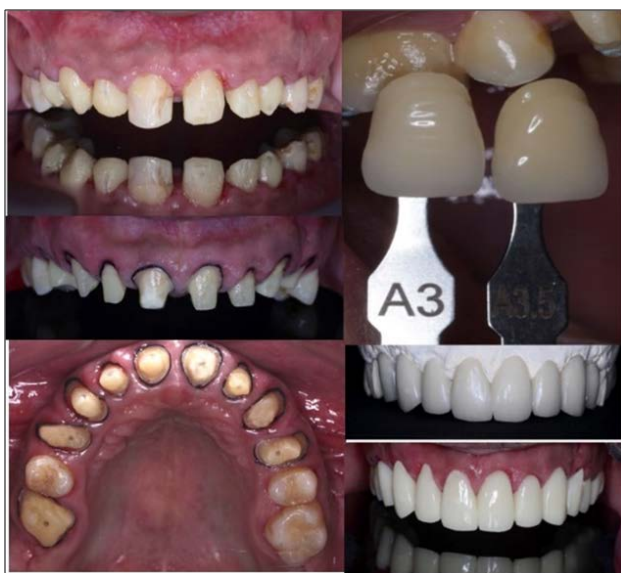partial denture was fabricated. Post-operative picture can be seen (Figure 8 & 9). Oral hygiene instructions were reinforced to the patient. Patient was recalled after 4 weeks. Overall oral hygiene, partial denture hygiene, crown margins and occlusion were evaluated.

### 3. Discussion

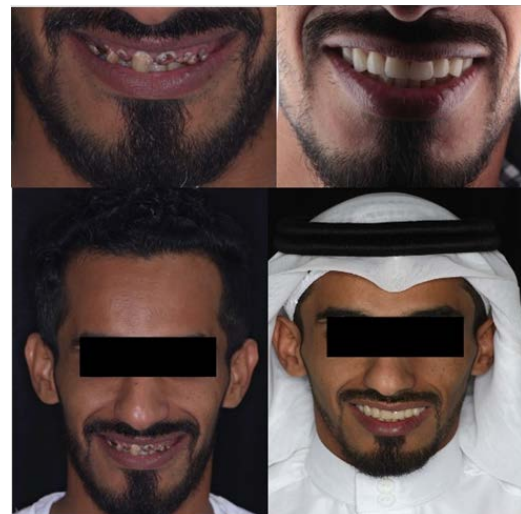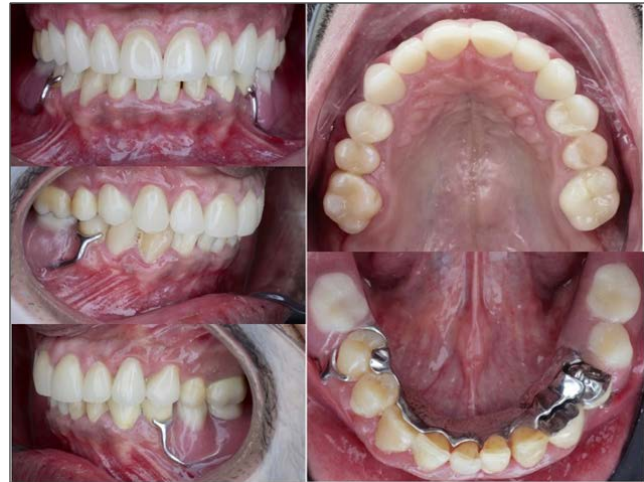Accurate clinical and radiographic examinations, careful determination of VDO and systematic treatment planning using a diagnostic wax-up is key to predictable and successful treatment for patients with restorative space issues.



**Figure 6.** Post and core build up.



**Figure 7.** Teeth preparation and temporization.



**Figure 8 and 9.** Post operative pictures.

Some of the key points to be considered during comprehensive evaluation of VDO is the nature of posterior teeth support available, history of duration of teeth wear, phonetic evaluation, evaluation of Vertical Dimension at Rest (VDR) and facial appearance. Loss of *posterior teeth support* resulting from missing, tipped, rotated, and broken down teeth results in loss of VDO. This, in turn, places undue stress on the anterior segment which eventually becomes mobile or wears excessively<sup>6</sup>. *History of wear*: Generally gradual occlusal wear over many years is compensated by the continuous eruption of teeth along with its alveolar support. VDO is lost when there is accelerated breakdown and wear which exceeds the rate of the eruption. *Phonetic evaluation*: Closest speaking space described by Silverman and Pound successfully evaluate the VDO under function. The normal mandibular position during the/S/sound places the incisal edge of the

mandibular incisors about 1 mm inferior and lingual to the incisal edge of the maxillary incisors<sup>7,8</sup>. *Interocclusal distance*: Niswonger<sup>9</sup> proposed method to determine VDO by measuring VDR. He reported that VDR remains constant throughout life. Interocclusal distance/Freeway space of 2 to 4 mm was found adequate. But the methods of measuring interocclusal distance are diverse, inaccurate, and inconsistent and subjective in nature<sup>10</sup>. Therefore these readings should be used carefully. *Facial appearance*: Loss of VDO results in thin lips with narrow vermilion borders, drooping commissures associated with overclosure<sup>11</sup>. Hence clinical judgment plays a major role in the assessment of VDO in rehabilitation.

In this patient, after careful evaluation of the VDO, it was observed that VDO was maintained. Loss of posterior teeth due to gradual wearing had resulted in continued eruption. Phonetic evaluation of 'S' sound showed ideal positioning of the lower incisors in relation to maxillary anterior, with the closest speaking space of about 1 to 2 mm. Inter occlusal space was also about 3 mm when the patient's mandible was in the rest position. According to Turner and Missirilian<sup>5</sup> our patient was categorized in Category 3: excessive wear without loss of vertical dimension, but with limited restorative space.

Regaining the restorative space by increasing the VDO was ruled out. A combination of methods including alveoloplasty, enameloplasty, intentional endodontic therapy, and occlusal plane alteration and surgical crown lengthening procedures to provide adequate retention and resistance form for the teeth preparations were considered. Orthodontic repositioning could be considered but ruled out as it requires 6 to 12 months.

A transient acrylic RPD was planned in phase I of the treatment. The objective was to provide a posterior occlusal table for better mastication, to relieve anterior teeth of undue stresses from occlusion and also to condition the patient for using the removable prosthesis.

Periodontal surgical crown lengthening was planned in this case as caries in the maxillary anterior teeth were extending subgingival. Other objectives that were achieved through the periodontal surgery were to expose adequate clinical crown length for better esthetics, to place the finish lines on the sound tooth structure, and to get adequate ferrule effect.

Sufficient interocclusal space for dental materials can usually, be obtained by altering the contours of opposing restorations and/or tooth structure as described by Dawson<sup>12</sup>. The fact that most of the teeth were

endodontically treated allowed us to correct occlusal plane alterations which were due to continuous eruption of teeth. Enameloplasty and uneven occlusal surface reductions were done to achieve proper restorative space required for the All-ceramic crowns.

In extreme cases of restorative space inadequacies, surgical repositioning of a segment of teeth and supporting alveolus may be indicated if a dentofacial deformity exists in conjunction with extreme wear. A LeFort I procedure combined with sectioning the anterior and posterior segments, is a technique used for treating patients with open anterior occlusion<sup>13</sup>. Surgical repositioning should be considered only after a thorough evaluation of diagnostic data that includes preoperative cast dissection, facial dimension, surgical complications, and benefits derived.

The increasing vertical dimension of occlusion should be avoided when there is no apparent loss of VDO. If deemed necessary, only a minimum increase should be considered for restorative needs only. Transient restorations like cemented provisional crowns or removable acrylic prostheses should be evaluated for a long period of time to ensure patient comfort and accommodation to the increase in VDO. Patients should be monitored frequently during postoperative follow-up visits. A thorough occlusal evaluation and signs of wear and masticatory muscle fatigue should be looked for.

Patient was monitored frequently for up to 6 months during post treatment follow-up visits. Patient reported high satisfaction with esthetics and function. A protective soft night-guard was fabricated for the patient as a preventive measure to prevent wearing and chipping of natural teeth and ceramic restorations.

## 4. Conclusion

Restoration of patients with inadequate restorative space issues presents a challenge to the dentist. VDO should be carefully evaluated. Causes for VDO loss, history should be considered to appropriately plan treatment. Multidisciplinary team approach that uses combined expertise will ensure the longevity of the treatment rendered.

## 5. Acknowledgements

Authors would like to thank the entire dental faculty at Ibn Sina National College for medical studies, for

their guidance and support during the execution of the treatment. Special thanks to Dr. Syed Mouaz Ur Rahaman, department of periodontics, for his guidance and expertise in periodontal surgery.

## 6. References

1. The Glossary of Prosthodontic Terms (GPT). J. Prosthet. Dent. 2017; 117 (5): e1-e105 DOI: <https://doi.org/10.1016/j.prosdent.2016.12.001>
2. Crothers AJR. Tooth wear and facial morphology. J. Dent 1992; 20:333-41 [https://doi.org/10.1016/0300-5712\(92\)90019-9](https://doi.org/10.1016/0300-5712(92)90019-9).
3. Sicher H. Oral Anatomy, Ed 5. St. Louis. The C.V. Mosby co.; 1949. P. 270.
4. Berry D, Poole D. Attrition: Possible mechanisms of compensation. J. Oral Rehabil. 1976; 30: 201-06. <https://doi.org/10.1111/j.1365-2842.1976.tb00945.x>. PMID: 1068232.
5. Turner K, Missirilian D. Restoration of the extremely worn dentition. J. Prosthet. Dent. 1984; 52:467-74. [https://doi.org/10.1016/0022-3913\(84\)90326-3](https://doi.org/10.1016/0022-3913(84)90326-3).
6. Stern N, Brayer L. Collapse of the occlusion – Aetiology, symptomatology and treatment. J. Oral Rehabil. 1975; 2(1):1-19. <https://doi.org/10.1111/j.1365-2842.1975.tb00907.x>. PMID: 1056439.
7. Pound E. The mandibular movements of speech and their seven related values. J. South Calif. Dent. Assoc. 1966; 34(9):435-41.
8. Silverman MM. The speaking method in measuring vertical dimension. J. Prosthet. Dent. 1953; 3:193. [https://doi.org/10.1016/0022-3913\(53\)90127-9](https://doi.org/10.1016/0022-3913(53)90127-9).
9. Niswonger ME. The rest position of the mandible and the centric relation. J. Am. Dent. Assoc. 1934; 21(9):1572-82. <https://doi.org/10.14219/jada.archive.1934.0258>.
10. Atwood DA. A cephalometric study of the clinical rest position of the mandible. J. Prosthet. Dent. 1956; 6:504-19. [https://doi.org/10.1016/0022-3913\(56\)90094-4](https://doi.org/10.1016/0022-3913(56)90094-4).
11. Hearrwell CM, Jr and Kahn AO. Syllabus of Complete Dentures, Ed. 3<sup>rd</sup>. Philadelphia, 1980. Lea & Fcbigr. Publishers, 558 pages.
12. Peter E Dawson. Evaluation, Diagnosis and Treatment of Occlusal Problems, Ed. 2<sup>nd</sup>. St. Louis: C.V. Mosby; 1989.
13. Bell WH, Proffit WR, White RP. Surgical Correction of Dentofacial Deformities, Ed. 1<sup>st</sup>, Vol 2. Philadelphia: Saunders; 1980.