

BOOK REVIEWS

to work as a professor of physics in the University of Arizona at Tuscan. It is interesting to note that the Head of the Department of Physics in the University was an Indian, Sumit Mazumdar who gave him all the support needed to work. Lizhi published 162 research papers while in Tuscan and helped many Chinese students to come to USA to work with him. He worked for about twenty years in Tuscan and died due to 'valley fever', a rare lung disease of the American desert.

Lizhi had two sons – Fang Ke and Fang Zhe. They could not go with their parents to the US when they escaped from China. The children were sent to the US after a great deal of effort made by several Lizhi's friends. Most unfortunately, one of his sons, Zhe, was killed in a car accident when he was only 16 years old.

The book contains a foreword and an epilogue, rather a long one, both written by Link. The main book ends with the flight of the Lizhis to America in 1990. Link describes in the epilogue the life and work of Lizhi in America from the time of his arrival till the time of his death in 2012.

Link writes, 'Some people call Fang Lizhi China's Sakharov, and that is fine. According to some others Fang and the Communist party of China are more like Galileo and the Roman church. An astrophysicist against powerful and arbitrary authority; the authority persecutes the physicist, but the physicist gets the truth right'.

The book describes vividly the troubles faced by scientists and intellectuals during the communist regime of China, especially in a period famously called the 'cultural revolution'. Mao Zedong treated intellectuals with great disdain, at times describing them as 'intellectuals are short on intellect because they can't plant crops or slaughter pigs'. After reading this book, it appears that the conditions for doing science were far better in India. When modern science arrived in India, the British treated the Indian scientists with dignity. The Indian scientists should appreciate that modern science in the real sense came to India with the British and that the rulers never came in the way of scientific pursuit, nor did they harass any scientist. Even the nationalists like Jagdish Chandra Bose and Prafulla Chandra Ray could carry out their work without any hindrance. Significantly, it

was an Englishman of the Madras Port Trust, Sir Francis Spring, who encouraged S. Ramanujan and arranged to send him to G. H. Hardy in Cambridge. It is because of Hardy's initiative that Ramanujan could do his epoch-making work in mathematics and attain world fame. After the British left India, the subsequent Indian governments, especially under the leadership of Jawaharlal Nehru, helped and encouraged scientists to develop and promote science in India.

CHINTAMANI MANDE
SHEKHAR C. MANDE*

*National Centre for Cell Science,
Ganeshkhind,
Pune 411 007, India
e-mail: shekhar@nccs.res.in

Annual Review of Pathology: Mechanisms of Disease, 2015. Abul K. Abbas, Stephen J. Galli and Peter M. Howley (eds). Annual Reviews, 4139 El Camino Way, P.O. Box 10139, Palo Alto, California 94303-0139, USA. Vol. 10. viii + 576 pp. Price: US\$ 65. ISBN978-0-8243-4310-1

What can be said about the *Annual Review* that has not been stated before? All of us know that the series contains articles on, to use those two clichés, 'cutting edge' information on the 'state-of-the-art' of medical research. It has, quite deservedly, among the highest impact factors among the periodicals, in all of the subjects that the series covers. This volume too, joins the others in the pathology series as an outstanding one. The topics are as diverse as before – some on the basic processes in the pathological cell, and some on specific diseases. There are 576 pages in this volume, compared to 386 in the previous volume and much of this is because of one chapter of 68 pages. The interview with a pioneer in the field is, however, not present in this issue and that is a pity, because I have found these interviews absolutely fascinating. The choice of subjects includes endoplasmic reticulum stress, driver and passenger mutations in cancer, inflammasomes and autoinflammatory diseases, molecular pathogenesis of renal carcinoma, pathobiology of transfusion reactions, diseases of pulmonary surfactant homeostasis, DNA repli-

cation stress and cancer, and also topics most pathologists would not even be aware of.

The best example of this in the book is the chapter on 'Engineered *in vitro* disease models'. As is obvious, procuring appropriate disease models is not easy. Mice are not men and despite the best of research being done on mice and other animal models, sometimes the results are simply not applicable to human beings. Cell lines have distinct uses for understanding certain mechanisms of a disease, but fall far short of replicating the real case – a human being. While getting human models for all diseases is impossible for practical and ethical reasons, Ingber and colleagues write a scintillating and detailed essay (yes, this is the 68-page article) on tissue engineering using organ-on-a-chip and 3D cultures, which is a step ahead in our attempt to develop disease models.

The range of diseases and organs that can be studied and are being investigated is vast – there are engineered heart valve models, cardiac tissues, chronic obstructive respiratory disease, inherited liver diseases, drug-induced nephrotoxicity, deep-vein thrombosis, schizophrenia, etc. I note with some interest that among the diseases studied are microcephaly: ordinarily, a disease that may not have been top of my list to read about, because it is uncommon – but which I notice now with great interest, because of the recent news reports that the just-discovered Zika virus is known to cause microcephaly.

How special this tool is, is clear from these astounding facts which sound like science fiction: the microfluidic kidney-on-a-chip device is composed of human kidney proximal convoluted tubule cells which mimic the conditions in the living proximal convoluted tubule. When exposed to physiological fluid flow, these cells show primary cilium formation, alkaline phosphatase activity, albumin transport, glucose reabsorption and Pgp transport function compared to cells in static Transwell culture. Similarly, Caco-2 cells, derived from an intestinal tumour, when exposed to cyclic mechanical distortion analogous to peristalsis, reorganize into 3D intestinal villi, including differentiating into the different cell types of the intestine.

Given the fact that rogue respiratory viruses have been in much of the news this century, beginning with the SARS

virus and disease in the early part of this century and the MERS virus in 2015, it is not surprising that this volume contains an article on the topic. It includes data on the diseases caused by Hantavirus, Nipah virus and MERS Coronavirus. Nipah virus is of two genotypes: genotype M, seen in strains from Malaysia and Cambodia, and type B comprising strains from India and Bangladesh. Nipah virus disease results in encephalitis and, to a lesser extent, respiratory disease, in part probably due to the strain of virus involved. Systemic vasculitis of the small blood vessels and capillaries in the central nervous system, lung, heart and kidney have been seen at autopsy. Similar findings have been noted in the animal models of Syrian hamsters, ferrets and African green monkeys.

Nipah virus disease is of special interest to us in India as there was an outbreak in Siliguri in 2001, which resulted in 66 cases with an almost 74% mortality. It speaks volumes for India's approach to health and disease outbreaks that one has to subsequently read the lines 'Histopathological information on deceased patients is available only for patients from the Malaysian outbreak in 1998-99' and 'A lack of pathology from human autopsies is a huge limitation for understanding pathogenesis of the diseases caused by the three viruses...'

Quite a different issue lies with Alzheimer's disease, which is defined by the presence of clinical dementia and

neurofibrillary tangles and senile/neuritic plaques in the brain (and hence, is almost always conclusively diagnosed only at autopsy). Autopsies have shown that many of the brains with Alzheimer's disease also exhibit coexistent Parkinson's disease, infections, cerebrovascular disease, etc. While much of what we know about the neuropathology of Alzheimer's disease is because of autopsies, these have their shortcomings and biases – the patient population is highly selected and may not be representative of a given population – and obviously examine tissue only at the end stage of a long drawn-out, chronic disease process. Biomarkers are now being investigated to determine their potential in the diagnosis of Alzheimer's disease. This includes neuroimaging (amyloid PET, FDG-PET and structural MRI) as well as blood tests to evaluate ApoE genotype and the ratio of $A\beta_{1-42}$ to $A\beta_{1-40}$. CSF levels of t-tau, p-tau and β -protein (usually $A\beta_{1-42}$) also offer a possible way to early diagnosis in the future.

Hepatitis C virus, which, on the other hand, has been known to us for just a little longer (it was cloned and identified in 1989 and was previously one of the non-A non-B viruses, to use the term that I was taught as an undergraduate medical student), is an RNA virus which has been implicated as a cause of hepatocellular carcinoma. Unlike hepatitis B virus, which integrates into the host genome, hepatitis C virus cannot; in fact, it does not even have any oncogenes. So how does it affect the hepatocyte and result in cancer? Lin *et al.* explain that the core protein, the E2 protein and NS5A proteins inhibit apoptosis and promote cellular proliferation and survival. This leads to genomic instability; and combined with reactive oxidative stress and fibrogenesis, it results in fibrosis and cirrhosis, and the combination leads to hepatocellular carcinoma. HCV can predispose to endoplasmic reticulum stress (clearly an important area of research, given the fact that the subject is a topic of another essay in this book) and this stress can predispose to mutagenesis secondary to intracellular and extracellular accumulation of DNA-damaging factors.

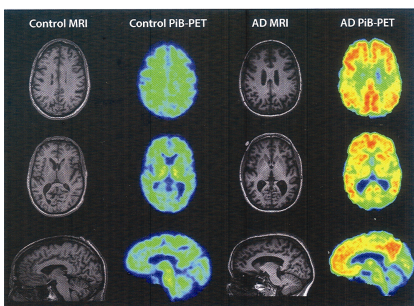
Amidst all the gems, are more gems. One learns, in the various essays, inter-

esting facts such as this: 'each human Beta cell in the islets of Langerhans produces on average about one million molecules of Insulin every minute'; *pate de fois gras* as well as beef contain AA amyloid (but it is not clear at the moment whether this is transmissible to man), and Gout, a disease which we associate with Victorian England and with the intake of port wine by the wealthy has been known to man for long, it has been documented in ancient Egypt as far back as the 27th century BC.

Finally, because the book deals with mechanisms of disease and not the morphology (which is hands-on, routine practical pathology), there is predictably, little on morphologic evaluation of disease – which is what I do in my daily practice of pathology. However, in most of the volumes that I have read, there have always been tidbits of information that I have found useful in my diagnostic work. This book is no different. In the chapter on severe asthma, we learn about a new entity (described first by the authors themselves), one that is termed 'asthmatic granulomatosis'. It appears that some cases of asthma are associated with the formation of non-necrotising granulomas in the bronchioles and in the interstitium. Granuloma formation has numerous causes – but tuberculosis is by far the most common and most important cause in India for granulomas in a lung biopsy. So much so, that many pathologists in India – regrettably – automatically assume that granulomas always indicate the diagnosis of tuberculosis, which results in patients being put on a useless therapeutic regimen, with many severe side effects. Because these asthmatic granulomatosis lesions have now been shown to occasionally even demonstrate caseation, a condition that is almost *sine qua non* for tuberculosis, it means that physicians and pathologists must be on guard before labelling all caseating lung granulomas as tubercular in origin.

SANJAY A. PAI

Department of Pathology,
Columbia Asia Referral Hospital,
Malleswaram,
Bengaluru 560 055, India
e-mail: sanjayapai@gmail.com



Structural (MRI) and amyloid PET imaging of axial slices of brain from a control subject (two columns at left) and an Alzheimer's disease (AD) subject (two columns at right). Note the prominent Pittsburgh compound B (PiB) signal in the AD brain (far right column). Images courtesy of William Jagust, University of California, Berkeley.