

modelling approach in identifying the major drivers of TCC change.

- <http://www.icimod.org/?q=1137>
- IPCC, The Fourth Assessment Report: Climate Change: Synthesis Report, Cambridge University Press, Cambridge, UK, 2007.
- Tiwari, P. C. and Joshi, B., *Water Resources Management*, 2012, **26**, 883–907.
- Ning, W., Rawat, G. S. and Sharma, E., ICIMOD, Kathmandu, Nepal, 2013; http://www.mountainpartnership.org/file-admin/user_upload/mountain_partnership/docs/3_HAR.pdf
- Food and Agriculture Organization of the United Nations, Global Forest Resources Assessment, FAO Forestry Paper 163, FAO, Rome, 2010.
- Hosonuma, N. *et al.*, *Environ. Res. Lett.*, 2012, **7**, 044009.
- Ali, J., Benjaminsen, T. A., Hammad, A. A. and Dick, Ø. B., *Global Environ. Change*, 2005, **15**, 370–380.
- Cui, X., Graf, H. F., Langmann, B., Chen, W. and Huang, R., *Earth Interact.*, 2007, **11**, 1–18.
- Iqbal, S. and Mastoraki, S. N., International Conference on Energy and Environment, Geneva, Switzerland, 2014.
- Behera, M. D., Murthy, M. S. R., Das, P., Uddin, K. and Sharma, E., In Proceedings of the ISRS National Symposium on Geomatics for Digital India, JK Lakshmipat University, Jaipur, 2015.
- Kulkarni, A., Patwardhan, S., Kumar, K. K., Ashok, K. and Krishnan, R., *Mt. Res. Develop.*, 2013, **33**, 142–151.
- Hansen, M. C., Potapov, P. V., Moore, R., Hancher, M., Turubanova, S. A., Tyukavina, A. and Townshend, J. R. G., *Science*, 2013, **342**, 850–853.
- Brown, S. and Shrestha, B., *J. Environ. Manage.*, 2000, **59**, 217–225.
- Burgess, P. J., Moffat, A. J. and Matthews, R. B., *Outlook Agricul.*, 2010, **39**, 263–268.

Received 6 August 2015; revised accepted 23 September 2016

MANCHIRAJU SRI RAMACHANDRA MURTHY¹
PULAKESH DAS²
MUKUNDA DEV BEHERA^{2,*}

¹International Centre for Integrated Mountain Development, GPO Box 3226, Kathmandu, Nepal

²Centre for Oceans, Rivers, Atmosphere and Land Sciences, Indian Institute of Technology, Kharagpur 721 302, India

*For correspondence.
e-mail: mbehera@coral.iitkgp.ernet.in

Histopathological changes in golden hamsters induced by *Leishmania tropica*

Several hundred million people are living in areas where they can be infected with leishmaniasis, a disease caused by over 20 species of pathogenic intracellular protozoan parasites of the genus *Leishmania* and transmitted through the bite of a female phlebotomine sandfly. *Leishmania* parasites infect phagocytes, dendritic cells and fibroblasts¹. The essential vertebrate host target cell is the macrophage, where the intracellular amastigotes of *Leishmania* reproduce, eventually rupture the cell and spread to other uninfected macrophages². Then these infected cells migrate to all host tissues. *Leishmania* parasites have a high chance for damaging some tissue functions. The clinical spectrum of leishmaniasis varies from an auto-resolving cutaneous lesion, to a distorting mucocutaneous disease, to a fatal visceral illness³. One of the important factors determining the pattern of pathology is the species of *Leishmania*⁴. However, the vectors, nutritional status, genetic background of the host and socioeconomic and environmental factors also have an important impact on the outcome of the disease^{3,4}. Patients, infected by the same species of *Leishmania*, may give rise to various symptoms⁵ and may respond differently to treatment^{6,7}. Lately, the

BALB/c strain of mice has attracted much attention because it produces visceral leishmaniasis which may be used as a model for studying human visceral leishmaniasis⁸. We address some histopathological features of viscerizing of *L. tropica* in golden hamsters as a model to study human visceral leishmaniasis.

Leishmania tropica was isolated in Baghdad teaching hospital, Baghdad, Iraq from a skin lesion on the left arm of a 21-year-old male⁹. Males of golden hamster ($n = 60$), aged 8–10 weeks, were

supplied by the National Center for Drug Control and Researches (NCDCR), Baghdad. The golden hamsters were divided into two groups, each consisting of 30 hamsters which were inoculated as follows: one was inoculated with 5×10^7 promastigotes of virulent isolate of *L. tropica* which was already cultivated in biphasic medium¹⁰. The other was the control group with hamsters inoculated with 0.2 ml of phosphate buffer saline.

All hamsters were injected intradermally in the left rear footpad using 1 ml

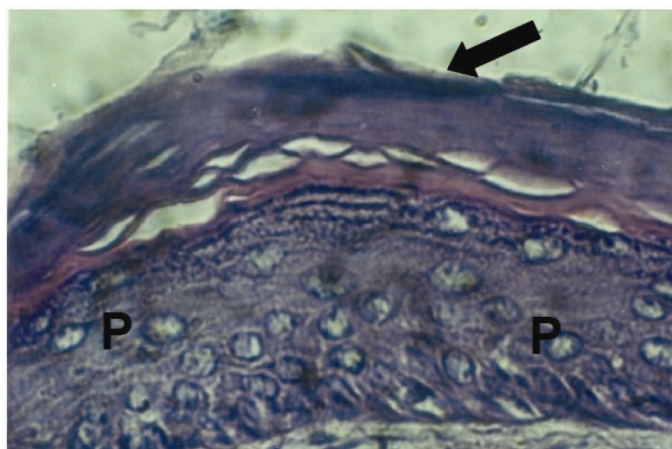


Figure 1. Section in footpad of infected group, showing hyperkeratosis (black arrow) and hyperplasia (P), 60 days post-infection, hematoxylin and eosine stain (400X).

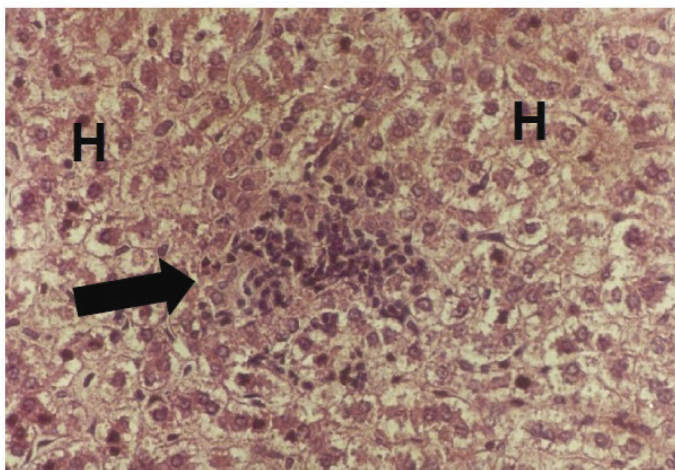


Figure 2. Section in liver of infected group, showing inflammatory infiltration (black arrow) and hypertrophy of kupffer cells (H), 60 days post-infection, hematoxylin and eosine stain (400X).

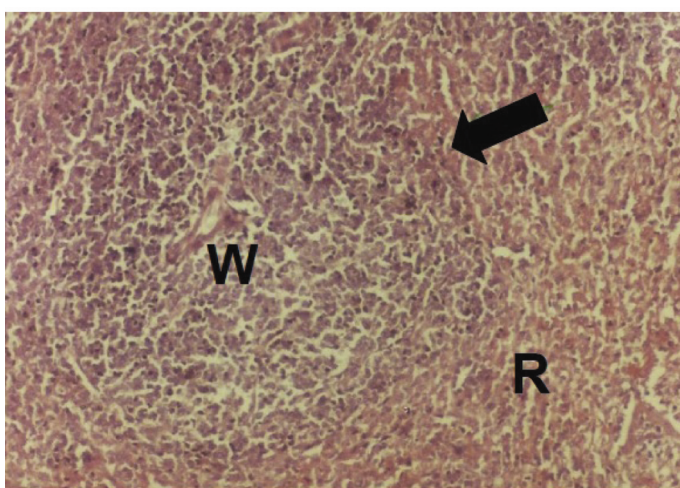


Figure 3. Section in spleen of infected group, showing white pulp dilation (W) over red pulp (R), margin of white pulp (black arrow), 60 days post-infection, hematoxylin and eosine stain (400X).

sterilized syringe for each animal. They were examined for the appearance of skin ulcer/ulcers and then each animal was dissected to study the progress of the infection of *L. tropica* in viscera at 30, 45, 60, 75 and 90 days post-infection. Biopsies taken from the injected footpad, liver and spleen, were fixed in 10% formalin in phosphate buffer saline (PBS), washed in distilled water for 4 h and dehydrated, then embedded in paraffin, cut to small pieces (3–4 μm thick) and stained with hematoxylin and eosin^{11,12}. Finally we examined them for histopathological changes using optical microscope.

Results showed that the skin ulcers appeared after two weeks post-infection with *L. tropica*. The footpad ulcers were

reddish and congested in the golden hamsters inoculated with *L. tropica* and there were histological changes in their footpad, spleen and liver that varied from low, moderate and heavy changes at the beginning. After following up at the middle and the end interval, the skin showed different levels of hyperkeratosis, hyperplasia and edema (Figure 1). On the other hand, inflammatory infiltration, kupffer cells hyperplasia and hydropic degeneration were noticed in the liver of the hamsters inoculated with *L. tropica* (Figure 2). Spleen also showed some histopathological changes from 30 days post-infection until the end of the follow-up duration. The changes manifested as infiltration of macrophages and lymphocytes, white pulp expansion,

follicular hyperplasia, fibrosis and blood congestion (Figure 3). These findings suggest that moderate and heavy visceral infections could be generated by *L. tropica* in golden hamsters, which may avail as an appropriate model to study human visceral leishmaniasis.

1. Kobets, T., Grekov, I. and Lipoldová, M., *Curr. Med. Chem.*, 2012, **19**, 1443–1474.
2. Awasthi, A., Kumar, M. R. and Saha, B., *Indian J. Med. Res.*, 2004, **119**, 238–258.
3. McGwire, B. S., Chang, K. P. and Engman, D. M., *Infect. Immun.*, 2003, **71**, 1008–1010.
4. Lemos De Souza, V., Ascensão Souza, J., Correia Silva, T. M., Sampaio Tavares Veras, P. and Rodrigues De-Freitas, L. A., *Microbes Infect.*, 2000, **2**, 1807–1815.
5. McMahon-Pratt, D. and Alexander, J., *Immunol. Rev.*, 2004, **201**, 206–224.
6. Herwaldt, B. L., *Lancet*, 1999, **354**, 1191–1199.
7. Kobets, T. *et al.*, *PLoS Neglected Trop. Dis.*, 2012, **6**, e1667.
8. Honoré, S., Garin, Y. J. F., Sulahian, A., Gangneux, J. P. and Derouin, F., *FEMS Immunol. Med. Microbiol.*, 1998, **21**, 231–239.
9. Luz, Z. M. P., da Silva A. R., Silva, F. O., Caligorne, R. B., Oliveira, E. and Rabello, A., *Mem. Inst. Oswaldo. Cruz.*, 2009, **104**, 62–66.
10. Al-Warid, H. S. and Al-Shanawi, F. A., *Int. J. Adv. Res.*, 2014, **2**, 875–879.
11. Al-Warid, H. S., Al-Shanawi, F. A. and Mohammed, G. S., *Al-Mustansiriyah J. Sci.*, 2011, **22**, 287–298.
12. Mora, A. M., Mayrink, W., Da Costa, R. T., Da Costa, C. A., Genaro, O. and Nascimento, E., *Rev. Inst. Med. Trop. Sao. Paulo.*, 1999, **41**, 243–248.

Received 30 March 2016; revised accepted 3 June 2016

HARITH SAEED AL-WARID^{1,2,*}
FAWZIA AHMED AL SHANAWI²

¹School of Natural Resources,
University of Missouri,
302 Anheuser-Busch Natural Resources
Building,
Columbia, Missouri, 65211, USA
²Biology Department,
College of Science,
University of Baghdad,
Al-Jadriyah Campus,
Baghdad, Iraq

*For correspondence.
e-mail: harithalward@scbaghdad.edu.iq