

ORIGINAL PAPER

A Clinical Study of Arthroscopic Management of Meniscal Injuries of Knee Joint

Paul Gautam Chandra¹, Biswas Samrat², Das SK³, Sipani AK⁴

Received on September 10, 2015; editorial approval on October 01, 2015

ABSTRACT

Background: *This prospective clinical study attempts to evaluate the role of arthroscopic surgery in meniscal injury of knee joint. Low morbidity and early rehabilitation associated with arthroscopic surgery of meniscal injuries makes it a highly acceptable procedure.*

Materials and Methods: *This study includes 30 cases of meniscal injuries of knee treated by arthroscopic techniques at Silchar Medical College and Hospital, Silchar between January 2011 to December 2012. Minimum follow up has been done upto 6 months.*

Results: *The mean age of the patients was 26.36 years. Twenty eight (93%) patients were male and 2 (7%) patients were female. Most sustained meniscal injury following sports related injuries (60%). Arthroscopic partial meniscectomy was done in 28 patients and arthroscopic meniscal repairs done in 2 patients. Mean operative time for meniscectomy was 75 minutes. Functional outcome was assessed based on Lysholm Knee Score and Tapper and Hoover Grading System in follow up period. Excellent to good results were found in 80% cases.*

Conclusion: *Arthroscopic partial meniscectomy and repair are minimal invasive technique, advantage of which includes early return to work, minimal complications, early post operative rehabilitation, short duration of hospital stay. Hence these are the preferred technique for treatment of meniscal injuries. Though arthroscopic partial meniscectomy is a preferred method of treatment but in repairable meniscal injuries meniscus preserving surgery should be tried.*

Keywords: *Meniscal tear, arthroscopic partial meniscectomy, arthroscopic meniscal repair*

INTRODUCTION

Menisci are essential for the normal function of the knee joint. The menisci act as a joint filler, compensating for gross incongruity between femoral and tibial articular surfaces. The menisci prevent capsular and synovial impingement during flexion-extension movements. It is believed to have joint lubrication properties.¹

The menisci have been shown to play a vital role in load transmission across the knee joint.² The menisci have shock or energy-absorbing functions.³ Meniscus injuries are produced most commonly by rotation as the flexed knee moves toward an extended position.⁴ Meniscal injuries of the knee joint are common in sportsperson and athletes.⁵ In other individuals, meniscal injuries can also occur as a result of road traffic accident and mine workers involving rotational injuries of knee joint. Meniscal tears are the most common injury of the knee, with an incidence of meniscal injury resulting in meniscectomy of 61 per 100 000 population per year.⁶ Typical signs and symptoms are clicking, catching or snapping. A knee effusion may or may not be present, but most patients will have joint line tenderness.

Address for the correspondence and reprint:

¹Registrar (**corresponding author**)

Dept. of Orthopaedics, Tezpur Medical College

Email: docgcpaul@gmail.com

Mobile: 9678925251

²Assistant Professor, Dept. of Microbiology, Tezpur Medical College

³Professor & Head, Dept. of Orthopaedics, Tezpur Medical College

⁴Professor & Head, Dept. of Orthopaedics, Silchar Medical College

Arthroscopic procedure of knee joint also improves accuracy of the diagnosis of meniscal injuries, reduces hospital stay, minimizes complications and improves the quality of life. Simpson DA et al.⁷ reviewed comparative analysis of open and close meniscectomy results and confirmed the overall economical and therapeutic advantage of arthroscopic partial meniscectomy over open meniscectomy.

AIMS AND OBJECTIVES

The present study is designed to evaluate the effectiveness of arthroscopy to confirm the types of meniscal injuries in clinically suspected cases and to assess the outcome of arthroscopic partial meniscectomy and meniscal repair in a tertiary centre like ours.

MATERIALS AND METHODS

This study includes 30 cases of meniscal injuries of knee treated by arthroscopic techniques at Silchar Medical College and Hospital, Silchar between January 2011 to December 2012. Minimum follow up has been done up to 6 months.

Patients aged between 18-50 years with clinically suspected meniscal injuries and suggestive MRI findings of meniscal lesion are included in the study. Patients with infective condition in and around the knee joint, meniscal injuries with tibial plateau fractures and/or distal femoral fracture and patients with medical contraindications are excluded from the study.

Patients with both clinically suspected and MRI diagnosed meniscal injury were admitted. Then patients were thoroughly examined clinically and routine investigation were done and documented.

All patients were operated under spinal anaesthesia and tourniquet was used. Arthroscopic partial meniscectomy was done in 28 patients and arthroscopic meniscal repair was done in 2 patients. Most common combination used was anterolateral portal for arthroscope and anteromedial portal for the instrumentation. Arthroscopic meniscal repair was done by Outside-in technique.⁸ In this technique two 18 gauge spinal needles were passed from outside the joint to inside the joint under arthroscopic vision. After reduction of meniscal fragments, they were tied with non-absorbable suture materials through the spinal needles.

Postoperatively Jones type padded bandage was applied and physiotherapy was started from day 1. Patients were allowed to bear full weight on second postoperative day onwards in arthroscopic partial meniscectomy group.

Weight bearing was avoided for at least 6 weeks in meniscal repair group. Out of 30 patients, 9 were associated with partial/complete ACL tear, 4 associated with articular cartilage degeneration and 2 associated with loose body.

RESULTS

28 (93%) patients were male and 2 (7%) patients were female. Age ranges from 18-46 years with a mean age of 26-36 years. Meniscal injuries in left knee were found in 17 (57%) cases and right knee in 13 (43%) cases. Mode of injuries was sports related injuries in 18 (60%) cases, road traffic accident 7 (23%) cases and history of fall in 5 (17%) cases. Twenty (67%) cases were medial meniscus tear and 10 (33%) cases were lateral tear. The most type of tear was Longitudinal tear (Bucket handle) (53%). Arthroscopic partial meniscectomy was done in 28 patients and arthroscopic meniscal repair was done in 2 patients. There were 9 cases of partial/complete ACL tears of which 7 cases were reconstructed with SMT graft. Two cases associated with loose bodies which were removed arthroscopically. Four cases associated with articular cartilage degeneration of which in one case arthroscopic microfracture performed. Complication such as haemarthrosis observed in two cases. Duration of hospital stay was average 2-7 days with a range of 2-4 days. Mean time for return to work was 14-8 days with range from 10-22 days. Patients were followed up in the out patient department on 2nd week and 4th week, after that every month for 6 months. Functional outcome was assessed based on Lysholm.

Knee Score and Tapper and Hoover Grading System⁹ in follow up period. Excellent to good results was found in 80% cases.

Case 1: Intraoperative Findings and Arthroscopic Techniques Of Meniscus Repair

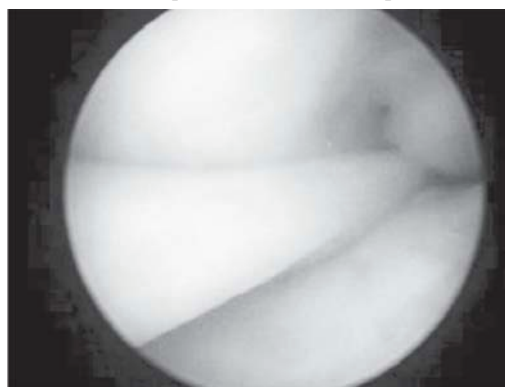


Figure 1 Bucket handle (BH) tear

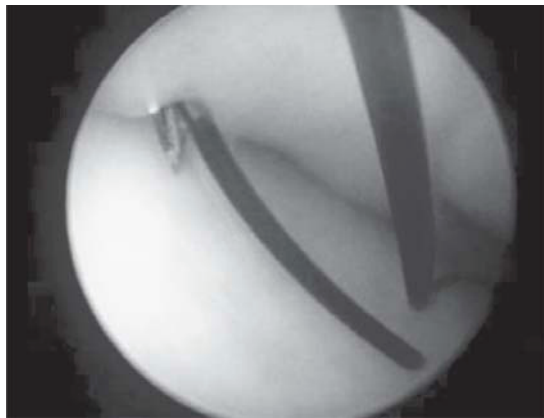


Figure 2 Suture insertion

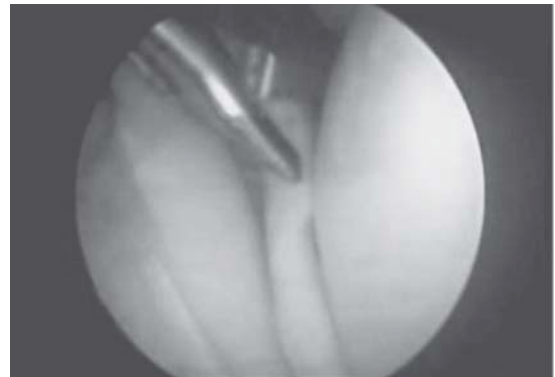

Figure 5 Biting with Basket Forcep

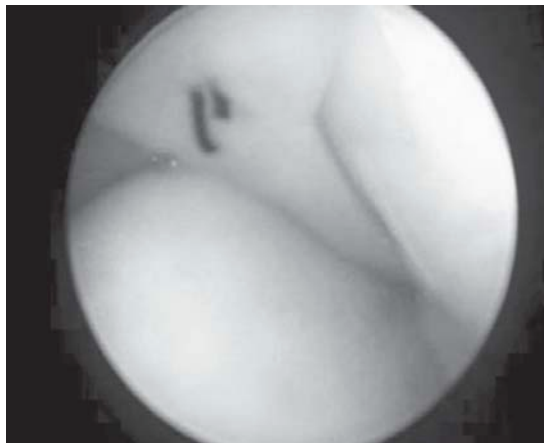

Figure 3 After Repair

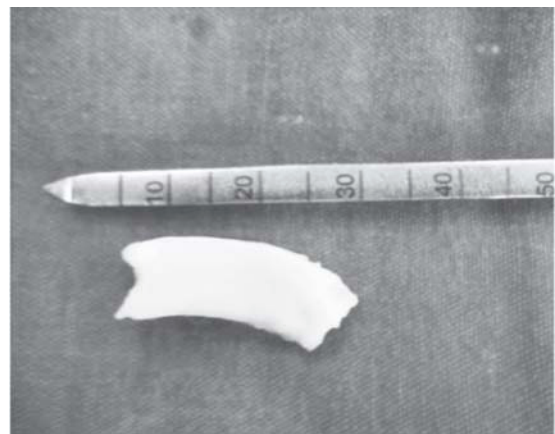

Figure 6 Resected Meniscal Fragment

**Case 2: Intraoperative Findings & Arthroscopic Techniques
Of Partial Meniscectomy**

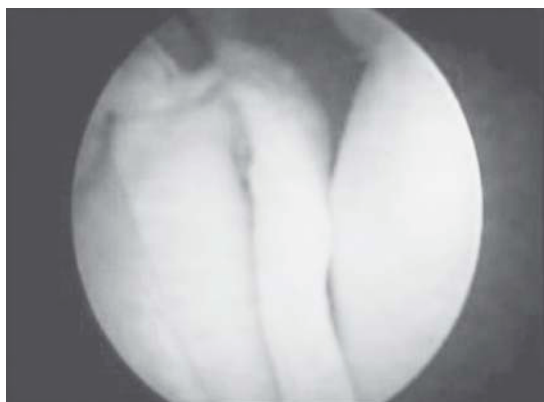

Figure 4 BHMM Tear

DISCUSSION

Treatment of meniscal injuries has evolved from conservative management, open meniscectomy and meniscal repair to closed arthroscopic partial meniscectomy and meniscal repair. Simpson DA et al⁷ reviewed the overall economical and therapeutic advantage of arthroscopic partial meniscectomy over open meniscectomy. Other authors have reported short hospital stay and early return to work and sports like Northmore-Ball et al¹⁰; Lysholm, Gillquist et al¹¹; GoodFellow JW et al¹²; Dandy DJ et al.¹³ Biedert RM et al¹⁴ reviewed short-term results were best by performing partial meniscectomy. However, other studies of meniscus preserving surgeries have reported even better medium to long term results like Paxton ES, Stock MV et al¹⁵; Dave LY, Caborn DN et al.¹⁶

In our study 28 (93%) patients were males, with mean age of all 30 patients was 26.36 yrs and 57% involvement was left side. In series of Simpson DA et al⁷ the mean age of

the 230 patients was 30.7 years. Men and boys formed 90% of the series.

In our series 60% of cases were sports related injuries, 23% road traffic accidents and 17% history of fall. In Rao PS, Rao SK et al⁵ reviewed sports related injuries was the most common mechanisms of injury.

Out of 30 cases incidence of medial meniscus tear was 67% and lateral meniscus tear was 33% and longitudinal (bucket handle) tear was the most common type of meniscal tear. In series of Dandy DJ et al¹⁷ medial meniscus tear was 70.5% and lateral meniscus tear was 29.5% and vertical (longitudinal) tear was common than the other type of meniscal tear.

Mean operative time in our series was 75 minutes as compared to 45 minute by Tregonning RJ et al.¹⁸ Mean duration of hospital stay in our study was 2.7 days (range 2-4 days) compared to 2.4 days (range 1 to 7 days) as reported by Simpson DA et al.⁷

Functional outcome results in our series excellent 57%, good 23%, fair 20% and poor 0% as compared to results in series of Rao PS, Rao SK et al⁵ was excellent and good 81.25% and fair and poor 18.75%. Functional results in series of Simpson DA et al⁶ was excellent to good in 80.55% of cases.

Majority of our patients returned to their premeniscal injury activity in 14.8 days where as in series of Tregonning RJ et al¹⁸ mean time for return to work was 12.9 days and in series of Dandy DJ et al¹³ was 10.5 days.

In our study we found correlation between clinical and radiological features with the arthroscopic findings. Thus arthroscopic partial meniscectomy and meniscal repair have many advantages in the treatment of meniscal injuries. Arthroscopic surgery reduces hospital stay, gives early relief of symptoms, low morbidity and patients return to their work early and minimal complications. Though our study was a short term outcome study but it confirmed the advantage of arthroscopic surgery in meniscal injuries. However, long term study is required for conclusive remark.

CONCLUSION

Incidence of meniscal injuries is most common in third decade in male persons due to sports related injuries and second commonest cause is road traffic accident. Arthroscopic partial meniscectomy and repair are minimally invasive technique. Advantage of which includes early return to work, minimal complications, early post operative

rehabilitation, short duration of hospital stay. Hence these are the preferred technique for treatment of meniscal injuries. Results were better in age group less than 40 years and in patients with early presentation. Though arthroscopic partial meniscectomy is a preferred method of treatment but in repairable meniscal injuries meniscus preserving surgery should be tried. But it is a technically difficult procedure with steep learning curve. From our present study we conclude that arthroscopic surgery may be a preferred treatment option for management of meniscal injuries.

Contribution of Authors

We declare that author(s) named in this article did this work and all liabilities pertaining to claim relating to the content of this article will be borne by the authors. The study was conceived and designed by Dr. Gautam Chandra Paul, who also collected and analyzed the data. Dr. Samrat Biswas, Dr. SK Das and Dr. AK Sipani contributed to analyze the data and designing the manuscript.

Acknowledgement

We are highly indebted to Dr Kanchan Bhattacharjee, Consultant Arthroscopic Surgeon, Kolkata for his constant help and guidance during the study.

REFERENCES

1. Textbook "Campbell's Operative Orthopaedics", eleventh edition, chapter 43, Knee Injuries by Robert H. Miller III and Frederick M. Azar, p. 2417-2436.
2. Seedholm Bb, Dowson D, Wright V. Functions of the menisci: a preliminary study. *J Bone Joint Surg [Br]* 1974;56-B:381-2.
3. Voloshin As, Wosk J. Shock absorption of meniscectomized and painful knees: a comparative in vivo study. *J Biomed Eng* 1983;5:157-61.
4. Renstrom P, Johnson RJ. Anatomy and biomechanics of the menisci. *Clin Sports Med* 1990;9:523-38.
5. Rao PS, Rao SK, Bhat SN. Short and long term results of arthroscopic partial meniscectomy. *Indian Journal of orthopedics* 2004;38(3):158-161.
6. Baker PE, Peckham AC, Puppato F, Sanborn JC. Review of meniscal injury and associated sports. *Am J Sports Med* 1985;13:1-4.
7. Simpson DA, Thomas NP, Aichroth PM. Open and closed meniscectomy. A comparative analysis. *J Bone and Joint Surgery Br* 1986 Mar;68(2):301-304.
8. Textbook "Manual Of Arthroscopic Surgery", Chapter 2: Knee Joint – Special Part, by Michael J. Strobel, p. 97-199.

9. Rao SK, Rao PS. Lysholm Scoring system to evaluate Meniscal injury. Indian Journal of Orthopaedics 1997;31(2):107-109.
10. Northmore- Ball, Dandy DJ, Jackson RW. Arthroscopic, open partial, and total meniscectomy-A comparative study. J Bone and Joint Surgery 1983 Aug;65(4):400-404.
11. Lysholm J, Gillquist J. Endoscopic meniscectomy J Int Orthop 1981;5(4):265-270.
12. Goodfellow JW. Closed meniscectomy. J Bone Joint Surg (Br) 1983 Aug;65(4):373-374.
13. Dandy DJ. Early results of closed partial meniscectomy. J Br Med 1978 Apr 29;1(6120):1099-1100.
14. Biedert RM. Treatment of intrasubstance meniscal lesions: a randomized prospective study of four different methods. J Knee Surg Sports Traumatol Arthrosc 2000;8(2):104-108.
15. Paxton ES, Stock MV, Brophy RH. Meniscal repair versus partial meniscectomy: a systematic review comparing reoperation rates and clinical outcomes. J Arthroscopy 2011 Sep;27(9):1275-88.
16. Dave LY, Caborn DN. Outside-in meniscus repair: the last 25 years. J Sports Med Arthrosc 2012 Jun;20(2):77-85.
17. Dandy DJ. The arthroscopic anatomy of symptomatic Meniscal lesions. J Bone and Joint Surgery 1990 July;72(4):628-633.
18. Tregonning RJ. Closed partial meniscectomy early results for simple tears with mechanical symptoms. J Bone and Joint Surgery 1983 Aug;65(4):378-382.

SUBMISSION OF MANUSCRIPT

1. All manuscripts must be in English and should be submitted through online (**Author Login**)
2. The full name as well as the e-mail addresses and telephone numbers of all authors must be provided
3. A copy of the manuscript in MS Word format may also be submitted via email (**editor@ijhrmlp.org**)
4. Illustrations (figures) should be in computer format. Images for any manuscript should not exceed 200 kilobytes and should also be sent as an attachment of mail (jpg format). Maximum figure five.
5. Authors may submit the names, affiliations and addresses (including email) of expert reviewers or those they do not want to review their papers.
6. **Paper size:** A4 with 1.25 cm margin on all sides
7. **Paragraphing:** All text must be in **single line** space all through. Also use single line spaces to indicate paragraphs. Nothing else.
8. **Font:** "Times" all through the text of article. **Title:** 22 points font size.
9. **Author's Names:** 12 points font size and must be in the following order: full surname, first name and lastly middle name. *Author's affiliation* and correspondence telephone and email: 9 points font size.
10. **Tables and Figures:** 9 points font size all through. Data in Tables **MUST** be provided in the cells inside Table. The use of TABS, spacing between lines using line should be avoided. Authors should produce figures that will not exceed the size of half column of a page.
11. **Body of manuscript:** Use 11 points (bold) for major headers and 10 points (bold) for all sub-headings and other texts.
12. **Material and Methods:** Use 11 points for header and 10 points for all sub-headings and other texts.
13. **Authors Contribution:** Use 10 points (bold) for header and 10 points for other texts
14. **Acknowledgements:** Use 10 points (bold) for header and 10 points for other texts