

ORIGINAL PAPER

Third Coronary Artery – An Autopsy Study

Yadukul S¹, Sumangala CN², Chandragirish C³, Chandrashekar TN⁴

Received on March 28/2015; accepted (revised) on April 11/2015; approved by author on May 11/2015

ABSTRACT

Anatomy and functionality of the coronary circulation have been of interest to physicians ever since it emerged that mammalian hearts have their own blood supply. If asked how many coronary arteries the normal heart has, most of the medical students (and many practitioners) would answer “TWO”. However, the frequent presence of two right coronary artery roots is not generally well appreciated, even though it has been evident to anatomists and cardiac surgeons for centuries.

In this present study, we dissected 550 hearts for a period of 6 months from January 1st 2011 to 30th June 2011 in Victoria Hospital, Department of Forensic Medicine, Bangalore Medical College and Research Institute, Bengaluru. The incidence, position, course of the third coronary and other forensic importance of the third coronary artery will be discussed in the present study.

Keywords: *Coronary Circulation, Third Coronary Artery, Autopsy.*

Address for correspondences and reprint:

¹Assistant Professor (**Corresponding Author**), Department of Forensic Medicine and Toxicology, Chamarajanagar Institute of Medical Sciences, Chamarajanagar.

Mobile: +91 9986510681

Email: dr.kooool@gmail.com

²Assistant Professor, Department of Forensic Medicine and Toxicology, Bangalore Medical College and Research Institute, Bengaluru. ³Assistant Professor, Department of Anatomy, Chamarajanagar Institute of Medical Sciences, Chamarajanagar. ⁴Dean and Director, Chamarajanagar Institute of Medical Sciences, Chamarajanagar.

INTRODUCTION

The human heart is in most cases vascularized by two coronary arteries, the right and the left coronary artery. Supernumerary or added coronary arteries are also present sometimes. Supernumerary coronary artery, which arises independently from the right aortic sinus (sinus Valsvae) and passes through sub-epicardial adipose tissue of pulmonary conus and anterior side of the right ventricle, is called third coronary artery. The third coronary artery (TCA) is a direct branch from the right aortic sinus (RAS) without any observable common trunk with the right coronary artery (RCA). It supplies the infundibulum (conu) of the Right Ventricle (RV), which is usually vascularized by the conal branches of both the RCA and the left anterior descending (LAD).^{1,2} The reported prevalence of the TCA suggests ethnic variability.¹⁻⁴ Although its distribution is relatively unexplored, this artery may supply variable parts of the anterior wall of the RV and the Interventricular septum.⁵⁻⁷ This study was undertaken with the purpose of estimating the incidence, position, and course of the third coronary and other forensic importance of the third coronary artery.

MATERIAL AND METHODS

This study was conducted at Victoria Hospital, Department of Forensic Medicine and Toxicology, Bangalore Medical College and Research Institute, Bengaluru for a period of 6 months from January 1st 2011 to 30th June 2011. A total number of 1779 cases were performed during the study period, out of which 550 cases were selected for our study. Specimens with observable cardiac defects and decomposed cases were excluded from the study. The hearts were dissected to display the origins of the right, left and third coronary arteries. The aortic root was split

posteriorly to enable a clear view of the RAS with its orifices. With the aid of dissecting lenses, the branches of the TCA were displayed and traced distally to confirm the course, branching and termination.

OBSERVATION AND RESULTS

In this present study, we dissected 550 hearts (out of 1779 cases) for a period of 6 months from 1st January 2011 to 30th June 2011 in Victoria hospital, Department of Forensic Medicine, Bangalore Medical College and Research Institute, Bengaluru. The varieties of cases that have been selected for this study are shown in **Figure 1**.

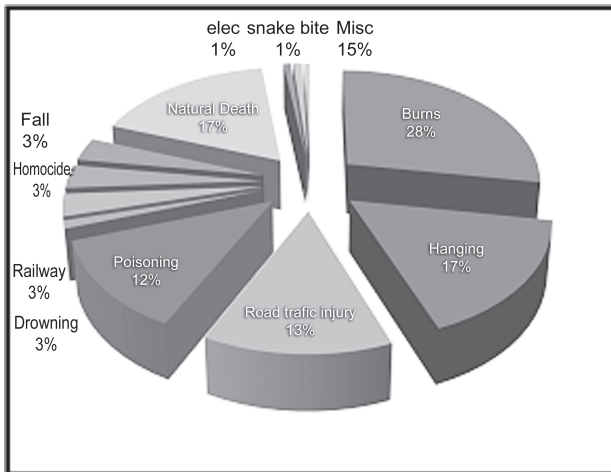


Figure 1 Variety of cases included



Figure 2 Presence of third coronary artery

Amongst 550 cases, 53% (n=293) were males. Out of the 550 hearts dissected, third coronary artery/conal artery was present in 184 hearts, which amounts to 33.45% (Fig

2). Incidence in males was 109 out of 293 (37.2%) and in females, it was 75 out of 257 (29.18%). According to the position (**Figure 3**) of the third coronary artery, 83.15% was in 10'clock position (n=153), 13.04% was in 9'clock position (n=24), 2.71% was in 8'clock position (n=5), 1.08% was in 7'clock position (n=2). Majority of the third coronary artery, i.e., 145 (78.8%) had an independent course without obvious anastomosis. Rest of the cases, 39 (21.2%) had a short course and had anastomosis with right coronary artery. Multiple orifices have been seen in 3 individuals (**Figure 4**). It was observed that among the 95 natural death cases, 32 cases were due to sudden natural death of cardiac origin. In these 32 cases, third coronary was present only in 3 cases.

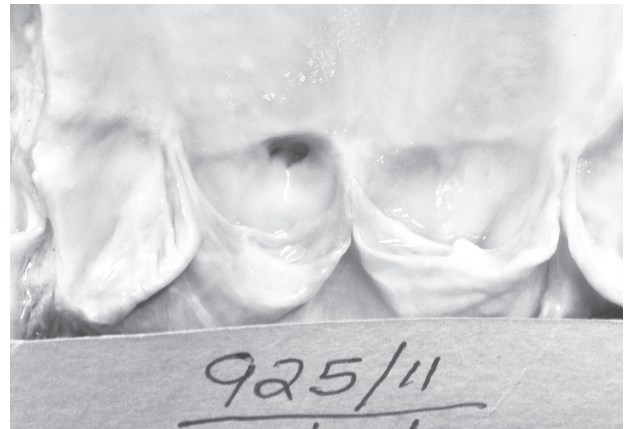


Figure 3 Third coronary in 10' clock position

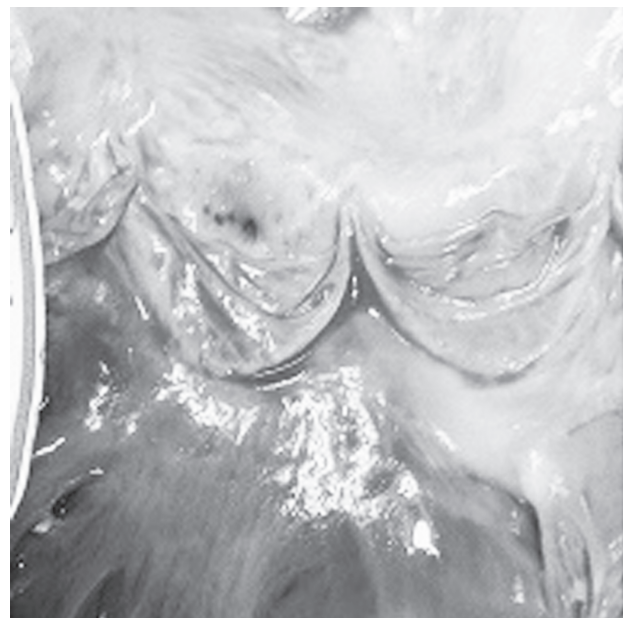


Figure 4 Presence of Multiple orifices

DISCUSSION

Many authors have studied the blood vessels, their variations and abnormalities. Various studies have been done in the past regarding the prevalence of third coronary artery, but very few have been done in our country. Supernumerary coronary artery arises mostly from the right aortic sinus. According to Almira et al., out of 25 hearts, examined by dissection, 8 of them (32%) had conal artery and 1 heart (4%) had four coronary arteries.⁸ In a Kenyan study by Olabu et al., it is observed that out of 148 cadaveric hearts, third coronary artery was seen in 35.1%.⁹ Study by Gouda Hareesh et al., discussed the importance of geographical differences and in establishment of partial identity if ante-mortem record is maintained.¹⁰ Studies from other countries regarding the incidence of the third coronary artery are mentioned in **Table 1**.^{3, 4, 7, 11-13} In our study, the incidence is 33.45%, which is higher (~9%) than the values given by Kalpana.¹³ It is remarkable that although the incidence of third coronary artery in our study is close to most of the other studies, much lower values have also been reported. These findings suggest ethnic variability and appear to support the proposal by Garg et al¹⁴ that there are geographical differences in coronary artery variations, which may have a genetic basis. Two orifices within the RAS had also been reported in the same setting.¹⁵ The separate orifices for the TCA and the RCA had been explained by insufficient unification of these two vessels, during their growth towards the ascending aorta.^{16, 17} Had•iselimovia¹⁸ points out that even three coronary arteries may arise independently from the right aortic sinus what was confirmed by this study too. Literature uses different terms for identifying this artery: conal artery, preinfundibular or supernumerary right coronary artery.¹⁸⁻²⁰ Literature describes cases with anastomosis of the coronary artery with the front interventricular branch, diagonal, circumflex one, as well as with the branches of the right coronary artery.²¹⁻²⁴

Table 1 Incidence of third coronary artery

Author	Population	Incidence
Miyazaki et al ³	Japanese	36.8%
Ivan et al ⁴	Bulgarians	34.8%
Von Ludinghausen et al ⁷	Germans	7.1%
Kurjia et al ¹¹	Iraqi	8%
Kalpana ¹²	Indians	24%
Turner et al ¹³	English	15.8%

CONCLUSION

The most suitable term to identify supernumerary heart artery that arises independently from the right aortic sinus is the third coronary artery. The present study highlights that the incidence of third coronary artery is 33.45%. It was observed that among the 95 natural death cases, 32 cases were due to sudden natural death of cardiac origin. In these 32 cases, third coronary artery was present only in 3 cases. Further studies, which include presence of third coronary artery among cardiac and non-cardiac individuals, should be done to access the importance of third coronary artery. Since this study is autopsy based, more research on third coronary artery is the need of the hour even in living individuals.

Acknowledgements: We sincerely acknowledge Dr. Devadass. PK, Dean and Director of Bangalore Medical College and Research Institute and all the Faculty members of Department of Forensic Medicine and Toxicology, Bangalore Medical College and Research Institute, Bengaluru. We also thank Dr. Prabhavathi, Professor of Cardiology, Shri Jayadeva Institute of Cardiovascular Sciences, and Bengaluru for her insight regarding the knowledge of third coronary artery.

Conflict of interest: None.

Contribution of Authors: We declare that the authors named in this article did this work and all liabilities pertaining to claims relating to the content of this article will be borne by the authors. Dr. Yadukul. S is the principle researcher who designed, collected and analyzed the data. Dr. Sumangala played a key role in collecting the data and analyzing it. Dr. Chandragirish and Dr. Chandrashekar. TN, were very helpful in providing the anatomical and clinical aspects to further analyze the data collected.

Ethical clearance: Taken.

REFERENCE

- Schlesinger MJ, Olla PM, Essler W. The conus artery: Third coronary artery. *Am Heart J* 1949; 38:823-36.
- Williams PL, Warwick R, Dyson M, Bannister H. *Gray's Anatomy*. 38th ed. London: Churchill Livingstone; 1995. p. 1451-626.
- Miyazaki M, Kato M. Third coronary artery: Its

- development and function. *Acta Cardiol* 1988; 43(4):449-57.
4. Ivan S, Milica J. Morphometric characteristics of the conal coronary artery. *M J M* 2004;8:2-6.
 5. Sahni D, Jit I. Blood supply of the human interventricular septum in Northwest Indians. *Indian Heart J* 1990;45(5):334.
 6. Ben-Gal T, Sclarovsky S, Herz I, Strasberg B, Zlotikamien B, Sulkes J. Importance of the conal branch of the right coronary artery in patients with acute myocardial infarction; electrocardiographic and angiographic correlation. *J Am Coll Cardiology* 1997;29(3):506-11.
 7. Von Ludinghausen M, Ohmachi N. Right superior septal artery with “normal” right coronary and ectopic “early” aortic origin: a contribution to the vascular supply of the interventricular septum of the human heart. *Clin Anat* 2001;14(5):312-9.
 8. Almira L, Fehim O, Ademir T. Third coronary artery; *Bosnian J of basic Med Sci* 2008;8(3):226-9.
 9. Olabu BO, Saidi HS, Hassanali J, Ogeng’o, JA. Prevalence and distribution of the third coronary artery in kenyans. *Int J Morphol* 2007;25(4):851-4.
 10. Gouda HS, Mestri SC, Aramani SC. Third coronary artery- boon or bane; *J of Ind Acad of For Med* 2009;31(1):62-4.
 11. Kurjia HZ, Cheudhry MS, Olson TR. Coronary artery variation in native Iraqui Population. *Cathet Cardiovasc Design* 1986;12(60):386-90.
 12. Kalpana RA. Study on principal branches of coronary artery in humans. *J Anat Soc India* 2003;52(2):137-40.
 13. Turner K, Navaratnam V. The positions of coronary arterial ostia. *Clin Anat* 1996;9(6):376-80.
 14. Garg N, Tewari S, Kapoor A, Gupta DK, Sinha N. Primary congenital anomalies of the coronary arteries: A coronary Arteriographic study. *Int J Cardiol* 2000;74(1):39-46.
 15. Saidi HS, Olumbe OK, Kalebi A. Anatomy and pathology of coronary artery in adult black kenyan. *East Afr Med J* 2002;79(6):323-7.
 16. Reese DE, Mikawa T, Bader DM. Development of the coronary vessel system. *Circ Res* 2002;91(9):761-8.
 17. Wada AM, Willet SG, Bader D. Coronary vessel development: a unique form of vasculogenesis. *Arterioscler Thromb Vasc Biol* 2003;23(12):2138-45.
 18. Had•iselimoviæ H., Dilberoviæ F., Ovèina F. Blood vessels of the human heart: coronarography and dissection. *Acta Anat (Basel)* 1980;106(4):443-9.
 19. Tanigawa J., Petrou M., Di Mario C. Selective injection of the conus branch should always be attempted if no collateral fi lling visualizes a chronically occluded left anterior descending coronary artery. *Int J Cardiol* 2007;115(1):126-7.
 20. Gupta SK, Abraham AK, Reddy NK, Moorthy SJ. Supernumerary right coronary artery. *J Clin Cardiol* 1987;10(7):425-27.
 21. Sharma S, Kaul U, Rajani M. Collateral circulation to the diagonal artery from the infundibular coronary artery in obstructive coronary arterial disease. *Int J Cardiol* 1989;25(1):134-6.
 22. Kerensky RA, Franco EA, Hill JA. Antegrade filling of an occluded right coronary artery via collaterals from a separate conus artery, a previously undescribed collateral pathway. *J Invasive Cardiol* 1995;7(7):218-20.
 23. Levin DC, Beckmann CF, Garnic JD, Carey P, Bettmann MA. Frequency and clinical significance of failure to visualize the conus artery during coronary arteriography. *Circulation* 1981;63(4):833-7.
 24. Mishkel GJ, Biagioni E, Stolberg H. Total occlusion of the circumflex artery with collateral supply from the conus artery. *Cathet Cardiovasc Diagn* 1991;23(3):194-97.
-