

An unusual case of retained DJ stentEkka NMP¹, Singh A²¹Dr Nishith M Paul EkkaAssistant Professor
drnmpekka@gmail.com²Dr Arpana Singh

Junior Resident

dr.arpanasingh1985@gmail.com

^{1,2}Department of SurgeryRajendra Institute of Medical Sciences
Ranchi, Jharkhand

Received: 14-03-2017

Revised: 27-03-2017

Accepted: 31-03-2017

Correspondence to:

Dr Nishith M Paul Ekka

drnmpekka@gmail.com

9431358260, 9801452420

ABSTRACT

Double J stents are an integral part of urological practice today. Ureteral stenting is done as an adjunct to ureteral surgery and for managing ureteral obstruction. Every urological surgery doesn't require DJ stenting and their use must be strictly restricted to selected cases. Retention is a common complication of ureteral stents and is mostly due to encrustations on a forgotten DJ stent. Here we report a case of retained DJ stent which was placed during open nephrolithotomy. It was neither forgotten nor encrusted, but was embedded in the renal parenchyma. As per our knowledge this is the first case of its kind to be reported in medical literature.

Key Words: DJ stent, ureteral stent, Double J Stent, stent retention, stent complications, encrustation

Introduction

Double J stents were first described by Zimskind in 1967 and ever since they have been a very important tool for the urologists. [1] Although they are mostly used to prevent complications following urological procedures, they sometimes themselves cause complications like retrograde migration, breakage, encrustations, stone formation and occlusion. Retention is a common complication of a DJ stent and is most commonly encountered when it is forgotten and encrusted. [2] Here we report a case of retained DJ stent which was neither forgotten nor encrusted, but was embedded in the renal parenchyma. This is the first case of its kind to be reported in medical literature.

Case Report

A 40 year old female presented to us for DJ stent removal, which was placed in situ following an open nephrolithotomy two months back. An attempt to remove the stent elsewhere had failed and the patient was referred to us. Initially we thought that its lower end had migrated upwards as the lower end of the stent was not visualised in the urinary bladder in cystoscopy. An IVU was done later which showed that the

lower loop of the DJ stent had straightened. [Fig.1]

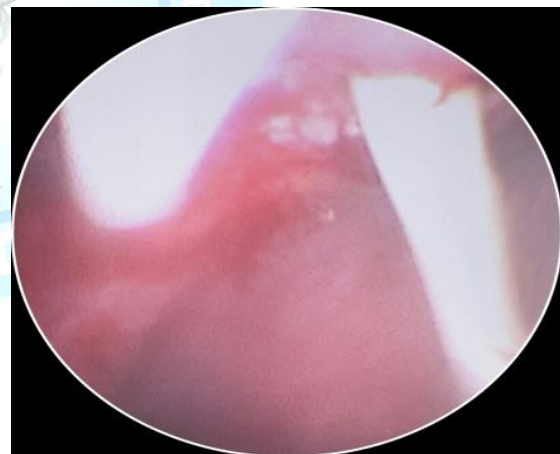


Fig.1 Endoscopic view of renal pelvis showing implanted DJ stent

Patient was planned for URS, during which the lower end of the stent was found in the lower ureter which was pulled out per urethra but the catheter was stuck and we were unable to pull it out. The catheter was then traced upwards by semi-rigid ureteroscope upto the renal pelvis. In combination with the C-Arm fluoroscopy it was observed that almost whole of the upper loop of the ureteric catheter was embedded into the

renal parenchyma. [Fig.2] The procedure was abandoned and an open surgical removal of the stent was planned for a later date. During open surgery the renal pelvis was opened as in extended pyelolithotomy and the DJ stent, embedded in the renal parenchyma, was retrieved. [Fig.3] The pelvis was closed and a closed abdominal drain was left in the retroperitoneum. Patient had an uneventful postoperative recovery and is in follow up at present.

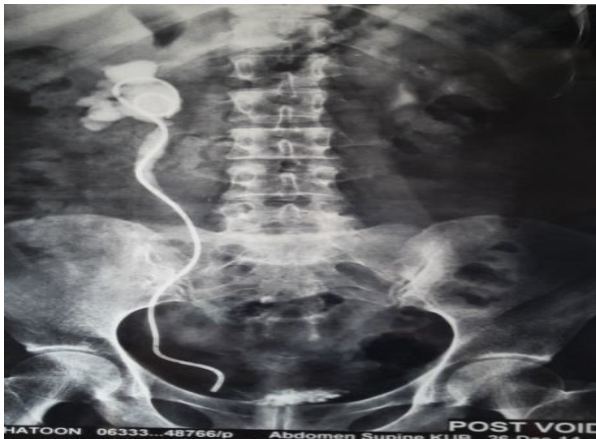

Fig.2 IVU showing DJ stent extending outside the renal pelvis

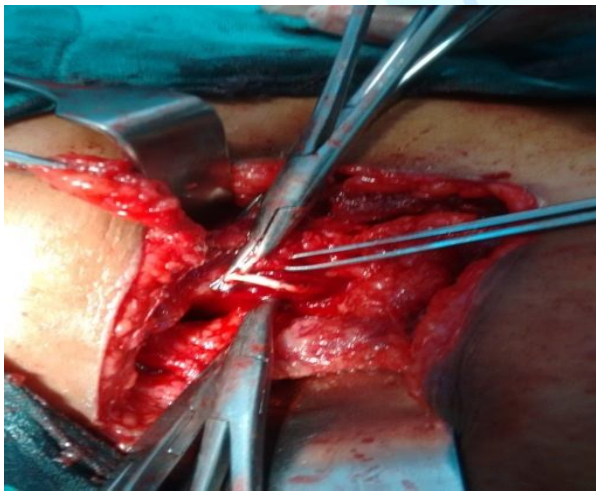


Fig.3 Removal of DJ stent by open surgery

Discussion

The double J stent is a double-edged weapon and, though it is regularly used, its use is not always justified. It is a common procedure in daily urologic practice and provides a convenient means of drainage for the upper urinary tract. [3] The indications for ureteral stenting may be

divided into two main headings: As adjunct to Ureteral surgery (preoperative and / or postoperative) which include ESWL, PCNL, ureteroscopy, endopyelotomy, open / laparoscopic ureteral surgery, ureteric injury and renal transplantation and for managing ureteral obstruction (extrinsic and / or intrinsic) which include stones, strictures, oedema, fistula, tumours, tuberculosis, retroperitoneal fibrosis-tumours and hydronephrosis. [4] Retention of DJ stents is most common when they are forgotten and calcified. Monga et al in their study of 31 cases found that of the retained DJ stents, 71% were forgotten while 29% were due to migration, 68% of the forgotten stents underwent encrustations. [2] Encrustations have been related to the indwelling duration. El-Fiqih et al in their study observed the encrustation rate to be only 9.2% if stent was removed within 6 weeks. However, if the stent was left over for 12 weeks, encrustation rate jumped up to 76.3%. [5] Calcium oxalate (43.8%), especially monohydrate form, constitutes most of the encrustation. [6] Management of such complicated ureteral stents requires multimodal therapeutic approach which includes ESWL, ureteroscopy, cystolithotripsy, and even percutaneous nephrolithotomy (PCNL). [7] Open surgery has a role when multimodal endourology fails or when such a facility is not available. [8]

In our case the stent was neither forgotten nor encrusted but almost the entire upper loop of the stent was embedded into the parenchyma of the kidney. After a lot of web searches we were unable to find any similar case reported in medical literature. Retained DJ stents have been attributed mostly to encrustations on a forgotten stent or stent migration. Ureteric catheter getting embedded in the renal parenchyma has not been seen and can occur when the stent is placed after an open nephrolithotomy. The stent can get caught in between the two raw surfaces of renal parenchyma during closure of the kidney if the stent is not placed properly in the collecting system. The role of a DJ stent after open nephrolithotomy is debatable and in our opinion is not advocated. In open or laparoscopic

ureteral surgery stenting is indicated and justified.^[4]

Conclusion

Ureteral stents have become an integral part of urological practice today. The aim of ureteral stenting should be to prevent complication and not to create one. Every urological surgery doesn't require DJ stenting. We recommend that their use must be strictly restricted to selected cases and routine use should be avoided, as they are not free of complications. It is not indicated in surgeries like open nephrolithotomy and should be avoided.

References

1. Zimskind PD, Kelter TR, Wilkerson SL. Clinical use of long-term indwelling silicone rubber ureteral splints inserted cystoscopically. *J Urol* 1967;97:840-4.
2. Monga M, Klein E, Castaneda-Zuniga WR, Thomas R. The forgotten indwelling ureteral stent: a urological dilemma. *J Urol* 1995 Jun;153(6):1817-9.
3. Vidhyadhar Kelkar, Deepak Patil. Management of forgotten double J stent and severe multiple large encrusted stones in the bladder and renal pelvis. *Cent European J Urol* 2012;65(4):238-41.
4. Iqbal Singh. Indwelling JJ ureteral stents-A current perspective and review of literature. *Indian Journal of Surgery* 2003;65(5):405-12.
5. El-Faqih SR, Shamsuddin AB, Chakrabarti A, Atassi R, Kardar AH, Osman MK, et al. Polyurethane internal stents in treatment of stone patients: Morbidity related to indwelling times. *J Urol* 1991;146(6):1487-91.
6. Bouzidi H, Traxer O. Characteristics of incrustation of ureteric stents in patients with urinary stones. *Prog Urol* 2008;18(4):230-7.
7. Rana AM, Sabooh A. Management Strategies and Results for Severely Encrusted Retained Ureteral Stents. *J Endourol* 2007;21(6):628-32.
8. Somers W. Management of forgotten retained indwelling ureteral stents. *Urology* 1996;47:431-5.

Cite this article as: Ekka NMP, Singh A. An unusual case of retained DJ stent. *Int J Med and Dent Sci* 2017;6(2):1543-1545.

Source of Support: Nil
Conflict of Interest: No