

Histological patterns of Ovarian neoplasms – A five year experience in North-East India

Saha M¹, Banerjee A², Datta A³

¹Dr Manasi Saha (Ray)
Associate Professor
saharaydrmanasi@gmail.com

²Dr Alpana Banerjee
Assistant Professor
banerjeealpana09@gmail.com

³Dr Abhijit Datta
Associate Professor
dattaabhijit@hotmail.com
^{1,2,3}Department of Pathology
Agartala Govt. Medical College & GBP
Hospital

Received: 21-06-2017

Revised: 11-07-2017

Accepted: 25-07-2017

Correspondence to:

Dr Alpana Banerjee
banerjeealpana09@gmail.com

ABSTRACT

Background: Ovary is one of the common sites of neoplasm in females. They manifest in wide spectrum of clinical, morphological and histological features. Ovary is the second most common site of primary malignancy in female genital tract.

Objectives: To study the frequency of different histological types of ovarian tumors and to analyze age distribution of these tumors.

Materials and methods: This was a retrospective study of all cases of ovarian tumors received at Pathology Department of Agartala Government Medical College during the period of 5 years from January 2012 to December 2016.

Results: A total number of 242 cases were studied. Among these 189 cases (78.1%) were benign, 12 cases (4.96%) were borderline and 41 cases (16.94%) were malignant. Benign neoplasms were most commonly seen between 3rd and 5th decade of age whereas malignant neoplasms after 4th decade. Serous cystadenoma was the commonest benign tumor followed by mucinous cystadenoma and mature cystic teratoma. Among the malignant surface epithelial tumors, mucinous cystadenocarcinoma was most common, followed by serous cystadenocarcinoma.

Conclusion: Benign ovarian neoplasms outnumber the malignant ones in all age groups. Surface epithelial tumors are the most common class of tumors and mucinous cystadenocarcinoma is the commonest malignant neoplasm.

Key words: Histological patterns, mucinous cystadenocarcinoma, ovarian neoplasms, surface epithelial tumors

Introduction

Ovaries are paired intrapelvic organs of female reproductive system. Ovarian neoplasm is most fascinating tumor in terms of histogenesis and malignant potential. Certain non-neoplastic lesions of ovary frequently form a pelvic mass and potentially mimic an ovarian neoplasm. Ovarian malignancy is second most common cancer of female reproductive system. [1] It is the fourth leading cause of death among cancer deaths in females and more predominantly after 3rd decade. [2,3] Sixty percent of ovarian tumors in first two decades of life are germ cell tumors accounting two-third of ovarian cancers. [4] Risk factors for ovarian cancer are much less clear than other genital tract tumors but nulliparity, family history and heritable mutation play a role in tumor development. [2] Diagnosing ovarian neoplasms at times difficult without histological studies. Determination of various histological patterns of ovarian tumors is very important in the diagnosis, prognosis as well as treatment of ovarian tumors. The study was conducted with the aim of finding out the frequency of different histological types of ovarian tumors and to analyze their age distribution.

Materials and Methods

This retrospective study included 242 consecutive cases of histopathologically proven ovarian tumors, reported by the Department of Pathology of this teaching institute over a period of 5 years (January 2012 to December 2016). Only benign and malignant tumors were included, all non-neoplastic or like lesions of ovary were excluded. Haematoxylin and Eosin (H&E) stained slides of all cases were retrieved. New sections of 3-5 micron were made from paraffin blocks and stained with H&E whenever felt necessary and sections were studied. The WHO classification of ovarian tumors was used for classifying the tumors. [5] All required data were retrieved from the records. Data was categorized and percentage calculated.

Results

A total number of 242 cases were studied. Out of those 189 cases (78.1%) were benign, 12 cases (4.96%) were borderline and 41 cases (16.94%) were malignant tumors. Surface epithelial tumors were most common followed by germ cell tumors & then sex cord stromal cell tumor (Table 1).

Table 1: Frequency distribution of ovarian neoplasm according to histological types

Types of tumor	Benign	Borderline	Malignant	Total
Surface epithelial tumors	129 (53.3%)	12 (4.96%)	29 (11.93%)	170 (70.25%)
Germ cell tumor	55 (22.72%)	--	8 (3.31%)	63 (26.03%)
Sex cord stromal tumors	5	--	1	6 (2.48%)
Metastatic tumors	--	--	3 (1.24%)	3 (1.24%)
Total	189 (78.1%)	12 (4.96%)	41 (16.94%)	242 (100%)

Benign neoplasms were most commonly seen below 3rd decade, whereas malignant neoplasms were common after 3rd decade (Table 2 & 3). The youngest patient in our study was an eight years old girl and morphologically the diagnosis was immature teratoma (Fig. 1). The eldest patient was 82 years old with the diagnosis of metastatic ovarian tumor (Fig.2)). Age distributions of benign, borderline and malignant tumors are given in Table 2, 3. Out of 170 surface epithelial tumors 75.29% were benign, 17.05% were malignant and 7% were borderline.

Among the benign surface epithelial tumors, serous cystadenoma (53.49%) was the commonest followed by mucinous cystadenoma (45.73 %) and those tumors were found to be more common between 2nd and 4th decade of life as depicted in Table 2. Germ cell neoplasms constituted 26.03 % of all ovarian neoplasms in this study (Fig.3). Most of the germ cell neoplasms (87.3%) were benign and diagnosed as mature cystic teratoma or dermoid cyst. Three cases were dysgerminomas and another three cases were squamous cell carcinomas associated with dermoid cysts. Among the malignant tumors, incidence of mucinous cystadenocarcinoma was more than that of serous cystadenocarcinoma (34.2% & 26.8% respectively).

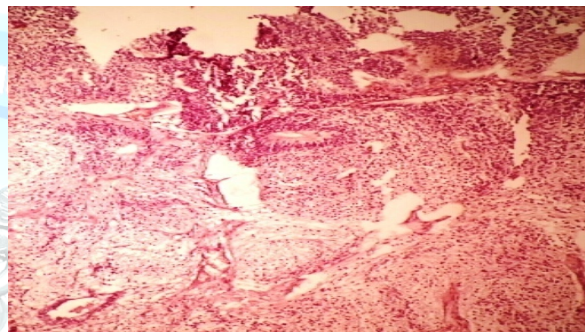
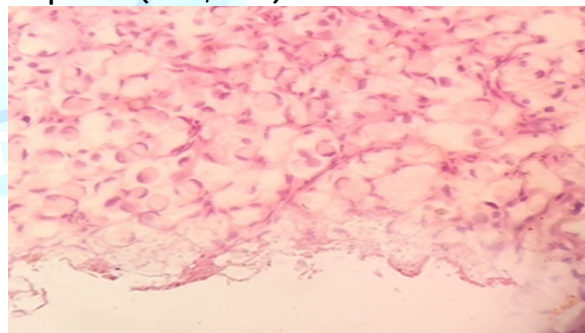
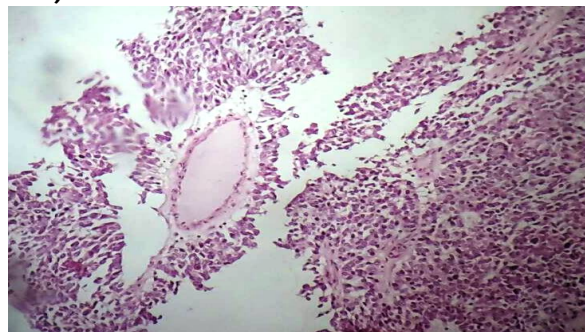
**Fig 1: Immature teratoma, immature neuronal components (H & E, X 100)****Fig 2: Metastatic adenocarcinoma, signet ring cells (H & E, X400)****Fig 3: Germ cell tumor (H & E, X100)**

Table 2: Frequency of different histologically benign & borderline tumor in different age groups

Age in years							
Histological type	0-20	21-30	31-40	41-50	51-60	>60	Total
Serous cystadenoma	8(40%)	26(33.8%)	13(28.2%)	12(46.2%)	5(45.4%)	5(55.5%)	69
Mucinous cystadenoma	5(25%)	24(31%)	14(30.4%)	8(30.7%)	4	4	59
Benign mature teratoma	7(35%)	26(33.7%)	15(32.6%)	6(23%)	1	-	55
Fibroma			03	-	1	-	03
Fibrothecoma		01					01
Lipid cell tumor			01				01
Total	20	77	46	26	11	9	189
Borderline tumor	1	4	2	4	0	1	12

Table 3: Frequency of individual malignant tumor in different age groups

Age in years							
Histological type	< 20	21-30	31-40	41-50	51-60	>60	Total
Serous cystadenocarcinoma		1	4(36.3%)	1	3(27.3%)	2	11(26.8%)
Mucinous cystadenocarcinoma		2	4(28.6%)	5(35.7%)	3(21.4%)		14(34.2%)
Endometroid carcinoma				1			01
Malignant Brenner					1	1	02
Transitional cell carcinoma		1					01
Immature teratoma	1						01
Squamous cell carcinoma		1			1	1	03
Dysgerminoma	1	1		1			03
Choriocarcinoma				1			01
Granulosa cell tumor	1						01
Metastatic carcinoma					2	1	03
Total	3	6	8	9(21.9%)	10(24.4%)	5	41

Discussion

Ovarian neoplasm has become important not only because of large variety of histological patterns but also because of its clinical behavior and increased mortality rate. 242 cases were studied in the present study. The median age of presentation of all ovarian tumors was 34 years while the median age of presentation of all malignant lesions was 44 years. In another study

from Eastern India, the median age for malignant lesion was 48 years. ^[1] A higher median age of 60-65 years for malignant lesions had been reported from western countries and from southern and western part of India. ^[6,7,8] Malignant epithelial and sex cord stromal tumors were found to be more common after 50 years, while germ cell tumors were more prevalent before age of 20

years. [6] In the present study, the malignant epithelial tumors were found predominantly in 30- 60 year of age. However three cases were found below thirty years of age and all the three belong to tribal/ ethnic community. The early presentation of malignant lesions in our study compared to western countries warrants prompt and thorough investigation of any vague abdominal complain in women of this age group. Our observations are compared with that of other studies as shown in Table 4. Our findings were almost similar to those by other workers and data from western countries where 75-80% of ovarian tumors were benign. However, benign tumors were only 59.2% in the study of Ahmad et al in Pakistan. [10] 137 ovarian tumors (56.6%) were found in between 21-40 years of age and

89.8 % of them (123/137) were benign. The percentage of benign tumor was 65.7% (46/70) after 40 years of age. Malignant tumors were far less common below 40 years. This is similar to the study by Dimpal et al and Jha et al; but the study done by Nirani et al showed maximum number of malignant tumor to be in 5th to 6th decade. [12,13,14] Malignant tumors occurring before 20 years were mostly germ cell tumors. The incidence of borderline tumor was relatively more in the present study as compared to other studies (Table 4). Fifty percent of borderline tumors in our study were from tribal/ ethnic group and more common in younger age group. Different histological types of ovarian tumors according to histogenesis were compared with that of other studies in Table 5.

Table 4: Comparison of frequencies of benign, borderline and malignant tumors in different studies

	Authors	Benign (%)	Borderline (%)	Malignant (%)
1	Mondal et al [1]	63.01	7.3	29.6
2	Pilli et al [9]	75.2	2.8	21.8
3	Ahmad et al [10]	59.18	0.02	40.18
4	Yagambal et al [11]	78.6	0.75	20.65
5	Nirani et al [12]	84.76	2.3	13.21
6	Dimpal et al [13]	84.53	2.07	13.40
7	Present study	78.1	4.96	16.94

Table 5: Relative percentage of different histological types of ovarian tumors in different studies

	Authors	Epithelial	Germ cell tumor	Sex cord stromal	Metastatic
1	Mondal et al [1]	67.9%	23.1%	5.6%	3.2%
2	Pilli et al [9]	71.1%	21.2%	7%	0.70%
3	Jha et al [14]	52.2%	42.2%	3.1%	2.4%
4	Nirani et al [12]	73.8%	17.6%	6.1%	--
5	Dimpal et al [13]	76.3%	17.8%	6.1%	2.3%
6	Swati Singh et al [15]	69.17%	25.83%	4.17%	0.83%
7	Present study	70.25%	26.03%	2.48%	1.24%

Present study results are comparable to many other studies, but in contrast with Jha et al which showed relatively more number of germ cell tumors. [14] The incidence of sex cord stromal tumors was relatively less in our study. Histologically, surface epithelial tumors were the commonest. The major burden of malignant

tumors were also contributed by this group. [7] Similarly in the present study, surface epithelial tumors comprised of 70.25% of all tumors and 70.7% of malignant group. Among the individual tumors, the commonest benign epithelial tumors were serous cystadenoma (53.49%) followed by mucinous cystadenoma (45.73%). Among primary

malignant tumors mucinous cystadenocarcinoma was most common, followed by serous cyst adenocarcinoma. Incidence of mucinous cystadenocarcinoma was more common as compared to Nirani et al and Swati Singh et al. [9,12] Endometrioid ovarian carcinoma accounted for 10-20% of all primary carcinoma in most of the old study reports, but in more recent study it is only 7%. [16] In a study from eastern India endometrioid tumors (malignant type) comprised of 4.2% of all malignant ovarian tumors and in our study it is only 2.4%. [1] This may be a reflection of geographic variation of diseases.

Germ cell tumors were the second major group of tumors in the present study (26.03%). Mature teratoma was the commonest benign germ cell tumor in our study. Malignant transformation in mature cystic teratoma of the ovary is rare, occurring only 1-2%. [17] But in the present study, out of 63 ovarian germ cell tumors three(4.7%) had squamous cell carcinoma, arising from a mature teratoma. Incidence of Krukenberg tumor was 7.3% of all malignant tumors. One of the most important morphological features suggesting a metastatic mucinous carcinoma is presence of signet ring cells, besides bilateral involvement and nodular growth pattern which were true in our cases. Tumors in the borderline category are characterized by epithelial proliferation greater than two layer and less than four layers stratification but absence of destructive invasion of stroma. [18] In our series, we encountered 12cases (4.96%) of borderline tumor, 58.3% (7/12) of those were from ethnic/tribal groups. Youngest patient was 22 years old. This is comparatively higher and seen in younger ages in comparison to other studies. [8]

Epithelial tumors of ovary were the commonest ovarian tumors followed by germ cell tumors. The most common ovarian neoplasm was serous cystadenoma and commonest malignant neoplasm was mucinous cystadenocarcinoma. Germ cell tumors were seen in all the age groups but more common below 30 years of age. Malignant tumors were common after 30 years. These findings may contribute significantly in the understanding of distribution of different ovarian

neoplasms among local population, which may lead to development of some strategic planning to investigate and treat the underlying causes of concerned neoplasm and may suggest preventive strategies.

References

1. Mondal S, Banyopadhyaya R, Nag D, Roychowdhury S, Mondap P, Sinha S. Histological pattern, bilaterality and clinical evaluation of 957 ovarian neoplasms: A 10 – year study in a tertiary hospital of eastern India. *Journal of Cancer research and Therapeutics* 2011;7(4):433-7.
2. Sen V, Sankaranaryana R, Mandal S, Romana AV, Parkin DM, Siddique M. Cancer patterns in Eastern India. The first report of Kolkata Cancer registry. *Int J Cancer* 2002;100:86-91.
3. Tortolerol, Mitchel FM, Rhodes HE. Epidemiology and screening of ovarian cancer. *Obstet Gynaecol Clin North Am* 1994;21:63-75.
4. Scully Robert E, Young Robert H. Clement Phillip B. Atlas of tumor pathology. Tumors of ovary, maldeveloped gonads, fallopian tube and broad ligament. 3rd series, fascicle 23. Armed force institute of pathology, 1999.
5. Shahrzad Ehdaivand. WHO classification of ovarian neoplasm. Pathology outline.com website <http://www.pathologyoutlines.com/topic/ovarytumorwhoclassif.html>. Accessed February 27th.2017
6. Murthy NS, Shalini S, Suman G, Pruthvish S, Mathew A. Changing trends in incidence of ovarian cancer- the Indian scenario. *Asian Pac J Cancer Prev* 2009;10:1025-30.
7. Yancik R. Ovarian cancer. Age contrast in incidence, histology, disease stage at diagnosis, and mortality. *Cancer* 1993;71(S2):517-23.
8. Quirk JT, Natarajan N. Ovarian cancer incidence in United States, 1992-99. *Gynecol Oncol* 2005;97:519-23.
9. Pilli GS, Suneeta KP, Dhaded AV, Yenni VV. Ovarian tumor. A study of 282 cases. *J Indian Med Assoc* 2002;100:420-7.

10. Ahmad Z, Kayani N, Husan SH, Muzaffar S, Gill MS. Histological pattern of ovarian neoplasm. Pak J Pathol 2005;16:28-32.
11. M Yogambal, P Arunalatha, K Chandramouleeswari, V Palaniappan. Ovarian tumors – Incidence and distribution in tertiary referral center in south India. IOSR-JDMS 2014;13(2):74-80.
12. Nirali N Thakkar, Shaila N Shah. Histopathological Study of Ovarian Lesion. International journal of Science and Research (IJSR) 2015;4(10)1745-9.
13. Dimpal Modi, Gunvanti B Rathod, KN Delwadia, HM Goswami. Histopathological pattern of neoplastic ovarian lesions. IAIM 2016;3(1):51-7.
14. R Jha, S Karki. Histopathological pattern of Ovarian tumors and their age distribution. Nepal Med coll J 2008;10(2):81-5.
15. Swati Singh, Veena Saxena, Suman Lata Khatri, Sumit Gupta, Jayadeep Garewal, Krishna Dubey. Histopathological Evaluation of Ovarian Tumors. Imperial Journal of Interdisciplinary Research (IJIR), 2016;2(4):435-9.
16. Seidman JD, Harkaynae SI, Cosin JA, Ryu HS, Haiba M, Boice CR. Testing of two binary grading system for FIGO stage III serous carcinoma of the ovary and peritoneum. Gynecol Oncol 2006;103:703-8.
17. Choudhury S, Hussain R. Squamous cell carcinoma arising in mature cystic teratoma (dermoid cyst)—a rare presentation. J Pak Med Assoc 2013;63(4):521-3.
18. Barkat RR. Borderline tumors of Ovary. Obstet Gynaecol Clin North Am 1994;21:93-105.

Cite this article as: Saha M, Banerjee A, Datta A. Histological patterns of Ovarian neoplasms – A five year experience in North-East India. Int J Med and Dent Sci 2018;7(1):1576-1581.

Source of Support: Nil
Conflict of Interest: No