

**Morphometric study of axis vertebra in subjects of Indian origin**Kaur J<sup>1</sup>, Kaur K<sup>2</sup>, Singh P<sup>3</sup>, Kumar A<sup>4</sup>

<sup>1</sup>Dr Jasveen Kaur  
Assistant Professor  
jsvn.kr@gmail.com  
<sup>2</sup>Dr Kamaljeet Kaur  
Assistant Professor  
kamaljeetkaurvij@gmail.com  
Dr Poonam Singh  
Ex Prof. & Head, Anatomy  
DMCH, Ludhiana  
Dr Ajay Kumar  
Professor, Anatomy  
DMCH, Ludhiana  
<sup>1,2,3,4</sup>Department of Anatomy  
1,2Punjab Institute of Medical Sciences  
Jalandhar, Punjab, India

Received: 17-09-2017

Revised: 01-10-2017

Accepted: 14-10-2017

Correspondence to:

Dr Jasveen Kaur  
jsvn.kr@gmail.com**ABSTRACT**

**Background:** The axis vertebra, exhibits complex and extensive variability in the morphology and there are vital neurovascular structures in its proximity. Knowledge of this variability is important for neurosurgeons, orthopaedicians, otorhinologists and other physicians who in everyday practice are in contact with disorders of the spine and their consequences.

**Objective:** The aim was to evaluate various morphometric dimensions of axis vertebrae and to compare with the available data.

**Material and methods:** 50 dried human axis vertebrae of Indian origin, available in the Department of Anatomy, Dayanand Medical College and Hospital, Ludhiana were studied. Various dimensions were taken with vernier calipers, metric scale and graph paper. The dimensions were measured in millimetres and statistically analysed with paired t-test.

**Results:** The mean of maximum anteroposterior diameter (max.APD) and maximum transverse diameter (max.TD) of Superior Articular Facet (SAF) was measured as 17.42mm±1.73 and 15.31mm±1.44 on the right side, 17.64mm±1.51 and 15.17mm±1.48 on left side. The mean Distance from Lateral most edge of SAF to Midline was measured as 22.56mm± 2.37 and 22.40mm± 2.16 on the right and left sides, respectively. The mean Distance from Tip of Transverse Process to Midline was 26.45mm± 2.85 on the right and 26.03mm± 2.64 on the left side. The mean Height of Dens was measured as 13.83mm ± 1.52, mean Width of Dens as 9.57mm ± 0.85. Width of Pedicle was measured as 10.52mm ± 1.99 and 10.61mm ± 1.67on right and left sides, respectively.

**Conclusion:** The knowledge of these dimensions can provide useful information for safe planning of osseous fixation.

**Keywords:** Axis, dens, pedicle, articular facet, vertebra

**Introduction**

The axis (C2), also called the epistropheus, is the second vertebra of the cervical spine; it creates a pivot joint between the head and neck. Its strongest characteristic is the dens or the odontoid process(OP) which is responsible for two distinct articulations. The first articulating surface comprises of an anterior surface which is oval in shape and in contact with the atlas. The second is in contact with the transverse ligament. Two distinct regions characterise the cervical spine; the occipitoatlantoaxial region (C1-C2) and the sub-axial region(C3-C7).The odontoid process represents the foundation of stability at the atlantoaxial articulation due to attached ligamentous structures.<sup>[1]</sup> The pedicle of axis, which courses from the body of axis to the dorsal surface of the articular surface of axis, is located more medially and ventrally than other cervical spine pedicles.<sup>[2]</sup> Its a strong structural element of the vertebrae, as in thoracic and lumbar spine. Thus reconstructions of the cervical spine by

using pedicles for screw fixation techniques have greater ability to support axial loads.<sup>[3]</sup> Nevertheless, depending on the size of the pedicles and the proximity of the vertebral artery as well as the dural sac and the nerve roots, there are potential risks of iatrogenic damage to neural and vascular structures.<sup>[4,5]</sup>

The laminae of axis fan out laterally to the articular masses. An articular mass is composed of a superior and inferior articular pillar.<sup>[2]</sup> In the axis vertebra, two characteristics of superior articular facet differ from the facets of all other vertebrae. Firstly, its proximity to the corpus and the medial aspect of pedicle axis when compared to the other facets, are located in proximity to the junction of the pedicle and lamina. Secondly, and more crucial is that vertebral artery foramen is present partially or completely in the undersurface of superior articular facet of axis while in other cervical vertebrae it is located entirely in relation to foramen transversarium.<sup>[6]</sup>

The axis is often described as a transitional vertebra. The weight of cranium is transferred from the occipital condyles and lateral masses of atlas to lateral masses of axis. From here the weight is transferred anteriorly to the axis body and subsequently to vertebral bodies of lower cervical vertebra. The spinal canal is more capacious at C1-2 than anywhere else, and the spinal cord is located close to instantaneous axis of rotation, which minimises distortion of spinal cord during rotation.<sup>[7]</sup>

Fractures of axis account for 18% of all cervical injuries of which odontoid fractures continue to be associated with significant morbidity and mortality.<sup>[8,9]</sup> Hangman's fracture with the hyperextension of head on neck is a well characterised injury of axis.<sup>[10,11]</sup> Congenital C2 malformations (e.g. odontoideum and odontoid agenesis), degenerative diseases, inflammatory diseases, tumors, are also known.<sup>[12]</sup> Instability at the atlas and axis requires internal fixation not only for immediate stability, but also to provide long-term immobility so as to attain a solid fusion.<sup>[13]</sup> There are a wide variety of surgical techniques to achieve this, including anterior odontoid screw fixation or posterior fusion methods such as Gallie-type fusion, Brooke-Jenkins technique, interlaminar clamps or Sonntag's modified Gallie fusion.<sup>[14]</sup> Previously wiring methods like sublaminar, spinous process, tension band, facet and triple wiring were done.<sup>[15]</sup> Recently, transarticular and transpedicular screw fixation have been widely used.<sup>[16]</sup> As these surgical techniques and instruments continue to evolve, a detailed and precise knowledge about the cervical spine and surrounding anatomy is required. To the best of our knowledge few studies have been conducted on subjects of Indian origin. Keeping this in mind, the current study on the morphometry of human axis vertebrae in subjects of Indian origin was taken.

### Material and Methods

Fifty axis vertebrae, available in the Department of Anatomy, Dayanand Medical College and Hospital, Ludhiana were studied. The specimens selected were dry, complete, human cadaveric

vertebrae of Indian origin without gross pathology. Various dimensions were measured with the help of Vernier Calipers, metric scale and graph paper. All the measurements were recorded in millimetres and bilaterally wherever applicable. The measured data was statistically analysed including test of significance (paired t-test). Comparison was done with existing studies. The  $p$  value  $< 0.05$  was considered to be significant and  $> 0.05$  was considered to be insignificant.

### Results

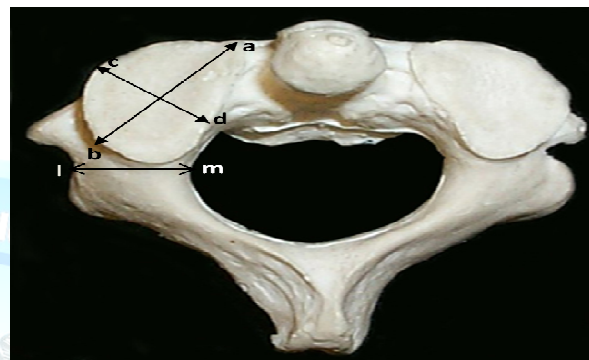


Fig. 1: Axis – Superior View; a – b: Maximum AP Diameter of SAF; c – d: Maximum TD of SAF; l – m: Width of Pedicle – horizontal diameter of the pedicle taken from its internal surface to the external surface at the level of foramen transversarium

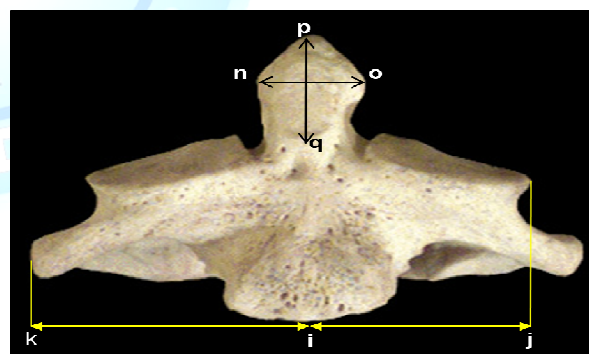


Fig. 2: Axis – Anterior View; i – j: Distance from Lateral most Edge of SAF to Midline; i – k: Distance from Tip of Transverse Process to Midline; n – o: Maximum Width of Dens; p – q: Maximum Height of Dens distance from the tip of dens to the horizontal line, which arbitrarily passed superior to SAF of axis

Observations were recorded and tabulated. Table no 1 shows the measurements that were recorded. The maximum APD (Anterior – posterior Diameter) of SAF (Superior Articular Facet) ranged from 13.20mm – 23.54mm on the right side and 13.52mm – 22.44mm on the left side. The range

of maximum TD(Transverse Diameter) of SAF was recorded as 12.20mm – 18.34mm on the right and 12.78mm – 19.22mm on the left side. The mean Distance from Lateral most edge of SAF to Midline was measured as 22.56mm± 2.37 and 22.40mm± 2.16 on the right and left sides, respectively. The mean Distance from Tip of Transverse Process to Midline was 26.45mm±

2.85 on the right and 26.03mm± 2.64 on the left side. The height of Dens ranged between 11.14mm – 17.32mm. The mean Width of Dens was 9.57mm ± 0.85. The mean Width of Pedicle was measured as 10.52mm ± 1.99 and 10.61mm ± 1.67 on right and left sides, respectively.

**Table 1 : Dimensions On Axis**

Dimension	Range (mm)	Mean
<b>Max. APD of Superior Articular Facet</b>	R - 13.20 – 23.54	17.42±1.73
	L - 13.52 – 22.44	17.64±1.51
<b>Max. TD of Superior Articular Facet</b>	R- 12.20 – 18.34	15.31±1.44
	L- 12.78 – 19.22	15.17±1.48
<b>Distance from Lateral most Edge of SAF to Midline</b>	R - 18.00 – 30.12	22.56± 2.37
	L -18.50 – 29.50	22.40± 2.16
<b>Distance from Tip of Transverse Process to Midline</b>	R - 20.20 – 34.20	26.45± 2.85
	L - 19.20 – 31.52	26.03± 2.64
<b>Height of Dens</b>	11.14 – 17.32	13.83 ± 1.52
<b>Width of Dens</b>	8.34 – 11.74	9.57 ± 0.85
<b>Width of Pedicle</b>	R - 6.24 – 15.50	10.52 ± 1.99
	L- 7.64 – 15.68	10.61 ± 1.67

### Discussion

Posterior transarticular fixation at the level of SAF of axis and IAF of atlas provides rigidity as well as preserves motion between atlanto-occipital joint. This procedure is advantageous in situations such as significant disruption of C1 posterior arch, canal compromise, posterior subluxation and congenital anomalies. For the locations of points of screw insertion on the SAF the knowledge of its dimensions is necessary.

Table 2 reveals that there is similarity between the values of the present study and most of the previous studies. Konig et al<sup>[17]</sup> has used a grid system to measure the dimensions which might have lead to higher values. Cattrysse et al<sup>[18]</sup> evaluated pairs of atlas and axis vertebrae from same spine and found that the C1 IAF has lower APD than the SAF of C2. The TD observed by Kandziora et al<sup>[19]</sup>, Gomez-Olivencia et al<sup>[20]</sup> and Cattrysse et al<sup>[18]</sup> have higher values than our

study. Whereas Sengul et al<sup>[6]</sup> has lower value, Konig et al<sup>[17]</sup> is closest. The variations depict that these could be as a result of racial and ethnic differences between these study groups.

As the lateral margins of SAF of axis overhang on the vertebral artery foramen, the foramen may be present partially or completely below the facet. The distance from the lateral most edge of SAF to midline and the distance from tip of transverse process to midline provide safe zones for the anterior transoral approaches, which may prevent damage to vertebral artery.

Type II and III odontoid fractures may require odontoid screw fixation. This requires knowledge regarding the diameter of odontoid process. Large OP can be fixated with two screws, whereas narrow OP can be fixed with one screw. The table 3 shows that observation in present study is lower but comparable with previous

authors. Mazzara et al<sup>[21]</sup> and Doherty<sup>[22]</sup> et al have similar values. Jasinki et al<sup>[23]</sup> has given individual measurements and not an average value. Kandziora et al<sup>[19]</sup> has measured this

parameter radiologically as well. It can be assumed that this difference in our study and the rest may be the result of racial disparity.

**Table 2: Comparison of Diameters of Superior Articular Facet**

Author	Origin	Dimension (mm)APD		Dimension (mm)TD	
		Right	Left	Right	Left
Kandziora et al	European	17.0 ± 1.1		16.6 ± 1.25	
Konig et al	German	19.1 ± 2.1	18.7 ± 2.2	15.3 ± 2.0	16.4 ± 1.8
Sengul et al	Turkish	17.5 ± 1.4	17.5 ± 1.5	14.1 ± 1.6	14.0 ± 1.5
Gomez-Olivencia et al	Spanish	17.7 ± 1.2	18.1 ± 1.4	16.4 ± 1.3	16.3 ± 1.4
Cattrysse et al	Belgian	17.9 ± 1.8	17.7 ± 1.4	17.5 ± 1.9	17.2 ± 2.8

**Table 3: Comparison of dimensions of Dens**

Author	Origin	Height(mm)	Width(mm)
Mazzara et al	American	15.4 ± 2.4	10.5 ± 1.0
Doherty et al	American	16.6 ± 1.9	10.8 ± 1.0
Kandziora et al	European	20.3 ± 1.9	10.80 ± 0.84
Jasinki et al	Polish	19.50 – 22.85	10.25 – 12.50
Sengul et al	Turkish	14.5 ± 2.3	11.02 ± 1.8
Naderi et al	Turkish	15.5 ± 1.8	10.5 ± 0.9

**Table 4: Comparison of Width of Pedicle**

Author	Origin	Dimension (mm)	
		Right	Left
Kazan et al	Turkish	10.72 ± 1.53	10.71 ± 1.44
Mandel et al	American	7.4 ± 1.7	8.0 ± 1.7
Sengul et al	Turkish	9.6 ± 2.4	9.5 ± 2.2
Hoh et al	American	9.3 ± 1.3	9.6 ± 1.3

The table 4 shows that the values observed in the present study are higher than most of the existing studies. But Madawi et al<sup>[24]</sup> has given the maximum range as 12.2mm, Solanki et al<sup>[25]</sup> as 12.2 mm, Mandel et al<sup>[26]</sup> as 14.7mm, Bloch et al<sup>[27]</sup> as 11.8mm, Gupta et al<sup>[28]</sup> as 12mm and Cacciola et al<sup>[29]</sup> as 11.4mm. This depicts that even though the average is different their ranges are comparable to our study. Kazan et al<sup>[30]</sup>,

Sengul et al<sup>[6]</sup> and Hoh et al<sup>[31]</sup> have studied this bilaterally and there is symmetry on both the sides. As various methods are approached for the treatment of traumatic and non-traumatic occipito-cervical instability, several studies were conducted to establish guidelines for placement of C2 pedicle screws, but adherence to such logarithm approaches failed to take into account individual variation and too often result in breach



of pedicle. It can cause damage to the adjoining neurovascular structures. Surgeon must have full knowledge of each patient's anatomy.

Various instruments and procedures used in cervical spine surgery are dependent on the size of vertebra. These can range from simple inter-spinous wires to segmental fixation with hooks, rods and screw posteriorly; plating and segmental fixation anteriorly. The basic principle is to provide strong, mechanical bony fixation with least risk to neurovascular elements. Our study has highlighted that it is difficult to go by pre-set standards of sizes as there is a lot of variation. However the best selection of treatment depends on understanding the anatomy, the mechanism in injury, the forces involved and the options that are available to stabilize and protect the spinal column and cord.

## References

- Johnston M, Ranieri S, de Wit W. Proposal of a new method of treating type II odontoid fractures: Odontoid process prosthetic (Ti). Studies by Undergraduate Researchers at Guelph 2008;1(2):49-56.
- Pait TG, Arnautovic KI, Borba LA. The anatomy of atlantoaxial complex. *Perspect Neurol Surg* 1997;7:91-8.
- Abumi K, Kaneda K. Pedicle screw fixation for nontraumatic lesions of the cervical spine. *Spine* 1997;22(16):1853-63.
- Richter M, Amiot LP, Neller S, Kluger P, Puhl W. Computer-assisted surgery in posterior instrumentation of the cervical spine: an in-vitro feasibility study. *Eur Spine J* 2000;9(1):65-70.
- Reddy C, Ingalthalikar AV, Channon S, Lim T, Torner J, Hitchon PW. In vitro biomechanical comparison of transpedicular versus translaminar C-2 screw fixation in C2-3 instrumentation. *J Neurosurg Spine* 2007oct; 414-8.
- Sengul G, Kadioglu HH. Morphometric anatomy of the atlas and axis vertebrae. *Turk Neurosurg* 2006;16(2):69-76.
- York JE, Klimo P, Apfelbaum RI. Treatment of Axis Fractures. In: Winn HR, Dacey Jr RJ, Sonntag VK, Vollmer DG, editors. *Youmans Neurological Surgery*. 5<sup>th</sup> ed. Philadelphia: Saunders; 2004.p.4939-49.
- Shetty A, Kini AR, Prabhu J. Odontoid fractures: a retrospective analysis of 53 cases. *IJO* 2009;43(4):352-60.
- Bellarbarba C, Mirza SK, Chapman JR. Injuries of the Craniocervical Junction. In: Bucholz RW, Heckman JD, Court-Brown CM, editors. *Rockwood and Green's Fractures in Adults*. 6<sup>th</sup> ed. Philadelphia: Lippincott Williams & Wilkins; 2006.p.1435-96.
- Wood II GW. Fractures, Dislocations and Fracture-Dislocation of the Spine. In: Canal ST, Beaty JH, editors. *Campbell's Operative Orthopedics*. 11<sup>th</sup> ed. Philadelphia: Mosby Elsevier; 2008.p.1761-850.
- Chittiboina P, Wylen E, Ogden A, Mukherjee DP, Vannemreddy P, Nanda A. Traumatic spondylolisthesis of the axis: a biomechanical comparison of clinically relevant anterior and posterior fusion techniques. *J Neurosurg Spine* 2009;11:379-87.
- Sorrenti L, Iamaguchi MM, Sposeto RB, Araujo MP, Iutaka AS, Filho TE, et al. Posterior instrumentation for laminar screw of C2: a dimensional anatomic study of axis. *Acta Orthop Bras* 2009;17(4):219-23.
- Vilela MD, Jermani C, Braga BP. C1 lateral mass screws for posterior segmental stabilization of the upper cervical spine and a new method of three-point rigid fixation of the C1-C2 complex. *Arq Neuropsiquiatr* 2006;64(3-B):762-7.
- Wright NM, Laurysen C. Vertebral artery injury in C1-2 transarticular screw fixation: results in a survey of the AANS/CNS section on disorders of the spine and peripheral nerves. *J Neurosurg Spine* 1998 april;88:634-40.
- Lundy DW, Murray HH. Neurological deterioration after posterior wiring of the cervical spine. *The Journal of Bone And Joint Surgery*. 1997;79B(6):948-51.
- Miyamoto H, Uno K. Cervical pedicle screw insertion using a computed tomography cutout technique. *J Neurosurg Spine* 2009 dec;11:681-7.

17. Konig SA, Goldammer A, Vitzthum HE. Anatomical data on the craniocervical junction and their correlation with degenerative changes in 30 cadaveric specimens. *J Neurosurg Spine* 2005 nov;3:379-85.
18. Cattrysse E, Provyn S, Gagey O, Kool P, Clarys JP, Roy PV. In vitro three dimensional morphometry of the lateral atlantoaxial articular surfaces. *Spine* 2008;33(14):1503-8.
19. Kandziora F, Schulze-Stahl N, Khodadadyan-Klostermann C, Schroder R, Mittlmeier T. Screw placement in transoral atlantoaxial plate systems: an anatomical study. *J Neurosurg (Spine1)* 2001july;95:80-7.
20. Gomez-Olivencia A, Carretero JM, Arsuaga JL, Rodriguez-Garcia L, Garcia-Gonzalez R, Martinez I. Metric and morphological study of the upper cervical spine from Sima de los Huesos site(Sierra de Atapuerca, Burgos, Spain). *J Hum Evol* 2007;53:6-25.
21. Mazzara JT, Feilding JW. Effect of C1-C2 rotation on canal size. *Clin Orthop Relat Res* 1988;237:115-9.
22. Doherty BJ, Heggeness MH. Quantitative anatomy of the second cervical vertebra. *Spine* 1995;20(5):513-7.
23. Jasinski R, Pezowicz C. Experimental investigation of the axis dens fracture. *Acta Bioeng Biomech* 2004;6(1):51-61.
24. Madawi AA, Casey AT, Solanki GA, Tuite G, Veres R, Crockard HA. Radiological and anatomical evaluation of the atlantoaxial transarticular screw fixation technique. *J Neurosurg* 1997 june;86:961-8.
25. Solanki GA, Crockard HA. Preoperative determination of safe superior transarticular screw trajectory through the lateral mass. *Spine* 1999;24(14):1477-82.
26. Mandel IM, Kambach BJ, Petersilge CA, Johnstone B, Yoo JU. Morphologic considerations of C2 isthmus dimensions for the placement of transarticular screws. *Spine* 2000;25(12):1542-7.
27. Bloch O, Holly LT, Park J, Obasi C, Kim K, Johnson JP. Effect of frameless stereotaxy on the accuracy of C1-2 transarticular screw placement. *J Neurosurg Spine* 2001july;95:74-9.
28. Gupta S, Goel A. Quantitative anatomy of the lateral masses of the atlas and axis vertebrae. *Neurol India* 2000 june;48:120-5.
29. Cacciola F, Phalke U, Goel A. Vertebral artery in relationship to C1-C2 vertebrae: An anatomical study. *Neurol India* 2004 june;52(2):178-84.
30. Kazan S, Yildirim F, Sindel M, Tuncer R. Anatomical evaluation of the groove for the vertebral artery in the axis vertebrae for atlanto-axial transarticular screw fixation technique. *Clin Anat* 2000;13:237-43.
31. Hoh DJ, Liu CY, Wang MY. A radiographic computed tomography- base study to determine the ideal entry point, trajectory, and length for safe fixation using C-2 pars interarticularis screws. *J Neurosurg Spine* 2010 june;12:602-12.

Cite this article as: Kaur J, Kaur K, Singh P, Kumar A. Morphometric study of axis vertebra in subjects of Indian origin. *Int J Med and Dent Sci* 2018;7(1):1615-1620.

Source of Support: Nil  
Conflict of Interest: No