

## To study the functional outcome of arthroscopic ACL reconstruction using hamstring graft fixed with endobutton for femur and interference screw and suture post for tibial fixation

Robindro P<sup>1</sup>, Latchumi NVK<sup>2</sup>, Kanthimathi BD<sup>3</sup>

<sup>1</sup>Dr Pheiroijam Robindro  
Consultant, Orthopaedics Surgeon  
Imphal Hospital and Research Centre  
Imphal, Manipur, India

<sup>2</sup>Dr Narayanan Vijaykumar Latchumi  
Assistant Professor, Orthopaedics  
Saveetha Medical College  
Chennai, India

<sup>3</sup>Dr Kanthimathi BD  
Professor, Orthopaedics  
Rajah Muthiah Medical college  
Chidambaram, Tamilnadu, India

Received: 18-08-2015

Revised: 20-10-2015

Accepted: 30-10-2015

Correspondence to:

Dr Robindro Pheiroijam  
+917308626488  
msdokter@gmail.com

### ABSTRACT

**Background:** Arthroscopic anterior cruciate reconstruction has become one of the most successful surgical techniques in sports medicine however initial secure graft fixation is essential for the success of any ACL reconstruction.

**Objective:** The study was done to evaluate the functional outcome of arthroscopic ACL reconstruction using hamstring graft fixed with endobutton for femur and interference screw and suture post for tibial fixation.

**Material and methods:** From 2009 to 2013, 30 patients underwent ACL reconstruction using hamstring graft fixed with endobutton for femur and interference screw with additional suture post for tibial fixation and the outcome was observed using IKDC knee score 2000.

**Results:** The mean IKDC knee score at the follow up, 24 patients out of 30 patients had normal, 5 had nearly normal and 1 had abnormal outcome. The majority of patients had improved outcome by two grades.

**Conclusion:** In our study, endobutton for femoral tunnel and hybrid fixation combination of suture post with

interference screw provides secure fixation for ACL reconstruction with hamstring graft.

**Keywords:** Anterior cruciate ligament, hamstring graft, suture post, endobutton, arthroscopy

### Introduction

Anterior cruciate ligament (ACL) injuries are common among athletes and occur primarily in individuals involved in sports with knee pivoting movements such as soccer, floor ball, team handball, basketball and alpine skiing.<sup>[1]</sup>

Reconstruction of ACL allows the patient to return to pre trauma activity level and delays the occurrence of associated meniscal injury and onset of degenerative changes of the tibiofemoral joint.<sup>[2]</sup>

Reconstruction is also essential to restore the stability of the knee.<sup>[3]</sup> The methods of ACL reconstruction

includes open ACL reconstruction and arthroscopic ACL reconstruction. Arthroscopic ACL reconstruction has become the "Gold Standard" of care for ACL insufficiency in active patients where there is marked reduction in postoperative morbidity. It enables early vigorous physiotherapy as compare to open arthrotomy which needs excessive soft tissue dissection leading to complications such as postoperative pain, high rate of infection, post surgical knee stiffness and prolong rehabilitation.

For decades, the patellar tendon was the most common autograft for ACL reconstruction. This

technique renders good, reproducible results, which has advantage of bone-to-bone healing. The potential morbidity like patellofemoral pain, loss of motion and patellar fracture in patellar tendon graft has promoted the use of hamstring tendon graft as alternative graft source for ACL reconstruction. [4,5]

The quadruple hamstring tendon graft has excellent material strength, minimal impact on the knee extensor mechanism and excellent postoperative outcomes. [6,7,8] The graft fixation choices varies from cross pin, bioabsorbable screws, endobutton for femoral end and suture post, interference screw, etc for tibial end which plays an important role.

Successful ACL reconstruction can be achieved with rigid fixation of a strong graft. The endobutton was developed to allow secure fixation of hamstring graft to the cortical bone of the lateral femoral metaphysis. For the tibial tunnel because of the osteoporotic nature of the proximal tibia single fixation device appears less adequate. This study was to determine whether endobutton in femur and in tibia interference screw with additional suture post provides secure fixation.

### **Materials and Methods**

30 patients undergone arthroscopic assisted ACL reconstruction using quadruple hamstring tendon autograft with endobutton for femur and interference screw with suture post for tibia at the Department of Orthopaedics, Rajah Muthiah Medical College, Chidambaram, between the period of 2009 to 2013 were included in the study. The age groups of the patients were between 18 to 55 years

of age. All the patients were evaluated for history of instability, sense of knee giving way and positive Lachman's test with soft end point was the criteria based on which the patients were taken for surgery. Regional anesthesia, tourniquet control and leg positioning in a leg holder were followed for all the patients. After a diagnostic arthroscopy and confirmation of ACL tear, the associated lesions were dealt at first. Partial meniscectomy or trimming of unstable segments for meniscal tears and shaving for chondral lesions were performed. The hamstring tendons (semitendinosus and gracilis) were harvested and each end of both tendons was sutured with 1 vicryl to achieve a criss crossing pattern. The midpoint of both tendons was then looped to endobutton to make a quadruple construct. Then the graft is sized and tensioned in the graft master board (15 pounds). The tibial tunnel was made using zig, entry point at 3.5cm from joint line and angled at 45°. Required size tunnel was made on the tibial side using a cannulated reamer. Then with knee in 90° flexion, guide pin was passed using femoral aimer with 2mm offset. The standard 10-11 clock position for right knee and 1-2 clock position for left knee were followed. The Transtibial femoral tunneling was made. The femoral tunnel was over drilled using a 4.5mm cannulated drill bit for the passing of endobutton. The outer holes in the endobutton were loaded with 1 vicryl and 1 prolene. Now with knee in 90 degrees flexion, passing pin was placed through the tibial and femoral tunnels and brought out at the anterolateral thigh. Vicryl was pulled first till the graft was positioned in the femoral tunnel and now the prolene suture toggled to flip the endobutton.

The graft was pulled out distally to check for secure fixation of endobutton. The tibial fixation was done using the suture post (4.5mm cortical screw with washer) approximately 1 cm distal to tibial tunnel with knee in extension. The matched sutures are secured around the fixation screw, and then the screw is tightened fully. The interference was fixed using a screw guide.

Patients were followed up at 6 weeks, 3 months, 6 months, 1 year, 1 year 6 months and 2 years. The patients were evaluated using the international knee documentation committee form. The final outcomes are documented as A, B, C, D. with 'A' being 'Normal' functional outcome and 'B' as 'Nearly Normal', 'C' being 'Abnormal' & 'D' as 'Severely Abnormal' functional outcomes.

### Results

30 cases of arthroscopic assisted ACL reconstruction using quadruple hamstring tendon autograft with endobutton for femur and interference screw with suture post for tibia were included in our study. Among those 8 patients were between 18-20 years, 17 patients were between 21-30, 2 patients were between 31-40 years, 2 patients were between 41-50 years and 1 patient was between 50-55 years. The youngest patient in the study was 18 years and the oldest patient was 55 years.

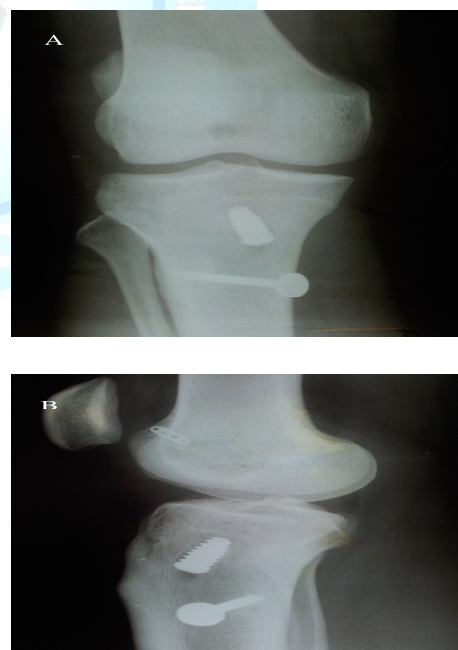
All patients at the end of the 6 months follow up were functionally evaluated based on the IKDC Score. 24 out of 30 patients had normal outcome and 5 patients had nearly normal outcome and 1 patient had abnormal outcome. 12 patients had improved by one grade and 18

patients had improved by two grades. All the patients in the normal outcome had no symptoms post operatively and had a full range of motion and ligament examination was also normal. One patient with abnormal outcome had loss of range of motion of 40%. (Table: 1)

**Table 1: International Knee Documentation Committee Scores**

Score	Pre operative	2years post operative
A	0	24
B	7	5
C	21	1
D	2	0

A- Normal, B- Nearly normal, C- Abnormal, D- Severely Abnormal



**Fig.1 X ray at 2 years follow up with (A) AP view and (B) lateral view and ACL reconstruction using hamstring graft fixed with femoral endobutton and tibial interference screw and suture post**

## **DISCUSSION**

Development in arthroscopic techniques and improvement in technology and research have allowed anterior cruciate reconstruction to become one of the most successful surgical techniques in sports medicine.<sup>[9]</sup> With advances in accelerated postoperative rehabilitation programs and initial strengths of four-stranded hamstring graft is greater than the native anterior cruciate ligament, the weak link in the graft construct is the fixation devices, especially on the tibial side.<sup>[10]</sup> Initial secure graft fixation is essential for the success of any ACL reconstruction. Attainment of rigid graft fixation minimizes or prevents failure or elongation during cyclic loading at the graft fixation sites prior to biologic incorporation.<sup>[11]</sup> In our study we have found that tibial graft fixation with interference screw and additional suture post with 4.5mm cortical screw and washer gives rigid fixation.

Noyes et al. hypothesized that ACL can load approximately 454 N (100 pound) for most activities.<sup>[12]</sup> The load of the ACL graft however can be even greater when the graft is overtensioned.<sup>[13]</sup> The result of our study shows ACL rupture treated with quadruple hamstring tendon autograft is equal to that of original ACL by clinical evaluation and functional assessment. Marder et al. utilized a two bundle semitendinosus construct and femoral endobutton in sixty two patients reported improved anterior stability.<sup>[14]</sup> Nabelung et al reviewed the result of twenty nine anterior cruciate ligament reconstructions with hamstring graft and endobutton. They graded 66% of the result as normal and near normal using the criteria of the International Knee Documentation

Committee.<sup>[15]</sup> Chae-Gwan et al. shown that endobutton femoral fixation showed good results that were comparable to those of cross pins fixation in hamstring ACL reconstruction.<sup>[16]</sup> We used endobutton for femoral graft fixation in all the patients which showed normal to nearly normal outcome. Carbon et al. suggested that interference screw fixation of hamstring tendon in ACL reconstruction is better when rounded threaded biodegradable interference screw rather than round threaded titanium screw.<sup>[17]</sup> Johnson LL et al has compared both bioabsorbable versus titanium interference screws with hamstring tendon graft in ACL reconstruction and concluded that there were no differences in clinical outcome at any stage of follow up to 2 years.<sup>[18]</sup> In our study titanium blunt threaded interference screw was used in all the patients.

ACL reconstruction when performed with technical precision has become a reliable reproducible surgical technique with a predictable outcome. Successful results can be achieved via anatomic reconstruction with rigid fixation of a strong graft. Quadruple hamstring autograft is a proven choice today. However the fixation techniques continue to evolve. Often the choice of fixation depends on the surgeon preference and his or her experience with the fixation device. In our study endobutton seem to be the better device for fixation of hamstring graft at the femoral tunnel with least complication and minimum instrumentation. For the tibial tunnel because of the osteoporotic nature of the proximal tibia single fixation device appears less adequate. With the available material in our study a



hybrid fixation combination of suture post with interference screw provides best fixation choose for hamstring graft at the tibial tunnel.

### References

1. Meighan AA, Keating JF, Will E. Outcome after reconstruction of the anterior cruciate ligament in athletic patients. A comparison of early versus delayed surgery. *Bone Joint Surg Br* 2003;85:521-4.
2. Satku K, Kumar VP, Ngoi SS. ACL injuries. To counsel or to operate? *J Bone Joint Surg Br* 1986;68:458-61.
3. Howe, Johnson, Kaplan. ACL reconstruction using Quadriceps patellar tendon graft. Part I. Long term follow up. *Am J of Sports Med* 1991;19:447-57.
4. Michael Wagner, Max J. Hamstring tendon versus patellar tendon anterior cruciate ligament reconstruction using biodegradable interference fit fixation. *Am J Sports Med* 2005;33(9):1327-1336.
5. Brier SJ, Warren RF, Pavlov H, Panareillo R. Reconstruction of the chronically insufficient anterior cruciate ligament with the central third of the patellar ligament. *J Bone Joint Surg Am* 1991;73:278-86.
6. Williams RJ, Hyman J Anterior cruciate ligament reconstruction with a four-strand hamstring tendon autograft. *J Bone Joint Surg* 2004; 86A(2):225-32.
7. Holm I, Risberg MA, Jensen HK, Steen H. Four strand hamstring tendon autograft compared with patellar tendon bone autograft for anterior cruciate ligament reconstruction. A randomized study with two year follow up. *Am J of Sports Med* 2001;29:722-8.
8. D Amato ML, Nedeff DD, Kaz A, Bach BR Jr. Arthroscopic anterior cruciate ligament reconstruction: a meta analysis comparing patellar tendon and hamstring tendon autografts. *Am J Sports Med* 2003;31:2-11.
9. Frank CB, Jackson DW. Current concepts review. The science of reconstruction of the anterior cruciate ligament. *Bone Joint Surg Am* 1997;79:1556-76.
10. Riley W, Jon H, Frank P, Tamara R. Anterior cruciate ligament reconstruction with a four strand hamstring tendon autograft. *Bone Joint Surg* 2004;86:225-232.
11. Anderson AA, Federspiel CF, Snyder RB. Evaluation of knee ligament rating systems. *Am J Knee Surg* 1993;6:67-73.
12. Noyes FR, Butler DL, Grood ES, Zernicke RF, Hefzy MS Biomechanical analysis of human ligament grafts used in knee ligament repairs and reconstructions. *Bone Joint Surg AM* 1984;66A(3):344-52.
13. Markolf KL, Slauterbeck JR, Armstrong KL, Shapiro MS. Force in the graft compared with force in the intact ligament. *J Bone Joint Surg* 1996;78A:1728-34.
14. Marder RA, Raskind JR, Carroll M. Prospective evaluation of arthroscopically assisted anterior cruciate ligament reconstruction, Patellar tendon versus semitendinosus and gracilis tendons. *Am J Sports Med* 1991;9:478-84.
15. Nebelung VV, Becker R, Merkel M, Ropke M. Bone tunnel enlargement after anterior cruciate ligament reconstruction with semitendinosus tendon using

- endobutton fixation on the femoral side. Arthroscopy 1998;14:810-5.
16. Chae-Gwan kong, Yong In. Cross Pins versus Endobutton Femoral Fixation in hamstring Anterior Cruciate Ligament Reconstruction: Minimum 4-Year Follow-Up. Knee Surg Relat Res 2012 Mar;24(1): 34–39.
17. Cardon DNM Coen M, Neef R, Hamilton D, Nyland J, Johnson DL. Quadruples semitendinosus gracilis autograft fixation in the femoral tunnel; comparison between a metal and bioabsorbable interference screw. Arthroscopy 1998;14:241-5.
18. Johnson LL, VanDyk GE. Metal and biodegradable interference screws; comparison of failure strength. Arthroscopy 1996; 12:452-6.

Cite this article as: Robindro P, Latchumi NVK, Kanthimathi BD. To study the functional outcome of arthroscopic ACL reconstruction using hamstring graft fixed with endobutton for femur and interference screw and suture post for tibial fixation. Int J Med and Dent Sci 2016; 5(1):978-983.

Source of Support: Nil  
Conflict of Interest: No

