

Case Report**An indirect sinus lift with ridge splitting procedure for implant placement: A case report**Shetty M¹, Thulasidas N², Hegde R³, Hegde C⁴

¹Dr Manoj Shetty
Professor, MDS
drmanojshetty@gmail.com

²Dr Nikhila Thulasidas
PG Student
nikhilathulasidas@yahoo.in

³Dr Rakshith Hegde
Professor, MDS
prosthodonts@yahoo.co.in

⁴Dr Chethan Hegde
Professor, MDS
hegdechethan@yahoo.co.in

^{1,2,3,4}Department of Prosthodontics
AB Shetty Memorial Institute of Dental
Sciences
Deralakatte, Mangalore-575018, India
Received: 30-10-2015
Revised: 10-10-2015
Accepted: 18-11-2015

Correspondence to:

Dr Nikhila Thulasidas
nikhilathulasidas@yahoo.in
09742024347

ABSTRACT

Implant placement becomes complicated when the height and width of the bone is compromised especially in the posterior maxillary region due to the presence of sinus. This case report presents the rehabilitation of the left maxillary premolar region by using indirect sinus lift and ridge splitting followed by immediate implant placement where the bone height and bone width was compromised. It helps in reducing the treatment time and increases the patient comfort.

Key words: Indirect sinus lift, ridge splitting, immediate implant placement

Introduction

An adequate bone quality and quantity are essential for a successful implant therapy.^[1] A common problem encountered while placing implant fixtures in the posterior maxilla region is the lack of bone required for successful implant therapy. Edentulous posterior maxillary region often presents challenge to implant placement due to ridge resorption and sinus pneumatization. Sinus pneumatization, which typically occurs with ageing, often minimizes or completely eliminates the vertical bone available for endosteal implant placement. Sinus lift procedures are the treatment of choice when such anatomic defects occur. The most widely used approaches for sinus lifting are: direct sinus lifting approach and indirect sinus

lifting approach. The indirect sinus lift procedure presents the advantage of being less invasive and less time consuming compared to direct sinus lift. This case report presents the rehabilitation of the maxillary left premolar region with reduced bone height and width using indirect sinus lift procedure and ridge splitting without grafting and immediate implant placement which helped in the reducing the healing time and waiting time for the patient.

Case Report

A male patient aged 28 years old reported to the Department of Implantology, with multiple missing teeth. A thorough clinical examination was done followed by the

radiographic examination using OPG. (Fig. 1)

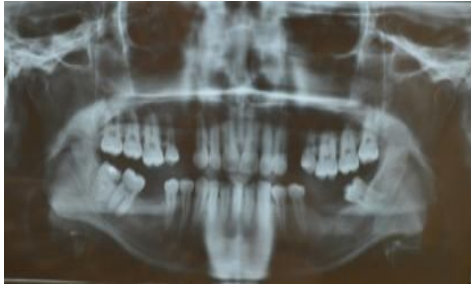

Fig. 1 Preoperative OPG

On evaluation it was found that the left premolar region had only 7 mm bone and an indirect sinus lift procedure with immediate implant placement was planned. The rest of the areas had adequate bone height. Blood examination was performed and antibiotic prophylaxis was given 1 day prior to the surgery.

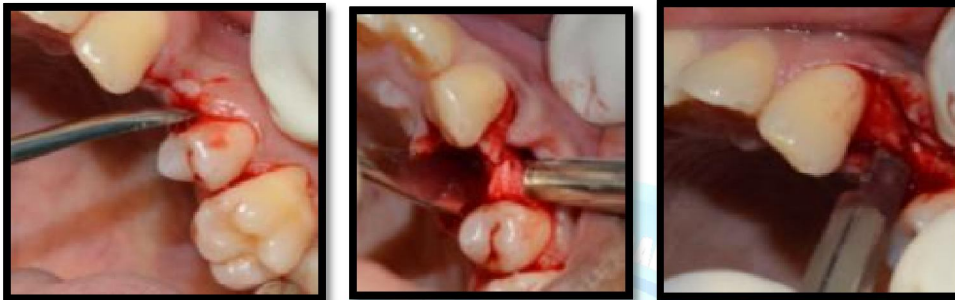

Fig. 2 Incision and reflection of the flap followed by ridge splitting

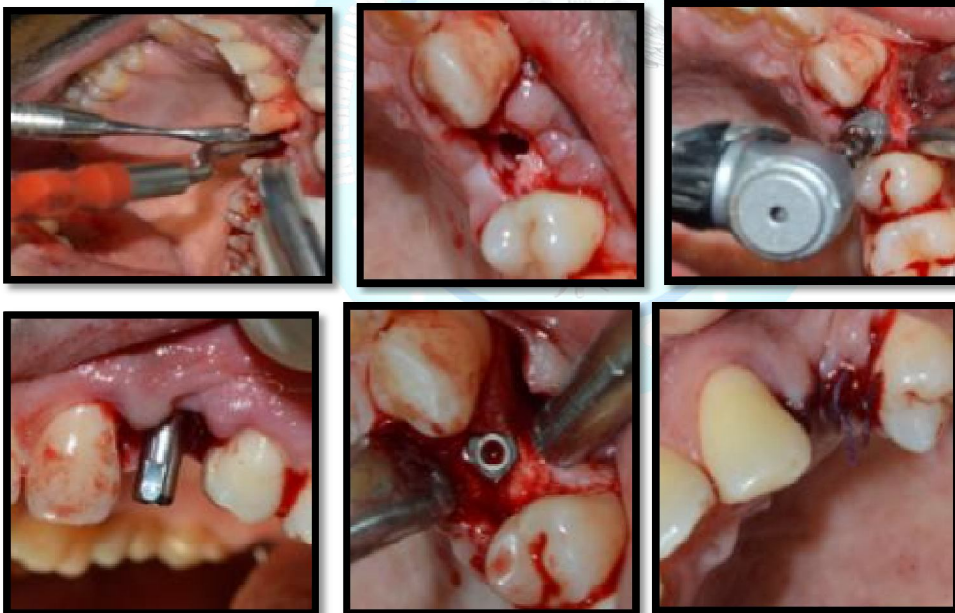


Fig. 3 Indirect sinus lift using osteotomes followed by placement of Ankylos CX A- 9.5 implant and suturing

Surgical phase:

- Local anaesthesia was given and crestal incision was made using no 15 BP blade.
- Flap was reflected and it was found that the bone width was less.
- Hence ridge splitting was done using a BP blade and mallet and bone expansion was done. (Fig. 2)
- Initial depth was achieved using a 2mm pilot drill at a speed of 850 RPM with saline irrigation. After that 3.2mm twist

- drill at a speed of 850 RPM with saline irrigation was used
- Indirect sinus lifting was done using sinus elevation instruments.
- After final osteotomy, Ankylos CX A-9.5 Implant motor driven at 20 rpm and 50 Ncm torque
- Cover screw was placed and suturing was done using multifilament 3-0 resorbable vicryl sutures. (Fig. 3)
- IOPA was taken and antibiotic prophylaxis was given. IOPA was taken after 4 months to assess the bone (Fig. 4)

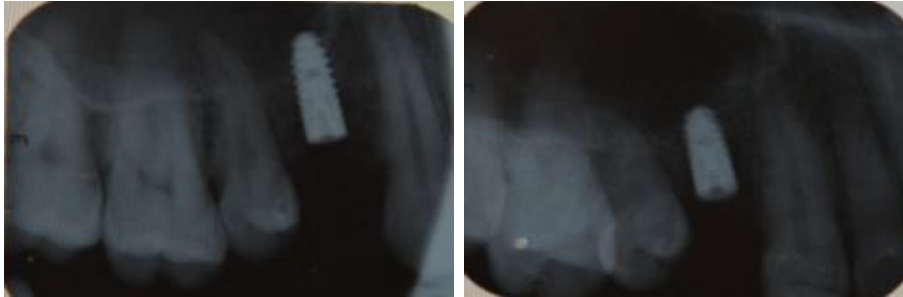

Fig. 4 IOPA after implant placement and after 4 months

- Prosthetic phase (Fig. 5)
- Sulcus formers were placed after 4 months
 - Well formed sulcus was obtained after one week and a closed tray impression was made with repositioning post.
 - Abutment was torque at 15 Ncm and a PFM crown fabricated in physiologic occlusion was cemented using zinc phosphate cement.
 - Patient was instructed to maintain the oral hygiene by means of dental floss and mouth wash. Also patient was recalled after 1 week and 3 months.

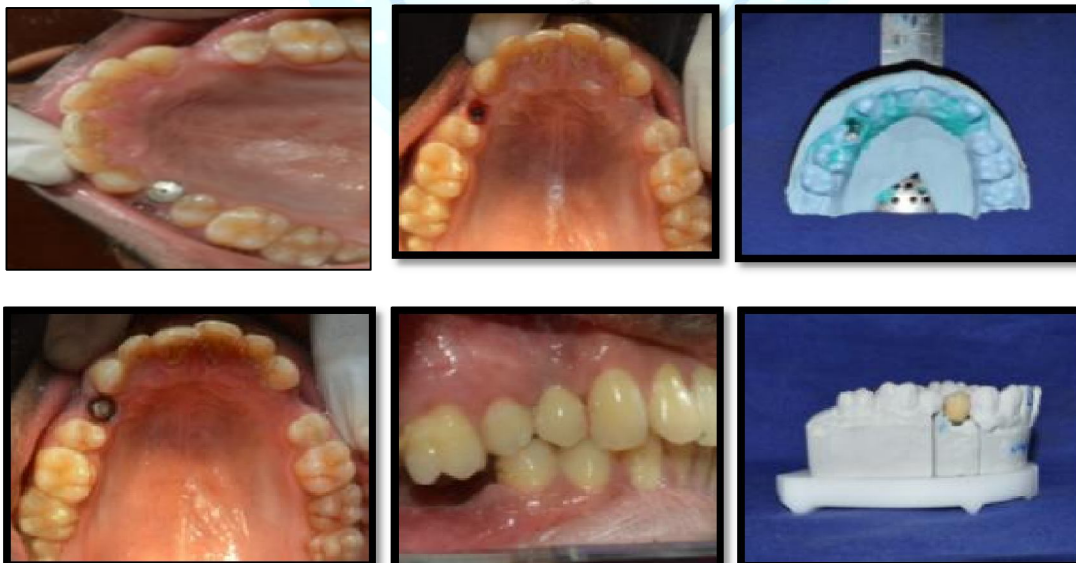


Fig. 5 Prosthetic phase involving placement of sulcus former followed by torquing of abutment and implant crown cementation in physiologic occlusion.

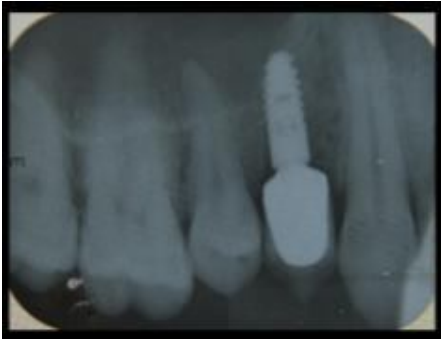

Fig.6 IOPA after crown cementation

Discussion

With the advancement in dentistry, implant placement has become the most preferred means of replacement of missing teeth. But in most cases posterior maxilla presents a problem because the maxillary sinus. In such cases it is necessary to elevate the sinus floor and increase the bone height before implant placement. The most commonly used techniques are the direct sinus lift and indirect sinus lift. In direct technique the sinus is approached through the lateral window technique most of the time whereas indirect technique follows a crestal approach.

In this article the indirect sinus lifting approach using sinus elevation instruments has been followed for increasing the bone height and the bone width was increased using ridge splitting. The present case showed a bone height of 7 mm radiographically and the sinus floor was elevated upto 2.5 mm for the placement of Ankylos Cx implant of 9.5 mm length and 3.5 mm diameter. According to the study conducted by Ahn et al the mean height of the residual alveolar process was 5.8 (0.9)mm, whereas mean elevation of the sinus floor was 6.2 (0.4) mm using indirect sinus lift. The study by Fornell et al ^[2] showed a mean bone gain of 3 mm without any marginal bone loss after 3-12 months which was similar to the present case report.

This technique has the advantage of being less invasive and less complex compared to the direct sinus lift procedure. Immediate implant placement with the indirect sinus lift reduces the healing time and waiting time for the patients which is an important factor in the present fast moving world. The bone was formed around the implant in 4 months and could be loaded. The disadvantage of this technique is that it is a blind procedure and only 2-3 mm of sinus elevation can be achieved.

Conclusion

Though the placement of implants can be difficult at times due to compromised situations, by good evaluation and utilising the various techniques available it is possible to provide a good treatment outcome. The indirect sinus lift procedure and ridge splitting along with immediate implant placement helps to reduce the treatment time in patients. Hence even by keeping the treatment procedure simple a successful rehabilitation can be achieved.

References

1. Agnihotri A, Agnihotri D. Maxillary sinus lift up: An indirect approach of implant placement in posterior maxilla. *Int J Oral Implant Clin Res* 2012;3(2):102-104.
2. Ahn S-H, Park E-J, Kim E-S. Reamer-mediated transalveolar sinus floor elevation without osteotome and simultaneous implant placement in the maxillary molar area: clinical outcomes of 391 implants in 380 patients. *Clin Oral Impl Res* 2012;23:866-872.
3. Fornell J, Johansson L-A, Bolin A, Isaksson S, Sennerby L. Flapless, CBCT-guided osteotome sinus floor elevation with simultaneous implant installation. I: radiographic examination and surgical technique. A prospective 1-year follow-up. *Clin Oral Impl Res* 2012;23:28-34.

4. Leblebicioglu B, Ersanli S, Karabuda C, Tosun T, Gokdeniz H. Radiographic evaluation of dental implants placed using an osteotome technique. *Journal of Periodontology* 2005;76: 385–390.
5. Listl S, Faggion CM. An economic evaluation of different sinus lift techniques. *Journal of Clinical Periodontology* 2010;37:777–787.
6. Pjetursson BE, Ignjatovic D, Matuliene G, Bragger U, Schmidlin K, Lang NP. Transalveolar maxillary sinus floor elevation using osteotomes with or without grafting material. Part II: radiographic tissue remodeling. *Clinical Oral Implants Research* 2009a;20:677–683.
7. Pjetursson BE, Rast C, Bragger U, Schmidlin K, Zwahlen M, Lang NP. Maxillary sinus floor elevation using the (transalveolar) osteotome technique with or without grafting material. Part I: implant survival and patients' perception. *Clinical Oral Implants Research* 2009b;20: 667–676.
8. Thomas GT. Sinus Lifts. A possible solution to the atrophic maxilla. *J Macomb Dent* 1990;29:9.
9. Toffler M. Osteotome-mediated sinus floor elevation: a clinical report. *The International Journal of Oral & Maxillofacial Implants* 2004;19:266–273.
10. Summers RB. A new concept in maxillary implant surgery: the osteotome technique. *Compendium* 1994a;15:152–158.
11. Summers RB. The osteotome technique: part 3—Less invasive methods of elevating the sinus floor. *Compendium of Continuing Education in Dentistry* 1994b;15:422–426.

Cite this article as: Shetty M, Thulasidas N, Hegde R, Hegde C. An indirect sinus lift with ridge splitting procedure for implant placement: A case report. *Int J Med and Dent Sci* 2016; 5(1):1088-1092.

Source of Support: Nil

Conflict of Interest: No