

## A multidisciplinary approach for ocular rehabilitation following ophthalmomalacia in a paediatric patient

Aggarwal H<sup>1</sup>, Jurel S<sup>2</sup>, Kumar P<sup>3</sup>, Singh RD<sup>4</sup>, Alvi HA<sup>5</sup>

<sup>1</sup>Himanshi Aggarwal  
MDS, Junior Resident  
<sup>2</sup>Sunit Jurel  
MDS, Assistant Professor  
<sup>3</sup>Pradeep Kumar  
MDS, Senior Resident  
<sup>4</sup>Raghuwar D Singh  
MDS, Assistant Professor  
<sup>5</sup>H.A. Alvi  
MDS, Professor and head  
<sup>1,2,3,4,5</sup>Department of Prosthodontics  
King George Medical University  
Lucknow, Uttar Pradesh, India

Received: 02-06-2012  
Revised: 10-06-2012  
Accepted: 20-06-2012

Correspondence to:  
Dr. Sunit Kumar Jurel  
09453604322  
dentistmj1110@yahoo.co  
.in

### ABSTRACT

The traumatic loss of an eye is not just the loss of an essential sense organ. It results in life-long agony of not being like others with two eyes, which can see and admire the nature's beauty. As young patients are quite sensitive to peer pressure and for them, the greatest challenges are in the terms of identity and social acceptance, so, early rehabilitation is must in such patients. This article reports on the rehabilitation of a 13-year boy with custom ocular prosthesis for his traumatically injured left eye. The custom made ocular prosthesis fitted over the patient's left eye with ophthalmomalacia, successfully restored the patient's aesthetics and improved his social acceptance thereby, improving his quality of life.

**Key Words:** Custom ocular prosthesis, prosthesis replacement, ocular trauma

### Introduction

The loss of an eye due to congenital defect or an acquired defect such as trauma, tumor, painful blind eye etc <sup>[1]</sup>, apart from causing aesthetic disfigurement of face, also significantly affects the individual physical <sup>[2]</sup>, psychological, emotional and social well being. Majority of patients experience extreme stress due to functional disability and non-acceptance in the society, thereby deteriorating the patient's quality of life.

The pitiable condition of such a patient who is sans eyes is beyond imagination. The patient is not only devoid of a very essential sense organ, but he loses

his ability to admire the nature's beauty. At the same time, he loses the beauty and the charm of his face, as eyes are generally the first facial feature to be noticed <sup>[3]</sup> and most of the times, when we meet other people, eyes speak earlier than the words.

As young patients are quite sensitive to peer pressure and for them, the greatest challenges are in the terms of identity and social acceptance, so, early rehabilitation is must in such patients, to promote the physical, psychological and emotional healing for the patient and to improve his social life. Rehabilitating such patients requires a multidisciplinary approach <sup>[4]</sup>

involving the combined and timely efforts of an ophthalmologist, psychologist and a skilled maxillofacial prosthodontist.

Ocular prosthesis can be stock prosthesis, or it can be customized according to the patient's socket tissue bed and individualized aesthetic requirements.

### Case Report

A 13-year male patient reported to the department of prosthodontics with the complaint of loss of vision and discolouration of his left eye (Fig. 1).

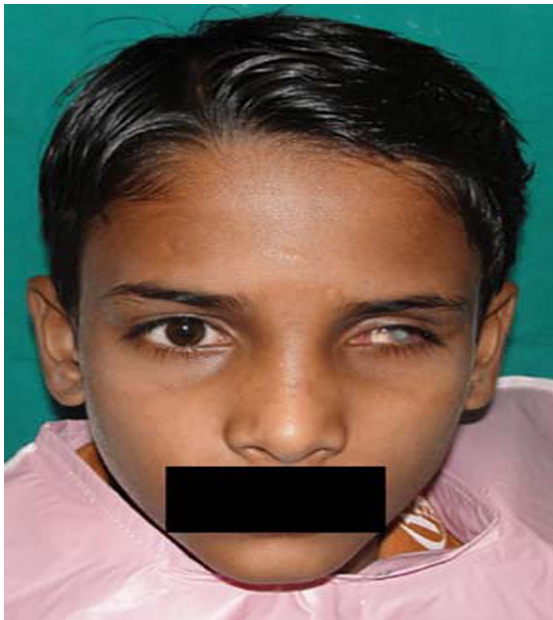

Fig.1 Pre-operative photograph showing defect of left eye

Examination revealed complete loss of vision in the left eye with disfigured and shrunken ocular tissues. Patient gave history of trauma with pencil two years back, but he didn't inform his parents about the injury. When he gradually started losing his eyesight, he informed his parents, but it was too late since the damaging effects of trauma had already commenced to an advanced stage.

After careful anamnesis, it was found that the patient was under psychological distress as his friends used to tease him about his facial appearance. So, before commencing with the treatment, ophthalmological and psychological consultations were taken.

The ophthalmologist confirmed it to be a case of ophthalmomalacia or phthisis bulbi, which is characterized by atrophy, shrinkage, anatomical disfigurement and disorganization of the globe. [5] The psychologist's counselling allayed the patient's anxiety and fears and helped in inculcating optimism in the patient.

After careful examination of the defect area, it was planned to fabricate custom ocular prosthesis for the patient. Whole procedure was explained to the patient/guardian to gain his co-operation. The procedure was initiated by selecting and modifying a stock eye, whose iris and pupil closely matched to patient's normal eye, to comfortably and loosely fit the socket. This was duplicated with clear-heat cured PMMA (Trevalon, Dentsply India Pvt. Ltd., Gurgaon, India) and perforated to be used as tray for the impression procedure. Perforation of the tray was done to avoid any compression of the ocular tissues. The tray was placed in the socket and the patient was asked to gaze at a distant point to accurately mark the pupil as per contralateral side, on the tray.

A thin mix of ophthalmic alginate (Ophthalmicmoldite, Milton Roy Co. Sarasota Fla.) was loaded in the tray and injected in the socket. The patient was asked to perform eye movements in all directions to allow the alginate to flow into defect areas. Impression (Fig. 2A) was examined for accuracy and the cast (Fig. 2B) was poured in two parts.

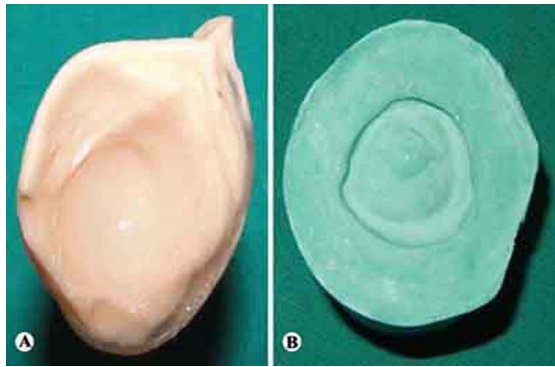


Fig. 2A Impression of the ocular defect  
2B Cast obtained after double-pour technique

The second part was poured after applying lubricant and making orientation grooves on the partially set first half. The tray handle was maintained as a sprue to pour the wax pattern and to transfer the pupillary point onto the cast.

The technique was modified here onwards by trimming the iris portion of the stock eye and orienting it on the cast according to previously transferred pupillary mark. Carving wax mixed with sticky wax was poured into cast, taking care not to displace the iris from its previously oriented position, in the wax pattern. This iris-wax pattern combination was placed in socket (Fig. 3) and modified for adequacy of ocular movements, correction of pupillary alignment, proper palpebral movements, scleral contour and convexity.



Fig.3 Final wax pattern try-in

The next step was to reproduce scleral shade of the normal eye. Shade tabs were prepared by mixing and matching different shades and proportions of tooth-colored acrylic (SC 10, Pyrax, Roorkee, India) till the color of contralateral sclera was replicated. The wax pattern was invested, flaked and de-waxed (Fig. 4A, 4B).

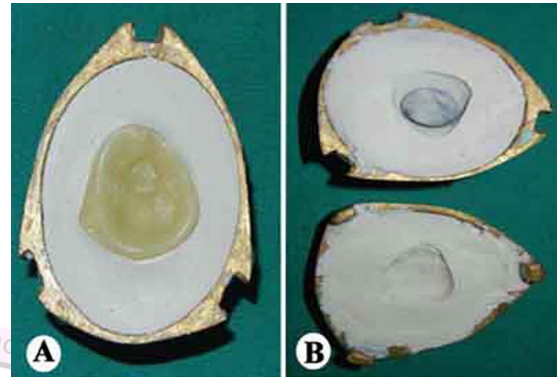


Fig. 4A Invested wax pattern  
4B Dewaxed mould

To mimic veins present in the eye, the veins separated from the veined acrylic material (Trevalon, Dentsply India Pvt. Ltd., Gurgaon, India), were placed in the acrylic dough followed by routine curing, finishing and polishing. Finally, thin film of the sclera was removed and replaced by a clear film of transparent heat-cured PMMA (Trevalon, Dentsply India Pvt. Ltd., Gurgaon, India) to simulate corneal translucency.

The final prosthesis was inserted in the socket (Fig. 5) after disinfection and lubrication with an ophthalmic lubricant (Ecotears, Intas Pharmaceuticals Ltd, Ahmedabad, India).

Minor adjustments were made at the time of delivery as per the patient's comfort and aesthetics. Instructions regarding proper care and hygiene maintenance were given. As the patient was in growing age and slight regression of ocular tissues takes place after insertion of prosthesis, so the patient was advised to come for regular follow ups at 1

month, 3 months, later followed by 6 monthly recall appointments, to facilitate relining of ocular prosthesis when necessary.



Fig. 5 Post-operative photograph showing prosthesis in lieu of defective eye

### Discussion

The custom made ocular prosthesis fabricated for this patient with ophthalmomalacia successfully restored the patient's aesthetics and improved his social acceptance thereby, improving his quality of life. The prosthesis demonstrated excellent fit, mobility and comfort.

As young patients are quite sensitive to peer pressure and for them, the greatest challenges are in the terms of identity and social acceptance, so, early rehabilitation is must in such patients. The rehabilitation of such patients presents a challenging clinical situation, as the patient has already been clouded by the sadness and psychological distress due to loss of vision and loss of facial aesthetics, as a result of failed ocular therapy.

Therapeutic approaches are very limited in ophthalmomalacia and usually provide only symptomatic relief in patients with mild ocular symptoms. Most of eyes

with ophthalmomalacia eventually become blind, painful, and cosmetically unacceptable for the patient.

The cosmetic rehabilitation of these patients with ocular prosthesis should be an integral part of their treatment, which fulfills aesthetic, psychological requirement of the patients and helps in their re-integration in the society.

### References

1. Beumer J III, Curtis TA, Firtell DN editors. Maxillofacial Rehabilitation: Prosthodontic and Surgical Considerations. St Louis: CV Mosby; 1979: 352–362.
2. Lubkin V, Sloan S. Enucleation and psychic trauma Adv Ophthalmic Plast Reconstr Surg. 1990; 8: 259–262.
3. Doshi PJ, Aruna B. Prosthetic Management of patient with ocular defect. J Ind Prosthodont Soc. 2005; 5: 37–38.
4. Bartlett SO, Moore DJ. Ocular prosthesis: a physiologic system. J Prosthet Dent. 1973; 29: 450–459.
5. Hogan MJ, Zimmerman LE, editors. Ophthalmic Pathology. An Atlas and Textbook. 2nd ed. Philadelphia: WB Saunders; 1962.

Cite this article as: Aggarwal H, Jurel S, Kumar P, Singh RD, Alvi HA. A multidisciplinary approach for ocular rehabilitation following ophthalmomalacia in a paediatric patient. Int J Med and Dent Sci 2012; 1(2):24-27.

Source of Support: Nil  
Conflict of Interest: No