

## ANTI-HEPATOTOXIC ACTIVITY OF *MARRUBIUM VULGARE* L. IN CARBON TETRACHLORIDE INDUCED TOXICITY

Ahmed B<sup>a\*</sup>, Masoodi MH<sup>b</sup>, and Khan S<sup>a</sup>

<sup>a</sup> Department of Pharmaceutical Chemistry, Faculty of Pharmacy, Jamia Hamdard, Hamdard Nagar, New Delhi -110 062, India

<sup>b</sup> Department of Pharmaceutical Sciences, University of Kashmir, Hazratbal, Srinagar, J & K - 190 006, India

Received on : 05.02.2008

Revised : 05.01.09

Accepted : 09.01.09

### ABSTRACT

Different extracts of whole plant of *Marrubium vulgare* L (Lamiaceae) were investigated for hepatoprotective activity against carbon tetrachloride induced hepatic damage in male Albino Wister rats. The activity of these extracts (500-mg/kg b. w for 7 days) was compared with the standard drug silymarin (Silybon-70, 10 mg/kg-b.w). The petroleum ether, chloroform and methanolic extracts have shown significant hepatoprotective activity by reducing the elevated levels of serum enzymes such as serum glutamate oxaloacetate transaminase (SGOT) by 17.69, 67.0 and 30.80%, serum glutamate pyruvate transaminase (SGPT) by 19.0, 22.30 and 39.29%, alkaline phosphatase (ALP) by 17.32, 28.99, 35.38% and increased total protein (TP) by 22.49, 31.84, and 34.29% respectively indicating that the methanol extract was the most active among the three extracts as compared to standard drug silymarin, which decreased SGOT by 53.04, SGPT by 55.96, ALKP by 35.87 and increased TP levels by 59.24% against CCl<sub>4</sub> intoxicated rats in comparison to normal control. These biochemical observations were also supplemented by histopathological examinations of the liver sections. The results showed that the methanolic extract was the most active among all the extracts.

**Key words:** *Hepatoprotective; Carbon tetrachloride; Marrubium vulgare; Silymarin.*

### INTRODUCTION

Medicinal plants belonging to different families have been used in herbal formulations as crude extracts for the treatment of various diseases of the liver. As many as 600 commercial preparations, of mainly plant crude extracts of claimed liver protecting activity are available all over the world<sup>1</sup>. Continuous exposure of liver to a variety of xenobiotics, therapeutic agents and environmental pollutants leads to various disorders such as liver cirrhosis, viral hepatitis, hepatoses and drug induced liver damage<sup>2</sup>. The drugs available in the modern medicines bring only symptomatic relief in the most of the cases, and are associated with risks of relapses and danger of side effects. On the contrary, medicines derived from plants are comparatively safer with fewer side effects. Thus, a concerted effort to explore the plant resources is extremely important in search of new remedies.

In continuation of the work on investigation of medicinal plants, we have selected *Marrubium vulgare* L. (Lamiaceae), which is commonly known as 'horehound' is a perennial herb about 1 foot high, branched below, bluntly quadrangular, more densely covered, especially when young, with a thick white cottony felt. The plant grows in waste ground throughout Europe, the Mediterranean district and Western Asia as far as India especially in Kashmir region. It possesses tonic,

aromatic, stimulant, expectorant, diaphoretic and diuretic activity. It is also laxative in large doses, and was formerly regarded as emmenagogue. It has also been used in hepatic disorders<sup>3</sup>. Hypoglycemic effect<sup>4</sup>, hypotensive activity<sup>5</sup> and antinociceptive properties are some of its reported biological activities<sup>6</sup>.

### EXPERIMENTAL

#### PLANT MATERIAL

The whole plant of *Marrubium vulgare* L. was collected in the month of August 2005 from Nawhatta, Srinagar (J&K) and authenticated by taxonomist Prof. A. R. Naqshi (Dept. of Botany, University of Kashmir, Srinagar, India). The voucher specimen (MV-FP-18) of the plant has been kept in the herbarium of Jamia Hamdard for future reference.

#### PREPARATION OF PLANT EXTRACT

The plant material (5.0 kg) was dried in shade and crushed to coarse powder and then successively extracted with petroleum ether (60-80), CHCl<sub>3</sub> and methanol using cold percolation (Borosil glass of 10 liters capacity made by Perfit India). The plant material was kept under percolation for about 2-3 days, and repeated several times until completely exhausted. The different extracts were concentrated under reduced pressure to get the crude viscous masses of petroleum

\*Correspondence : drbahmed@rediffmail.com, baharchem@yahoo.com Ph. (+91-11) - 26059688, extn. 5623

ether (65.0 g), chloroform (90.0 g) and methanol (180.0 g) fractions.

**EXPERIMENTAL ANIMALS**

Male Wistar rats weighing 150–200 g were employed for assessing the anti-hepatotoxic activity, which were procured from the Central Animal House of Jamia Hamdard, New Delhi (173/CPCSEA), after approval under the project proposal number-228. They were fed with a standard pellet diet and water *ad libitum*. The animals were maintained at 25 °C to 28 °C with 40-70% RH and 12 h light/dark cycles and were fastened for 12 h prior to the experiment.

**ANTIHEPATOTOXIC ACTIVITY**

The animals were divided into six groups consisting of 5 rats each. The first group-I served as normal control, which received normal saline only. The second group-II served as toxic control and received only carbon tetrachloride diluted with liquid paraffin in a ratio of (1:1) (0.7 ml/kg b.w, i.p) on the first day to produce toxicity in the liver<sup>7, 8</sup>. The third group-III was given a single dose of CCl<sub>4</sub> on the first day (0.7 ml/kg b.w, i.p) and then silymarin (Silybon-70, 10 mg/kg b.w, p.o) for 7 days. Groups-IV to VI received a single dose of CCl<sub>4</sub> on the first day (0.7 ml/kg b.w, i.p) and then petroleum ether, chloroform and methanolic extracts respectively at the dose of (500 mg/kg b.w, p.o) for 7 days<sup>9,10</sup>. On the day 8 the blood samples were withdrawn by puncturing the orbital plexus and the rats were sacrificed by decapitation. The blood samples were allowed to clot for 30-40 min at room temperature. Serum was separated by centrifugation at 2500 rpm for 15 min and various biochemical parameters like SGOT, SGPT<sup>11</sup>, ALKP<sup>12</sup> and TP<sup>13</sup> were studied by reported methods.

**STATISTICAL ANALYSIS**

The data of biochemical estimations were reported as ± S.E, where n = 5. The statistical significance was determined by one way analysis of variance (ANOVA) and Dunnett's test. P-values of less than 0.05 were considered significant<sup>14</sup>.

**HISTOPATHOLOGICAL STUDIES**

For histopathological study, the livers after autopsy and The rats were sacrificed and the livers were quickly removed then washed with normal saline and fixed in 10% formalin solution<sup>15</sup>. Small pieces of tissues were embedded in paraffin wax. The sections of about 5-6 μm were cut, stained and then observed under microscope for histopathological changes in liver and then consequently their pictographs were taken.

**RESULTS AND DISCUSSION**

Table I shows that the animals of group-II, which received only CCl<sub>4</sub> were found to develop significant hepatic damage as was observed from elevated levels of SGOT, SGPT and ALP and decrease in TP levels as compared to group-I normal animals. The treatment

**Table 1: Effect of various extracts of *Marrubium vulgare* (whole plant) on serum enzymatic activity in CCl<sub>4</sub> induced live damage in rats.**

Groups (n=5)	Treatment	Dose	SGOT Units/ml	SGPT Units/ml	ALKP Units/ml	TP Gm/dl
I	Normal (control)	—	36.47 ± 1.46	25.52 ± 0.70	27.58 ± 0.56	7.38 ± 0.16
II	Toxic (control)	1 mg/kg (s.c.)	119.19 ± 4.05	94.70 ± 4.03	55.08 ± 2.39	4.49 ± 0.16
III	Silymarin (standard drug)	10 mg/kg (p.o.)	65.97 ± 1.61**	41.70 ± 2.90**	35.32 ± 1.03**	7.15 ± 0.12**
IV	CCl <sub>4</sub> /Petroleum ether extract	500 mg/kg (p.o.)	98.10 ± 3.97**	76.46 ± 2.39**	45.54 ± 2.48**	5.50 ± 0.32*
V	CCl <sub>4</sub> /Chloroform extract	500 mg/kg (p.o.)	111.21 ± 3.23**	73.97 ± 3.02**	39.88 ± 2.73	5.92 ± 0.34**
VI	CCl <sub>4</sub> /Methanol extract	500 mg/kg (p.o.)	82.44 ± 3.92**	57.46 ± 3.37**	35.59 ± 2.34**	8.03 ± 0.28**

\*SGOT= Serum glutamyl oxaloacetate transaminase; SGPT= Serum glutamate pyruvate transaminase; ALKP= Alkaline phosphatase; TP, Total protein; s. c. = subcutaneous; p. o. = per oral.

\*\* P < 0.01; \*P < 0.05 vs CCl<sub>4</sub>; P > 0.05 ns.

Values are mean ± S.E. of five animals. One way analysis and Dunnett's test.

with petroleum ether, chloroform, and methanolic extracts of *Marrubium vulgare* at a dose of 500 mg/kg b.w, p.o in groups (IV), (V) and (VI) significantly prevented CCl<sub>4</sub> induced elevation of liver enzymes namely SGOT by 17.69, 67.0 and 30.80%, SGPT by 19.0, 22.30 and 39.29% and ALP by 17.32, 28.99 and 35.38% respectively. On the other hand, the TP levels were increased by 22.49, 31.84, and 34.29% respectively indicating that the methanol extract was the most active among the three extracts as compared to standard drug silymarin, which decreased SGOT by 53.04, SGPT by 55.96, ALKP by 35.87 and increased TP levels by 59.24%.

Histopathological studies also revealed that in animals of group-II, CCl<sub>4</sub> caused prominent centrilobular fatty change with prominent and enlarged central vein. There was a significant periportal inflammation. Necrosis was also observed indicating the liver damage and inflammation of the hepatocytes (Plate I). Sections of the liver treated with different plant extracts, groups (IV to VI) showed a significant recovery of hepatocytes (Plate II-IV). The methanolic extract exhibited a significant recovery of the hepatic cells with a little sinusoidal dilatation in some hepatic lobules. Central vein appeared clearly with disappearance of the necrosis thereby indicating a potent anti-hepatotoxic activity (Plate IV). The histopathological studies have also revealed that the rats treated with methanolic extract had almost normal architecture of hepatocytes indicating significant recovery as compared to the standard silymarin (Plate No. V)

The increase in the level of serum transaminase reflects the liver damage<sup>16</sup> as these enzymes are released in the blood circulation after the administration of hepatotoxin i.e. CCl<sub>4</sub><sup>17</sup>. The toxicity is initiated by formation of a reactive metabolite trichlormethyl radical <sup>•</sup>CCl<sub>3</sub> by microsomal fixed function oxidase (MFO's). The biotransformation is catalyzed by a cytochrome p-450 dependent monooxygenase<sup>18</sup>. The activated <sup>•</sup>CCl<sub>3</sub> radical binds covalently to the macromolecules and induces peroxidative degradation of membrane lipids resulting



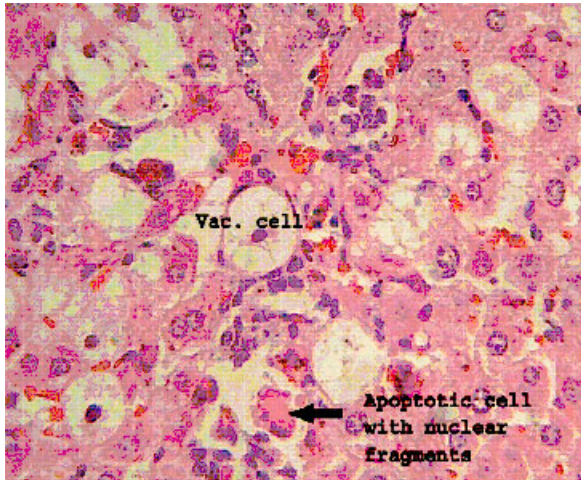

Plate No. I. High power photomicrograph of Toxic control rat liver on 8<sup>th</sup> day (HE x 40X).

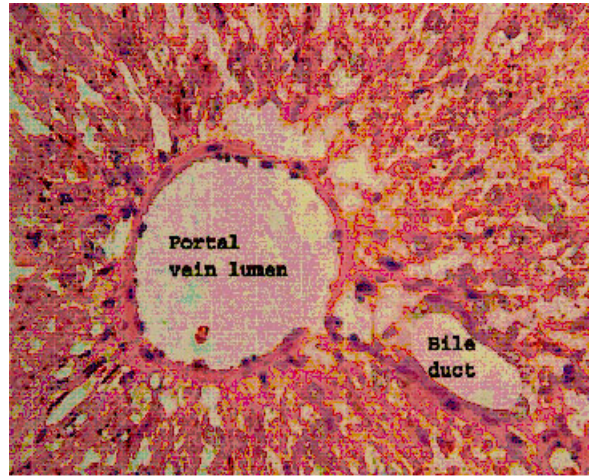


Plate No. IV. High power photomicrograph of methanol fraction on 8<sup>th</sup> day (HE x 40X).




Plate No. II. High power photomicrograph of petroleum ether fraction on 8<sup>th</sup> day (HE x 40X).




Plate No. V. High power photomicrograph of Standard silymarin on 8<sup>th</sup> day (HE x 40X).

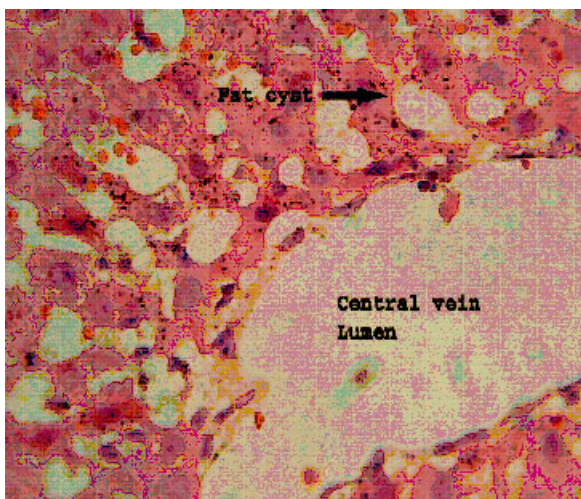


Plate No. III High power photomicrograph of chloroform fraction on 8<sup>th</sup> day (HE x 40X).

in hepatotoxicity and subsequent increase in serum transaminase<sup>19</sup>. On the basis of above results it may be inferred that the methanolic extract exhibited significant anti-hepatotoxic activity as compared to standard drug silymarin. This effect can be attributed due to its inhibitory effect on microsomal enzymes or on lipid peroxidation. The plant extract can also hinder the formation of the reactive metabolite  $^{\circ}\text{CCl}_3$  by interfering with cytochrome P-450. The other two extracts of petroleum ether and chloroform have shown hepatoprotective activity lesser than the methanolic extract. Histopathological studies have also revealed that the rats treated with methanolic extract had almost normal architecture of hepatocytes indicating significant recovery as compared to the standard silymarin. The preliminary examination of the methanolic fraction has shown the presence of monoterpene acid, which could be responsible for antihepatotoxic activity.

#### ACKNOWLEDGEMENTS

The authors are thankful to the Head Department of Pharmaceutical Chemistry, Faculty of Pharmacy, Jamia Hamdard for providing necessary research facilities and to the in-charge Central Animal Facility, Jamia Hamdard, New Delhi for providing rats and other related facilities for pharmacological activities.

#### REFERENCES

1. Handa SS, et al. *Fitoterapia*, 1986; 57: 307-51.
2. Ravinder K, et al. *Ind J Expt Biol*. 1994; 32: 328-32.
3. Robert H, et al. *Medicinal Plants*, Vol. III, J & A Churchill, New Burlington Street, London, 1880; p-210.
4. Roman RR, et al. *Arch Med Res*. 1992; 23(1): 59-64.
5. El Bardai S, et al. *Clin Exp Hypertens*. 2001; 23: 329-32.
6. De Jesus RA, et al. *Phytomedicine*, 2000; 7: 111-14.
7. Ahmed B, et al. *J Ethnopharmacol*. 2001; 76: 187-89.
8. Vogel H J, *Drug Discovery and Evaluation, Pharmacological Assays*, 2nd Edn., Springer Verlag, Berlin Heidelberg, New York, 2002; p 24.
9. Hukkeri VI, et al. *Indian Drugs*, . 2004; 41: 684-89.
10. Ahmed B, et al. *J Ethnopharmacol*. 2003; 87: 237-40.
11. Reitzmann S, et al. *American J Clin Path*. 1957; 28: 56-63.
12. Kind PRN, et al. *J Clin Path*. 1954; 7: 332.
13. Wooton ID, *Microanalysis in Medical Biochemistry*, 4<sup>th</sup> Edn. Churchill, London, 1964; p 138-40.
14. Dunnet CW, *Biometrics*. 1964; 20: 482.
15. Luna LG, In *Manual of Histology, Staining methods of Armed Forces Institute of Pathology*. 3<sup>rd</sup> Edn. Mc Graw-Hill Book Co. New York, 1986, p 146.
16. Schmidt E, et al. Liver morphology and enzyme release further studies in the isolated perfused rat liver. In: Keppler, D. (Edn.), *Pathogenesis and Mechanism of liver Cell Necrosis*. Medical and Technical, Lancaster, 1975; p 47.
17. Sallic R, et al. *Drugs and the liver biopharmaceutical drug disposition*, 1991; 12: 251-59.
18. Dhuley JN, et al. *J Ethnopharmacol*. 1997; 56: 159-64.
19. Cheesmen KH, *Environmentl Health Perspect*. 1935; 64: 85-101.