

POTENCY OF METHANOLIC EXTRACT OF *ZIZYPHUS JUJUBA* FRUIT AGAINST CARBONTETRACHLORIDE INDUCED HEPATIC DAMAGE IN RATS

Prasanna Kumar SR¹, Asdaq SMB^{1*} and Rawri Rajesh Kumar²

¹Department of Pharmacology; ²Department of Pharmaceutical Chemistry, Krupanidhi College of Pharmacy, # 12/1, Chikkabellandur, Carmelram Post, Bangalore - 560 035, India.

Received on : 29.07.2010

Revised : 27.09.10

Accepted : 22.10.10

ABSTRACT

A high percentage of the people living in developing countries use traditional medicines including medicinal herbs to meet their primary health care needs for various ailments including hepatic damage. Traditionally, the fruits of *Zizyphus jujube* extract have been used in Indian and Chinese system of medicine to strengthen liver function. However, there is no scientific evidence for confirming the efficacy of this herb. Hence, present study was undertaken to evaluate the effect of methanolic extract of *Zizyphus jujube* fruit (MEZJ) on acute (0.5 ml/kg, *p.o.*) and chronic (0.2 ml/kg, *p.o.* twice weekly for eight weeks) models of liver injury induced by carbon tetrachloride (CCl₄) in rats. The MEZJ was administered orally at three different doses of 250 mg/kg, 500 mg/kg and 1000 mg/kg for eight weeks and ten days in chronic and acute models, respectively. The MEZJ (250 mg/kg, *p.o.*) significantly decreased levels of alanine aminotransferase (ALT), aspartate aminotransferase (AST), alkaline phosphatase (ALP) and bilirubin in serum and increased the same in LTH in the chronic model. In acute liver injury, MEZJ (250 mg/kg, *p.o.*) and MEZJ (500 mg/kg, *p.o.*) altered biochemical markers in both serum and LTH indicating hepatoprotective effect. The MEZJ (250 mg/kg, *p.o.*) also showed significant rise in SOD and catalase activities in both chronic and acute models, while MEZJ (500 mg/kg, *p.o.*) caused elevation in antioxidant enzyme activities only in the acute model. The histopathological studies supported the biochemical findings. It is concluded that MEZJ possess good hepatoprotective effect at doses of 250 and 500 mg/kg orally, whereas, 1000 mg/kg was found to be non-effective in preventing the hepatic damage.

Keywords: *Zizyphus jujube*; Hepatoprotective; Carbon tetrachloride; Antioxidants.

INTRODUCTION

Liver is an organ of paramount importance, which plays a pivotal role in regulating and maintaining the biological equilibrium of vertebrates. It has great capacity in detoxifying toxic substances and synthesis of useful principles. Therefore, damage to the liver caused by hepatotoxic agents is of grave consequences¹. In spite of tremendous strides in the modern medicine, there are not many drugs available for the treatment of liver disorders so there is a worldwide trend to go back to traditional medicinal plants. Many natural products of herbal origin are in use for the treatment of liver ailments².

Zizyphus jujuba (Synonym: *Zizyphus sativa*, *Zizyphus vulgaris*) belongs to Rhamnaceae family, commonly known as jujube. The principal chemical constituents of fruit are flavonoids, saponins, and tannins. Jujube is both a delicious fruit and an effective herbal remedy. The plant has been used traditionally as sedative, tonic and diuretic³. The plant is also reported for anti-complementary⁴, anti-cancer⁵, hypoglycemic⁶ and anxiolytic activities⁷. Further, traditionally, jujube is used prophylactically for liver diseases⁸ and to strengthen liver function⁹. To the best of our knowledge there is no

scientific report available in support of the hepatoprotective activity of the plant using modern techniques. Therefore, to justify the traditional claims we have assessed the hepatoprotective effect of methanolic extract of *Zizyphus jujube* fruit (MEZJ) in an experimental model of carbon tetrachloride intoxicated acute and chronic hepatic damage in rats.

MATERIALS AND METHODS

Chemical

All chemicals used were obtained from SD fine chemicals Ltd. (Mumbai, India). Kits for enzyme estimation were purchased from Crest Biosystems, Coral clinical systems, Goa, India. All chemicals used in the present study were procured from standard companies and were of analytical grade.

Experimental animals

Laboratory bred female Sprague-Dawley (SD) rats weighing 175-250 g were housed at 25° ± 5°C in a well-ventilated animal house under 12:12 h light dark cycle. Institutional Animal Ethics Committee approved the experimental protocol. The animals were

*Correspondence : basheer_1@rediffmail.com/sasdaq@gmail.com

Hepatoprotective activity of *Zizyphus jujuba*

maintained under standard conditions in an animal house as per the guidelines of Committee for the Purpose of Control and Supervision on Experiments on Animals (CPCSEA).

Plant material

The shade dried fruits of *Zizyphus jujuba* were purchased from local market in Bangalore (India) and Regional Research Institute (Ay), Bangalore authenticated the fruits. A specimen (RRCBI-Ap2901) has been preserved for future reference. The fruits were mechanically powdered and subjected to exhaustive extraction in a soxhlet apparatus-using methanol. The extract was concentrated under reduced pressure and stored in a desiccator until further use.

Phytochemical estimations of the extract

The methanolic extracts of *Zizyphus jujuba* fruits (MEZJ) were subjected to qualitative analysis for various phytoconstituents such as alkaloids, carbohydrates, glycosides, phytosterols, saponins, tannins, proteins, amino acids and flavonoids.

Acute toxicity study

The acute oral toxicity study was performed according to the OPPTS guidelines (Office of Prevention, Pesticide and Toxic Substance) following the limit test procedure¹⁰. The animals were fasted over night prior to the experiment. Test dose of 2 g/kg and 5 g/kg were given orally to mice. Both doses were found to be safe. Hence, 1/5th, 1/10th and 1/20th of the maximum safe dose corresponding to 1000, 500 and 250 mg/kg orally were selected as high, medium and low doses respectively.

Experimental protocol

The animals were divided into six groups of six each. Group I was vehicle control, treated with vehicle for eight weeks in chronic model and 10 days in acute model. Group II received CCl₄ (twice weekly for eight weeks in chronic model and on 10th day in acute model). Group III was treated with standard (silymarin 100 mg/kg *p.o.*)¹¹ for eight weeks and 10 days in chronic and acute models respectively. Group IV, V and VI were administered MEZJ 1000, 500 and 250 mg/kg orally for eight weeks and 10 days in chronic and acute models respectively.

Carbon tetrachloride induced chronic hepatitis model

During the treatment of animals for eight weeks from group II to VI, CCl₄ (0.2 ml/kg, *p.o.*) diluted with liquid paraffin (1:1) was administered twice weekly¹². Eight weeks after CCl₄ administration started, and 24 hours after the last treatment, the rats were sacrificed. Blood samples were collected by the retro orbital puncture method. Serum was separated and biochemical markers [ALT, AST, ALP and bilirubin (total and direct)] were estimated¹³⁻¹⁵. Liver tissue homogenate (LTH) was prepared in sucrose solution (0.25 M) and used for

Prasanna Kumar SR et al

estimation of endogenous marker enzymes and biological antioxidants viz., superoxide dismutase (SOD)¹⁶ and catalase¹⁷ activities. The liver was then subjected to histopathological examination.

Carbon tetrachloride induced acute hepatitis model

At the end of 10 days treatment of animals from group II to VI, single dose of CCl₄ (0.5 ml/kg, *p.o.*) diluted with liquid paraffin (1:1) was administered¹⁸. After 24 hours of CCl₄ administration the animals were sacrificed and blood was collected by retro orbital puncture. Serum was separated and biochemical markers [ALT, AST, ALP and bilirubin (total and direct)] were estimated. Liver tissue homogenate (LTH) was prepared in sucrose solution (0.25M) and subjected for the estimation of biochemical markers.

Histological analysis

Liver sections were prepared, stained with hematoxylin and Eosin (H&E) and change in histology were observed.

Statistical analysis

Results are expressed as mean ± SEM. Statistical significance was assessed using One-way Analysis of variance (ANOVA) followed by Tukey-Karmer multiple comparison tests. *P*<0.05 was considered significant.

RESULTS

Preliminary phytochemical investigation

The preliminary phytochemical investigation of the MEZJ extract showed the presence of carbohydrates, tannins, flavanoids and saponins. The percentage yield of MEZJ was found to be 17%.

Carbon tetrachloride induced chronic hepatitis model

Administration of CCl₄ resulted in elevation of biochemical markers ALT, AST, ALP and bilirubin (Total and Direct) in serum and depletion in LTH significantly (*P*<0.001) compared to vehicle control. In animals pre-treated with low dose of MEZJ (250 mg/kg) and silymarin, there was significant reduction of biochemical markers (*P*<0.001) in serum compared to CCl₄ control. However, pre-treatment of animals with medium dose of MEZJ (500 mg/kg) showed reduction in only ALP and bilirubin level (*P*<0.01) compared to CCl₄ control (Table-1). Further, there was significant (*P*<0.001) rise in biochemical markers in LTH compared to CCl₄ control in groups pre-treated with MEZJ 250 mg/kg (*P*<0.001), MEZJ 500 mg/kg (*P*<0.01) and silymarin (*P*<0.001). Furthermore, elevated liver weight was significantly reduced in groups treated with MEZJ (250 mg/kg and 500 mg/kg) and silymarin compared to CCl₄ control. Similarly, there was significant (*P*<0.001) incline in SOD and Catalase activities in groups pre-treated with MEZJ (250 and 500 mg/kg, *p.o.*) and silymarin compared to CCl₄ control (Table-2). On the contrary, MEZJ (1000

Hepatoprotective activity of *Zizyphus jujuba* (mg/kg) did not produce any significant ($P > 0.001$) change in biochemical enzyme levels and antioxidant activities in serum as well as in LTH compared to CCl_4 control. Moreover, histological studies showed regeneration of hepatocytes with low dose of MEZJ (Figure-1C) and silymarin.

Table 1: Effects on serum ALT, AST, ALP and bilirubin (total and direct) levels in CCl_4 induced chronic hepatotoxicity in rats.

| | | | | | | | | | |
|--|--|--|--|--|--|--|--|--|--|
| | | | | | | | | | |
| | | | | | | | | | |
| | | | | | | | | | |
| | | | | | | | | | |
| | | | | | | | | | |
| | | | | | | | | | |
| | | | | | | | | | |
| | | | | | | | | | |
| | | | | | | | | | |
| | | | | | | | | | |

Values are mean \pm SEM, n = 6, ^a P < 0.05, ^b P < 0.01, ^c P < 0.001 Vs vehicle control. * P < 0.05, ** P < 0.01, *** P < 0.001 Vs CCl_4 control. MEZJ = Methanolic extract of *Zizyphus jujuba* fruits.

Table 2: Effect on ALT, AST, ALP and bilirubin (total and direct) levels in liver tissue homogenate and liver weight, SOD and catalase (CAT) in chronic induced acute hepatotoxicity in rats.

| | | | | | | | | | |
|--|--|--|--|--|--|--|--|--|--|
| | | | | | | | | | |
| | | | | | | | | | |
| | | | | | | | | | |
| | | | | | | | | | |
| | | | | | | | | | |
| | | | | | | | | | |
| | | | | | | | | | |
| | | | | | | | | | |
| | | | | | | | | | |
| | | | | | | | | | |

Values are mean \pm SEM, n = 6, ^a P < 0.05, ^b P < 0.01, ^c P < 0.001 Vs vehicle control. * P < 0.05, ** P < 0.01, *** P < 0.001 Vs CCl_4 control. MEZJ = Methanolic extract of *Zizyphus jujuba* fruits.

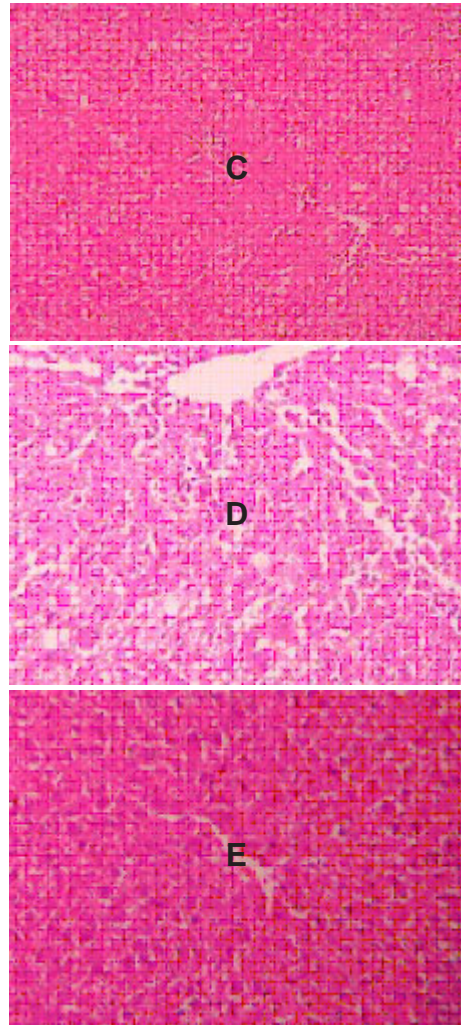
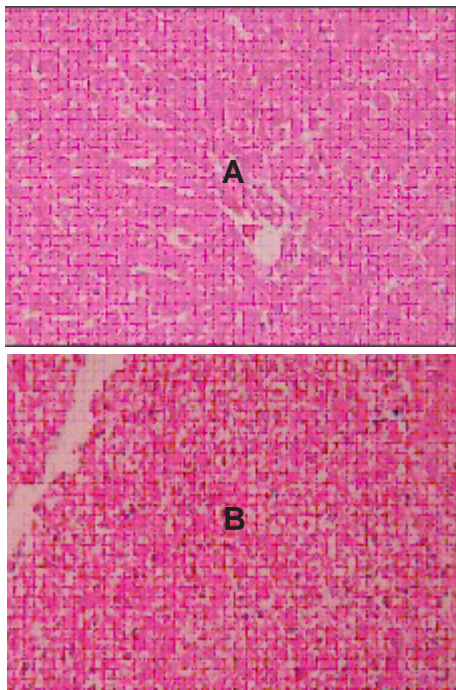


Fig.1: Microphotographs of H&E (100 X) stained histological sections of liver.

- (A) Control: Normal architecture is evident.
- (B) CCl_4 control-chronic model: The figure shows moderate degree of fatty changes, mild congestion, fibrosis, regeneration and cirrhosis.
- (C) CCl_4 +MEZJ (250 mg/kg)-chronic model: The treatment of MEZJ (250 mg/kg) shows mild protection to hepatocytes with mild cirrhosis.
- (D) CCl_4 control-acute model: Single higher dose of CCl_4 shows hepatic cells with extensive fatty change and ballooning of hepatocytes, more around central vein, centrilobular necrosis and hyperplasia.
- (E) CCl_4 +MEZJ (250 mg/kg)-acute model: The prophylactic treatment indicated partial protection to hepatocytes with mild necrosis.

Carbon tetrachloride (CCl_4) induced acute hepatic injury

A significant ($P < 0.001$) change in biochemical enzyme levels was observed between normal and CCl_4 control groups in serum and LTH. Pre-treatment of animals with MEZJ (250 and 500 mg/kg, p.o.) and silymarin significantly ($P > 0.001$) decreased the elevated levels

Hepatoprotective activity of *Zizyphus jujuba*

of biochemical enzymes in serum and increased the depleted levels in LTH compared with CCl₄ control. Moreover, high dose of MEZJ (1000 mg/kg, *p.o.*) significantly (*P*<0.01) declines the ALT, AST and ALP levels in serum and inclines in LTH compared to CCl₄ control. However, MEZJ (1000 mg/kg) failed to reduce elevated level of bilirubin (total and direct) in serum. Administration of CCl₄ causes significant (*P*<0.001) increase in liver weights when compared to vehicle control. Pre-treatment with MEZJ (250, 500 and 1000 mg/kg) and silymarin significantly (*P*<0.001) reduces liver weights compared to CCl₄ control. Further, there was significant (*P*<0.001) rise in SOD and Catalase activities in groups pre-treated with MEZJ (250, 500 and 1000 mg/kg, *p.o.*) and silymarin compared to CCl₄ control (Table-3 & 4). Histological studies show regeneration (Figure-1E) of hepatocytes in liver tissues of animals prophylactically treated with MEZJ (250 mg/kg and 500 mg/kg).

Table 3: Effects on serum ALT, AST, ALP and bilirubin (total and direct) levels in CCl₄ induced acute hepatotoxicity in rats.

| | | | | | | | | | |
|--|--|--|--|--|--|--|--|--|--|
| | | | | | | | | | |
| | | | | | | | | | |
| | | | | | | | | | |
| | | | | | | | | | |
| | | | | | | | | | |
| | | | | | | | | | |
| | | | | | | | | | |
| | | | | | | | | | |
| | | | | | | | | | |
| | | | | | | | | | |

Values are mean ± SEM, n = 6, ^a *P* <0.05, ^b *P* <0.01, ^c *P* <0.001 Vs vehicle control. * *P* <0.05, ** *P* <0.01, *** *P* <0.001 Vs CCl₄ control. MEZJ = Methanolic extract of *Zizyphus jujuba* fruits.

Table 4 : Effect on ALT, AST, ALP and bilirubin (total and direct) levels in Liver tissue homogenate and liver weight, SOD and catalase (CAT) in acute induced acute hepatotoxicity in rats.

| | | | | | | | | | |
|--|--|--|--|--|--|--|--|--|--|
| | | | | | | | | | |
| | | | | | | | | | |
| | | | | | | | | | |
| | | | | | | | | | |
| | | | | | | | | | |
| | | | | | | | | | |
| | | | | | | | | | |
| | | | | | | | | | |
| | | | | | | | | | |
| | | | | | | | | | |

Values are mean ± SEM, n = 6, ^a *P* <0.05, ^b *P* <0.01, ^c *P* <0.001 Vs vehicle control. * *P* <0.05, ** *P* <0.01, *** *P* <0.001 Vs CCl₄ control. MEZJ = Methanolic extract of *Zizyphus jujuba* fruits.

DISCUSSION

The present study was designed to evaluate the pharmacological efficacy of methanolic extract of *Zizyphus jujube* fruit (MEZJ) against acute and chronic hepatic damage induced by carbon tetrachloride (CCl₄) in experimental animals to confirm the traditional claim for hepatoprotective potential. The result indicated that MEZJ was effective in low and medium doses (250 and 500 mg/kg, *p.o.*) at times of acute stress, whereas, during chronic damage to hepatocyte, only low dose

(250 mg/kg, *p.o.*) of MEZJ is potent enough to reverse the damaging effect of hepatotoxin such as CCl₄. On the contrary, high dose (1000 mg/kg, *p.o.*) of MEZJ was found to be least effective in presence of damage to liver.

Carbon tetrachloride (CCl₄) is a potent hepatotoxic agent often used to induce hepatic lesions. Short-term administration of CCl₄ causes acute hepatocellular injury with centrilobular necrosis and steatosis. Chronic administration may lead to cirrhosis (liver fibrosis)¹⁹. CCl₄ is catalyzed by cytochrome P450 enzyme and forms the highly reactive trichloromethyl free radical. This then readily interacts with molecular oxygen to form the trichloromethyl peroxy radical. The free radical can form covalent bond with sulfahydryl group, such as glutathione (GSH), protein thiol and lipids or abstracting a hydrogen atom from an unsaturated lipid. This covalent binding of free radical to cell macromolecules is considered the initial step in a chain of events, which eventually leads to membrane lipid peroxidation, liver damage and finally cell necrosis^{20,21}.

Damage to the membrane leads to leakage of endogenous biomarkers into the circulation and thereby decreasing the intracellular enzyme levels. This is demonstrated in our study by an elevation in the serum marker enzymes such as AST, ALT, ALP and direct and total bilirubin and depletion of these enzymes in the liver tissues. Prophylactic administration of MEZJ (250 & 500 mg/kg, *p.o.*) was found to revert back the normal condition to the hepatic musculature as shown by biochemical and histological findings. The stimulation of hepatic regeneration was considered as the possible hepatoprotective mechanism of MEZJ (250 & 500 mg/kg, *p.o.*). Such stimulation was known to cause the liver to become more resistant to hepatotoxin induced liver injuries²². Likewise, activation of the functions of the reticuloendothelial system²³ or inhibition of protein biosynthesis²⁴ were also considered as some possible hepatoprotective mechanisms, which could reduce the hepatotoxicity of CCl₄. Since saponins are thought to have a membrane-stabilizing action²⁵, the cytoprotective effect of MEZJ (250 & 500 mg/kg, *p.o.*) could also be attributed to membrane-stabilizing role of MEZJ during acute and chronic hepatic damage.

As discussed above, CCl₄ induces free radical formation and reduction in antioxidant activities such as superoxide dismutase (SOD) and Catalase in LTH. Pre-treatment of animals with low and medium doses of MEZJ (250 & 500 mg/kg, *p.o.*) and silymarin causes remarkable elevation in antioxidant activities. Elevated activity of catalase in LTH is more beneficial than increase in SOD activity alone because without a simultaneous increase in catalase activity, increased SOD activity may lead to intracellular accumulation of H₂O₂ with detrimental effects²⁶. The augmented antioxidant activities in LTH could be due to presence of flavanoids in MEZJ (250 & 500 mg/kg, *p.o.*).

Hepatoprotective activity of *Zizyphus jujuba*

Carbon tetrachloride induced a significant increase in liver weight due to blocking of secretion of hepatic triglycerides into the plasma²⁷. Pre-treatment with MEZJ (250 and 500 mg/kg, *p.o.*) and silymarin prevented the increased liver weight.

In chronic model, CCl₄ induces moderate degree of fatty changes, mild congestion, fibrosis and cirrhosis. Low dose of MEZJ (250 mg/kg, *p.o.*) provided protection to hepatocyte from fatty changes, congestion and cirrhosis. In acute model, extensive fatty change with ballooning of hepatocytes predominantly around central vein, centrilobular necrosis and hyperplasia was seen with single high dose of CCl₄. Low and medium dose of MEZJ (250 and 500 mg/kg, *p.o.*) produces partial protection in hepatocytes with mild necrosis.

The results of the present study support the traditional use of the fruits in hepatoprotection. The maximum efficacy was seen with low dose (250 mg/kg, *p.o.*) of MEZJ, whereas, medium dose (500 mg/kg, *p.o.*) of MEZJ was moderately effective in keeping the integrity of hepatocytes during damage. The protection offered by the extract may be attributed to antioxidant activity and membrane stabilizing role of flavonoids and saponins respectively, in the fruit extract²⁸. However, with the present study it is difficult to predict the reason for reduced efficacy of high dose (1000 mg/kg, *p.o.*) of MEZJ.

CONCLUSIONS

From our study it may be concluded that the low dose of MEZJ (250 mg/kg) possess good hepatoprotective activity in chronic hepatitis induced by CCl₄ whereas low and medium dose of the MEZJ (250 mg/kg and 500 mg/kg) potentially ameliorates acute hepatitis induced by CCl₄. The protective effect may be because of the presence of flavonoids and saponins in MEZJ. However, further studies should be carried out to isolate the active constituent of MEZJ responsible for its therapeutic efficacy as well as to elucidate the underlying mechanism of action.

ACKNOWLEDGEMENTS

Authors are thankful to Prof. Dr. Suresh Nagpal Chairman and Prof. Sunil Dhamanigi, Secretary, Krupanidhi Institutions for, constant encouragement, infrastructure and all other essential facilities for the successful completion of this research work.

REFERENCES

1. Shanmugasundaram P, *et al.* J. Ethnopharmacol. 2006;104:124.
2. Bhandarkar MR, *et al.* J. Ethnopharmacol. 2004; 91:61.
3. Nadakarni KM. Indian material medica. Volume I. Bombay: Popular prakashan; 2002. p.212.
4. Lee SM, *et al.* Biol Pharm Bull. 2004;27:1883.

Prasanna Kumar SR *et al*

5. Huang X, *et al.* Am J Chin Med. 2007;35:517.
6. Iganacimuthu S, *et al.* Indian J Pharmacol. 1998;30:107.
7. Peng WH, *et al.* J. Ethnopharmacol. 2000; 72:435.
8. Raj JK, *et al.* Indian Drugs. 1999;36:668.
9. Khare CP. In *Encyclopedia of Indian Medicinal Plants*. New York: Springer; 2004. p.113.
10. Health Effect Test Guidelines, Acute Oral Toxicity, OPPTS 870, 1100 United States Office of Prevention, Pesticides and Toxic Substances Environmental Protection Agency (7101). [Available from: URL: <http://www.epa.gov/opptsfrs/home/guidelin.htm>. 5/7/2008].
11. Yadav NP, *et al.* Phytomedicine. 2008;15:1053.
12. McLean EK, *et al.* Br J of Exp Path. 1969;50:502.
13. Reitman S, *et al.* Am J Clin Pathol. 1957;28:53.
14. Kind PRN, *et al.* J Clin Pathol. 1954;7:322.
15. Malloy HT, *et al.* Int J Biol Chem. 1937;119:481.
16. Erich F, Elastner. Anal Chem. 1976;70:616.
17. Eva ML. Arch Biochem Biophys. 1988;365:362.
18. Shenoy KA, *et al.* Indian J Pharmacol. 2001;33:260.
19. Zim MCA, *et al.* Braz J Med Biol Res. 2002; 35:1339.
20. Sana J, *et al.* J Pharmacol Toxicol. Met 2002; 48:41.
21. Ahmed S, *et al.* J Ethnopharmacol. 2000;69:157.
22. Lesh R, *et al.* Exp Mol Pathol. 1970;12:58.
23. Gruen M, *et al.* Acta Hepato- Gastroenterol. 1974;21:5.
24. Castro J A, *et al.* Toxicol Appl Pharmacol. 1977; 41:305.
25. Abe H, *et al.* Naunyn-Schmiedberg's Arch Pharmacol. 1981;316:262.
26. Das DK, *et al.* J Mol Cell Cardiol. 1995;27:181.
27. Yoko A, *et al.* Biol Pharm Bull. 2005;28:19.
28. Bhat AD, *et al.* Indian J Gastroenterol. 1996; 15:63.