

# To Study the Functional Outcome of Primary Cemented Bipolar Hemiarthroplasty in the Management of Unstable Inter-Trochanteric Fracture of Femur among Elderly

Parth Vinod Agrawal, Nitin Wagh and Sandeep Pangavane

Department of Orthopaedics, Nashik, Maharashtra – 400610, India

## Abstract

**Aims and Objectives:** To evaluate the results with regard to function, to restoring proper limb length after surgery and to study the associated complications in intertrochanteric fractures treated by cemented bipolar hemiarthroplasty in elderly. **Methodology:** This is a prospective study of 25 cases of Intertrochanteric fractures admitted to a tertiary care center between August 2013 and November 2015 treated with Cemented Bipolar Hemiarthroplasty for intertrochanteric fractures. Cases were taken according to inclusion and exclusion criteria. **Results:** In our study of 25 cases, there were 14 male and 11 female patients with mean age of 72.8 years. 80% of the cases admitted were due to trivial trauma, 20% due to RTA with left side being more common side affected. According to OTA classification Type 31A2.2 fractures accounted for 60% of cases & Type 31A2.3 accounted for 40 %. Mean duration of hospital stay was 13.2 days and mean time of full weight bearing was 4.7 days in our patients. Excellent was seen in 24% cases Fair to Good results were seen in 72% of cases in our study according to Harris Hip Score. **Conclusion:** From our study we conclude that Cemented Bipolar Hemiarthroplasty for intertrochanteric fractures in elderly reduced the complications of prolonged immobilisation, prolonged rehabilitation, marked residual deformities and need for revision surgeries. The procedure offered, faster mobilization, rapid return to pre injury level, improved the quality of life.

**Keywords:** Hemiarthroplasty, Harris Hip Score, Intertrochanteric Fractures

## 1. Introduction

Intertrochanteric femur fracture is one of the most important health problems amongst the elder population. Incidence of these fractures has increased primarily due to increasing life span and more sedentary life style brought by urbanization. In younger population, IT fracture occurs due to high velocity trauma, whereas in elderly population, it is most often due to trivial trauma<sup>1</sup>. Incidence of intertrochanteric fractures is more in females compared to males due to osteoporosis. Mortality ranges between 15%-20%<sup>1</sup>.

IT fractures can be managed by conservative or operative methods. Conservative methods were the treatment of choice until 1960 before the introduction of new fixation devices. As conservative methods resulted in higher mortality rates and complications like

decubitus ulcer, urinary tract infections, pneumonia, thromboembolic complications. These methods have been abandoned. Conservative methods are now indicated under 2 conditions,

- Elderly person with high medical risk for anesthesia and surgery.
- Non ambulatory patient with minimal discomfort following injury<sup>1,9</sup>.

A successful surgery at the hip joint should provide a painless, stable hip with wide range of movements. But, none of the accepted procedures have been able to achieve the goal fully. The patient needs to go through in many instances, multiple surgical procedures and a prolonged rehabilitation in order to preserve his original joint.

Bipolar hemiarthroplasty offers a durable and versatile solution for unstable intertrochanteric fractures in the elderly<sup>1,8</sup>. It can be done as a primary procedure or

secondary to failure of conservative or internal fixation, offering an advantage of rapid return of function with a pain-free, stable and mobile hip<sup>1</sup>.

## 2. Material and Methods

25 cases of Intertrochanteric femur fractures were treated with hemiarthroplasty studied between August 2013 and December 2015 were studied prospectively. There were 14 males and 11 females. All patients were above age of 60 yrs. The fractures were classified according to OTA classification and Evans classification, only Ao/OTA type 31-A2.2 and 31-A2.3 and Evans type III or IV were included in this study. Although the OTA classifies these as peritrochanteric, however since we used Evans classification we retained terminology intertrochanteric fracture. Patients that were non ambulatory previous to trauma, less than 60 yrs of age, polytrauma patients were excluded from study. None of our patients had preexisting hip pathology.

All surgeries were performed using standard posterior Coxa femoral approach with patient in lateral position under spinal anaesthesia. From a point 10 cm distal to posterior superior iliac spine and extended distally and laterally parallel to the fibres of gluteus maximus to the posterior margin of the greater trochanter and then directed about 10cm parallel to the femoral shaft. Deep fascia was exposed and divided in line with the skin incision as also was the fascia over gluteus maximus, which was then split in the direction of its fibres using blunt dissection. By retracting the proximal fibres of the muscle proximally, the greater trochanter is exposed. Distal fibres are retracted distally and partly divided at their insertion into the linea-aspera in line with the distal part of the incision. The fractured greater trochanter is reflected anteriorly. The sciatic nerve was usually not exposed, and if it was, it was gently retracted out of the way. The gemelli, obturator internus and the piriformis tendons were retracted with greater trochanter. The posterior part of the capsule thus exposed is incised from distal to proximal along the line of neck of femur and at right angle to it, thus making a T shaped opening. The distal part of the capsule is detached from the femur.

The thigh and knee are flexed to 90° and the thigh is rotated internally to expose the neck of the femur, osteotomy was done at the level of the neck, then the hip was dislocated posteriorly. The head of the femur was levered out of the acetabulum and size measured using template, the size was confirmed using trial prosthesis. The acetabulum was prepared, the remnant ligamentum teres was completely excised and the remaining soft

tissue from the region of pulvinar region was curetted. The femoral shaft was rasped using a broach (rasp) and prepared for the insertion of the prosthesis.

Bipolar stem was cemented in place in 10-15° of anteversion using standard cementing techniques – lavage, cleaning, drying and plugging of the canal. Then the greater trochanter was put back in place, in case of comminution it was fixed using a SS wire and k-wires. After suturing the capsule the external rotators and greater trochanter were sutured with help of k wires and TBW, the wound was closed in layers over a suction drain, which is removed at the first change of dressing after 48hrs.

All patients underwent a routine postoperative physiotherapy protocol that included early gait training in form of walking with the help of a walker starting second day post surgery. The rehabilitation then progressed as tolerated by the patients. Patients were examined postoperatively at 6 weeks, 3 months, 6 months, 9 months and thereafter annually. At each follow-up visit, a clinico-radiological examination was done and the patient was evaluated using the Harris hip score (HHS) and were graded as <70 poor, 70-79 Fair, 80-89 Good and 90-100 Excellent. Anteroposterior radiographs of the hip were analyzed at each follow-up to note evidence of loosening

## 3. Results

The following observations were made from the data collected during the study of 25 cases of intertrochanteric fractures treated by cemented bipolar hemiarthroplasty in the Department of Orthopaedics in tertiary care center between august 2013 to august 2015.

Use of bipolar prosthesis in trochanteric fractures among the elderly, 25 patients with mean age of 72.8 years was included.

Cerclage wiring with k wire to hold the greater trochanter was done in case of 15 patients and Ethibond no-5 was used to hold greater trochanter in 10 cases. There was a low rate of infections, namely superficial infection in 2 cases (10%) and superficial bed sores in 1 case (5%).

The mean day for full weight bearing was on the 4.36<sup>th</sup> day.

Post operatively 4 patients (16%), had a shortening of less than 2 cms and 2 patients (8%), had a shortening of more than 2 cms. 4 patients had lengthening of less than 2 cms (16%).

Two patients (8%) had fixed external rotation of the operated limb of less than 20 degrees. Two patients (1%) had a flexion deformity of than 20 degrees.

There was no incidence of postoperative dislocation of the prosthesis in the study.

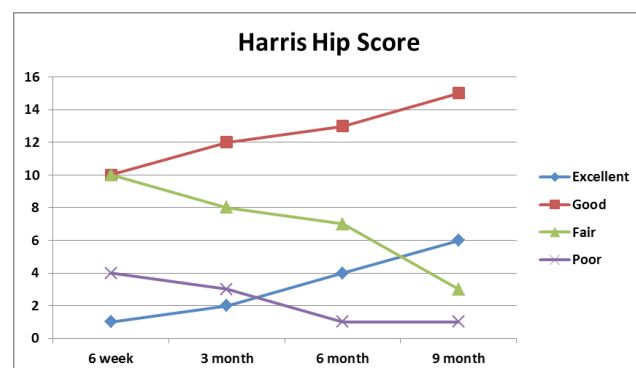
Patients were discharged from the hospital at a mean on the 13.2<sup>nd</sup> day.

Patients were followed up at 6 weeks, 3 months, 6 months and 12 months, 3 patients were lost in follow up. The mean time of follow up was 9 months. Majority of the patients had a pain free mobile hip, with full range of flexion, abduction and adequate amount of rotations and adduction.

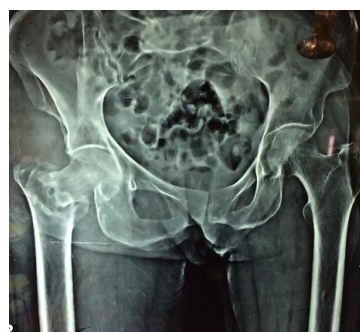In our study, there was no incidence of loosening of the prosthesis or acetabular erosion radiologically on follow up. There was no incidence of revision surgeries. The final functional results were fair to good according to Harris hip scoring system.

**Table 1.** Functional results according to Harris hip score at 6 weeks, 3 months, 6 months, 9 months

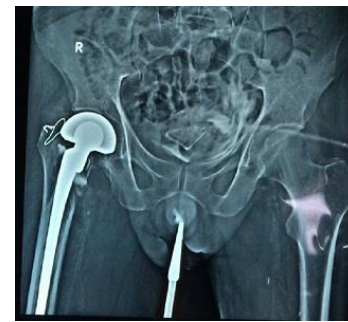| Harris Hip Score | 6 week | 3 month | 6 month | 9 month |
|------------------|--------|---------|---------|---------|
| Excellent        | 1      | 2       | 4       | 6       |
| Good             | 10     | 12      | 13      | 15      |
| Fair             | 10     | 8       | 7       | 3       |
| Poor             | 4      | 3       | 1       | 1       |
| Total            | 25     | 25      | 25      | 25      |



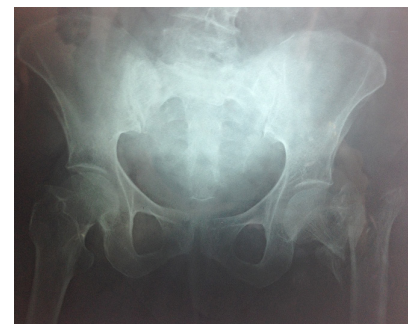**Graph 1.** Functional results according to Harris hip score at 6 weeks, 3 months, 6 months, 9 months.



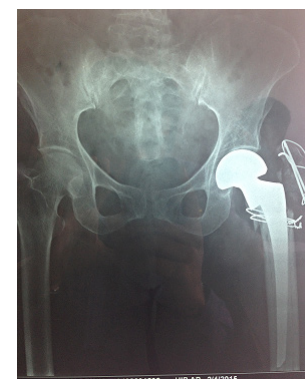(a)



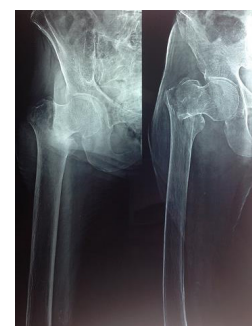(b)



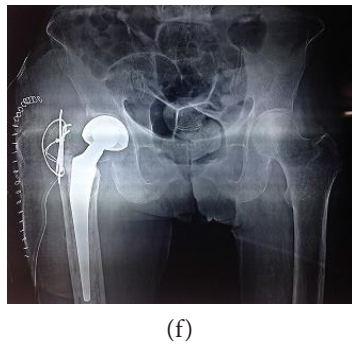
(c)



(d)



(e)



**Figure 1.** (a) Pre-op x-ray:-Case 1. (b) Post-op x-ray:-Case 1. (c) Pre-op x-ray:-Case 2. (d) Post-op x-ray:-Case 2. (e) Pre-op x-ray:-Case 3. (f) Post-op x-ray:-Case 3.

## 4. Discussion

Over the years osteosynthesis has been indicated as the preferable mode of treatment for stable intertrochanteric fractures and has shown promising results but high rate of mortality, complications due to recumbency in initial postoperative year render this option impractical in unstable Intertrochanteric fracture cases. Primary cemented bipolar hemiarthroplasty has emerged as a valid choice for treatment of unstable inter-trochanteric fractures and has shown promising results with fewer complications. With this background, the present study was carried out with an aim to evaluate functional outcome in cemented bipolar hemi-arthroplasty as the primary treatment choice among elderly patients with unstable Intertrochanteric fracture. The concept of dual bearing surfaces in prosthesis, offers considerable advantages. It results in sharing of motion at the two surfaces and hence reduces the net wear at either surface, thus reducing erosion at the acetabular joint interface<sup>1</sup>. In addition, the total range of motions at the joint is increased.

In our study of 25 cases, 14 patients were males and 11 patients were females, OTA classifications for trochanteric fractures were used in the study. In our study, 15 patients presented with 31A2.2 fractures, 10 patients with 31A2.3 fractures.

Cerclage wiring with k-wiring was done in 15 cases to fix greater trochanter. There was incidence of postoperative superficial infection in 2 patients who had serous discharge within 5 days of post-operative period. They responded to conservative treatment of oral antibiotics. 1 patient had a couple of superficial bedsores which were dressed daily and healed before the patient was discharged from the hospital.

Postoperatively, 6 patients had shortening of the

operated limb of which 4 had less than 2 cms, so they were given a heel raise. They walked with the help of a cane. Two patients had shortening more than 2 cm, they had slight limp and used support of a quadruple walker while walking. 4 Patients had lengthening of less than 2 cm.

The operated limb was fixed in 20 degrees of external rotation in 2 cases. One patient had a flexion deformity which was less than 20 degrees. There was no incidence of acetabular erosion, loosening or dislocation of the prosthesis in this series, on follow up up to 9 months.

Full weight bearing was allowed on and after the third post-operative day. The mean day of full weight bearing was on the 4.7<sup>th</sup> day.

10 patients were discharged after suture removal on 12<sup>th</sup> day.

The mean number of days spent by the patient in the hospital was 13.2 days. All patients were advised not to squat and sit crossed legged.

The patients were followed up at 6 weeks, 3 month, 6 months and 9 months post operatively.

At the end of 6 months 6 patients walked without any support, 10 patients walked with the help of a cane, 5 patients used walker. 4 patients complained of occasional anterior thigh pain on long distance walking, which was relieved on taking rest and analgesics.

The functional results were graded according to Harris Hip Scoring System, where in, a score of more than 90 indicates excellent result, a score in between 80 and 90 indicates good results, a score in between 70 and 80 indicates fair results and a score below 70 is rated as poor. In our study at end of 9 months, 6 patients had excellent results, 15 patients had good results, 3 patients had fair results, and 1 case had poor result.

Green et al.,<sup>2</sup> in a series of 20 cases, performed bipolar hemiarthroplasty for elderly patients with unstable trochanteric fractures with a mean time to ambulation of 5.5 days, and a mean follow up of 13.2 months. Amongst the 20 cases, 7 patents had excellent results, 11 patients had good results, 7 patients had fair results, 5 patients had poor results and 3 patients died. They concluded that with technical considerations in mind head neck replacement hip arthroplasty for unstable intertrochanteric fractures in forgetful, elderly patients was a suitable alternative to internal fixation because the prosthesis provided for early full weight bearing and rapid rehabilitation.

Haentjens et al.,<sup>3</sup> in a series of 37 cases, with a mean age of 82 years who sustained unstable intertrochanteric fractures were treated with immediate bipolar hemiarthroplasty. Amongst the 37 cases, who were rated according to criteria of Merle d'Aubigne, 7 patients had



excellent results, 11 patients had good results, 7 patients had fair results, 5 patients had poor results and reported death of 3 cases. They concluded that immediate bipolar hemiarthroplasty for independently mobile patients older than 70 years having unstable intertrochanteric fractures, allowed early walking with full weight bearing and helped the patients to return to prefracture level of activity rapidly, preventing complications such as pressure sores, pneumonia, and atelectasis and pseudo arthrosis. They observed bone callus radiologically 4 weeks post operatively on the medial aspect of the femur and sometimes completely surrounding the prosthesis.

Rosenfeld et al.,<sup>4</sup> in a series of 72 elderly patients with unstable trochanteric fractures treated using head neck replacement prosthesis. The series showed excellent results in 33 patients, good results in 21 patients, fair results in 11 patients, poor results in 2 patients and reported death of 5 patients. They concluded that in elderly, frail and confused patients who had intertrochanteric fractures, hemiarthroplasty helped in faster ambulation and reduced the complications.

Casey C K et al.,<sup>5</sup> in series of 55 patients with intertrochanteric fractures, with a mean age of 84.2 years, were treated using cemented bipolar hemiarthroplasty. They reported excellent results in 19 cases good results in 8 cases, and death of 12 cases in the series. They concluded that, cemented bipolar hemiarthroplasties for intertrochanteric fractures have the advantage because the patients can bear full weight immediately after the surgery and there was no risk of excessive collapse, compromising walking function and so is a reasonable alternative to a sliding screw device for the treatment of unstable IT fracture.

A C Vahl et al.,<sup>6</sup> in a series of 22 patients with unstable trochanteric fractures with severe comminution and osteoporosis. Endoprosthesis was inserted in 5 patients with subtrochanteric and 17 with pertrochanteric fractures. Pre and postoperative ambulation levels were classified. Seventeen patients (17%) achieved full weight bearing mobilization. Five patients never walked again (23%). 2 patients died in first month (9%). It is concluded that for elderly and debilitated patients with an unstable trochanteric fracture, hemiarthroplasty is an acceptable alternative to osteosynthesis.

Chris Grimsud et al.,<sup>7</sup> in a series of 39 patients with unstable three and four part intertrochanteric hip fractures, treated with cemented bipolar hip arthroplasty with a novel technique of cerclage fixation of the trochanteric bone fragments allowing retention of the femoral calcar. At one year minimum follow up, there was no loosening or subsidence of the femoral components. All trochanters healed. One dislocation and one deep

infection occurred. They concluded that, this technique allows safe early weight bearing on the injured hip and had a relatively low rate of complications.

KH Sancheti, PK Sancheti, AK Shyam, S Patil, Q Dhariwal, R Joshi<sup>8</sup> analyzed 37 cases of primary hemiarthroplasty performed for osteoporotic unstable I.T. fractures (AO/OTA type 31-A2.2 and 31-A2.3 ). There were 27 females and 10 males with a mean age of 77.1 years . The series showed two patients died due to unrelated cause (myocardial infarction) within 6 months of surgery and remaining 35 patients were followed up to an average of 24.5 months (range, 18-39 months). A total of 32 out of 35 patients (91%) had excellent to fair functional results and 2 had poor result with respect to the Harris hip score (mean 84.8±9.72, range 58-97). Hemiarthroplasty for unstable osteoporotic intertrochanteric fractures in elderly results in early ambulation and good functional results although further prospective randomized trials are required.

We conclude that the procedure offered excellent painless, mobile, stable hip, with easy rehabilitation and rapid return to functional level, when standard techniques were used.

Bipolar hemiarthroplasty reduced the complications of prolonged immobilization, prolonged rehabilitation, marked residual deformities and need for revision surgeries. The procedure offered, faster mobilization, rapid return to pre injury level, improved the quality of life and gave a long term solution in elderly patients with intertrochanteric fractures of the femur.

## 5. References

1. Canale ST. Campbell's operative orthopaedics. 12th ed.
2. Green S, Moore T, Prano F. Bipolar prosthetic replacement for the management of unstable Inter trochanteric hip fractures in the elderly. Clin Orthop. 1987 Nov; 224:169-77. PMID:3665238.
3. Haentjens P, Castelyn PP, De Boeck H, et al. Treatment of unstable inter trochanteric and subtrochanteric fracture's in elderly patients. JBJS. 1989 Sep; 71(A):1214-25.
4. Robert T, Rosenfeld, Schwartz DR. Alter AH. Prosthetic replacement of trochanteric fractures of femur. JBJS. 1973; 55(A):420.
5. Chan KC, Gill GS. Cemented hemi arthroplasties for Elderly patients with Inter trochanteric hip fractures. Clin Orthop. 2000 Feb; 371:206-15. <https://doi.org/10.1097/00003086-200002000-00025>
6. Vahl AC, DunkiJacobs PB, Patka P, Haarman HJThM. Hemi-arthroplasty in elderly, debilitated patients with an unstable femoral fracture in the trochanteric region. Actaorthopaed-ica Belgica. 1994; 60(3):274-9. PMID:7992603.
7. Grimsrud C, Monzon RJ, Richman J, Ries MD. Cemented hip arthroplasty with a novel cerclage cable technique for

- unstable intertrochanteric hip fractures. J Arthroplasty. 2005 Apr; 337–43. PMID:15809952. <https://doi.org/10.1016/j.arth.2004.04.017>
8. Sancheti KH, Sancheti PK, Shyam AK, Patil S, Dhariwal Q, Joshi R. Primary hemiarthroplasty for unstable osteoporotic intertrochanteric fractures in the elderly: A retrospective case series. Indian J Orthop. 2010 Oct-Dec; 44(4):428–34.
  9. Koval KJ, Zuckerman JD. Rockwood and green's fracture in adults. Bucholz RW, Heckman JD, editor. 6th ed. J. B. Lippincott Company; 2001. p. 1794–825.