



Treatment of diabetic foot ulcers with autologous bone marrow cells, platelets, fibrin glue and collagen matrix

Prof. (Dr) Gajanan Ekbote¹,
Professor of Surgery

Dr Arvind Giram³
Resident

Dr Sarfraj Pathan²,
Assoc. Professor of Surgery

Dr Ahsan Zuberi⁴,
Resident

Abstract :

Objectives : *To study the role of autologous bone marrow in healing chronic diabetic wound And to evaluate the cost effectiveness*

Methods : *Autologous Bone Marrow aspirated under spinal anaesthesia and Bone Marrow-total nucleated cells were separated and concentrated. 100 mL peripheral blood were taken and platelets and fibrin glue were prepared according to standard procedures. Then it was locally applied and regular dressing done. Pt was followed for six weeks, with assessing the wound every week.*

Results : *35 patients were studied and 3 patients had complete closure of the wound. One patient did not show significant improvement. Rest all the patients had significant reduction of wound size after 6 weeks.*

Conclusion : *Patients treated with autologous bone marrow cells, platelets, fibrin glue and collagen matrix did show significant reduction in the wound size. Use of these components was safe and effective and this treatment had been cost effective.*

Key Words : *Bone Marrow, Platelets, Fibrin Glue, Collagen Matrix*

INTRODUCTION

Definition: Diabetic foot ulcers are defined as foot affected by ulceration that is associated with neuropathy and/or peripheral arterial disease of the lower limb in a patient with diabetes [1].

Diabetic foot ulcers are also defined as: neuropathic in the presence of peripheral diabetic neuropathy and absence of ischemia; ischemic if the patient presents peripheral artery disease but no diabetic peripheral neuropathy;

and neuroischemic if neuropathy and ischemia coexist [1].

The prevalence of diabetic foot ulceration in the diabetic population is 4–10%; the condition is more frequent in older patients. It is estimated that about 5% of all patients with diabetes present with a history of foot ulceration, while the lifetime risk of diabetic patients developing this complication is 15%[2-4]

Foot ulcers are a significant complication of diabetes mellitus and often precede lower extremity amputation. The most frequent underlying etiologies are neuropathy, trauma, deformity, high plantar pressures, and peripheral arterial disease. Loss of protective sensation is the primary factor in foot ulceration in diabetics. Mechanical stresses resulting from joint deformity, limited joint mobility, and poor foot care/footwear are important in the causal pathway of both neuropathic and ischemic ulcers. It was shown that the recurrence of foot infection was common among Indian diabetic patients (52%). A lesser prevalence of peripheral vascular disease (13%) among Indians was noted when compared with those in Western countries (48%). Smoking increases the risk by reducing blood circulation in the legs and reducing sensation in the feet [5].

Impaired local blood circulation as a result of micro and macrovascular disease and peripheral neuropathy causes foot ulceration in up to 25% of patients with diabetes mellitus (DM) [6]. Foot ulceration is associated with increased morbidity and mortality, has a negative impact on the quality of life of diabetic patients and poses a serious burden on the health care system [7,8].



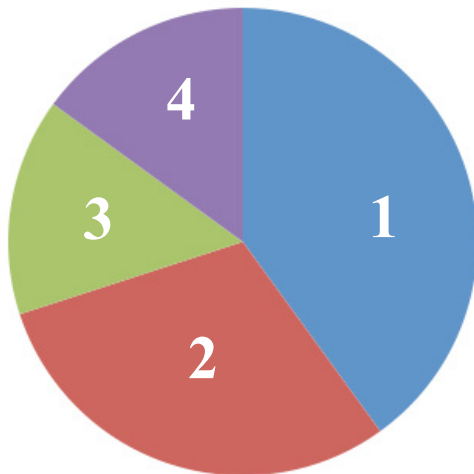The cost of treating one diabetic foot ulcer has been estimated to be Rs 30000-40000 [6].

Considering the pathophysiology of chronic nonhealing wounds, the more widely recognized causative factors are

- (i) phenotypically altered and/or senescent mesenchymal cells that fill the dermis of the skin [10,11,12];
- (ii) significantly decreased local concentration, stability and bioavailability of growth factors; the extracellular matrix, impair tissue repair and suppress cell proliferation and angiogenesis [13,14].

Several novel approaches for diabetic foot ulceration treatment have been proposed recently. These suggest the use of bone marrow stem cells [17], platelet-derived wound healing factors [18], fibrin glue [19] or bone marrow-impregnated collagen matrix

[20]. Each of these approaches has been reported to increase the response time of healing chronic wounds. But, as the wound environment is dynamic and requires the presence of all ‘ contributing components ’, it is unlikely that one type of treatment alone can bring a wound to complete closure [21,22].



- 1) Bone Marrow regenerate components of blood, and non-hematopoietic stem cells
- 2) Platelets Platelets have been used as a source for cytokines
- 3) Collegen matrix Collagen matrix acts as a scaffold for regeneration resulting in induction of angiogenesis and fibroplasia
- 4) Fibrin glue provides an important temporary extracellular matrix for wound healing

Optimum healing of a wound requires a well orchestrated integration of the complex biologic and molecular events of cell migration, proliferation, extracellular matrix deposition and remodeling [23]. In the present study we used bone marrow cells, concentrated in a small volume, using a recently described technique able to remove most of the RBC from bone marrow aspirate, thus achieving small volumes useful for cell therapy [24].

The bone marrow is an important source of hematopoietic stem cells, which regularly regenerate components of blood, and non-hematopoietic stem cells, including MSC which can be differentiated into several other cell types such as vascular endothelia, neurons, fibroblasts and skin keratinocytes. Considering the plasticity of bone marrow stem cells to produce new skin cells, it is conceivable that they may replenish lost cells during wound healing [25-26] Therefore, these cells are recognized as key players in tissue regeneration and, under appropriate conditions, it is considered that these cells can rejuvenate or rebuild tissue compartments [27].

Several studies suggest that bone marrow-derived stem cells may contribute to wound repair, either by self-proliferation and differentiation or by releasing regulatory cytokines. It has been proposed that stem/progenitor cells may be mobilized to leave the bone marrow, home to injured tissues and participate in repair and regeneration [28].

AIMS AND OBJECTIVES:

- To study the role of autologous bone marrow in healing chronic diabetic wound.
- To evaluate the cost effectiveness

MATERIAL & METHODS

Sample size: all the cases admitted between may 13 to oct. 15

Number of cases: 35

Type of study: Prospective Cohort Study

Duration of study: 2 years

Inclusion and Exclusion criteria.

Inclusion criteria.

- Patient with diabetes of the both sexes above age 18 years.



- Patient with diabetes for at least 3 months
- Wound size not more than 5*5 cms

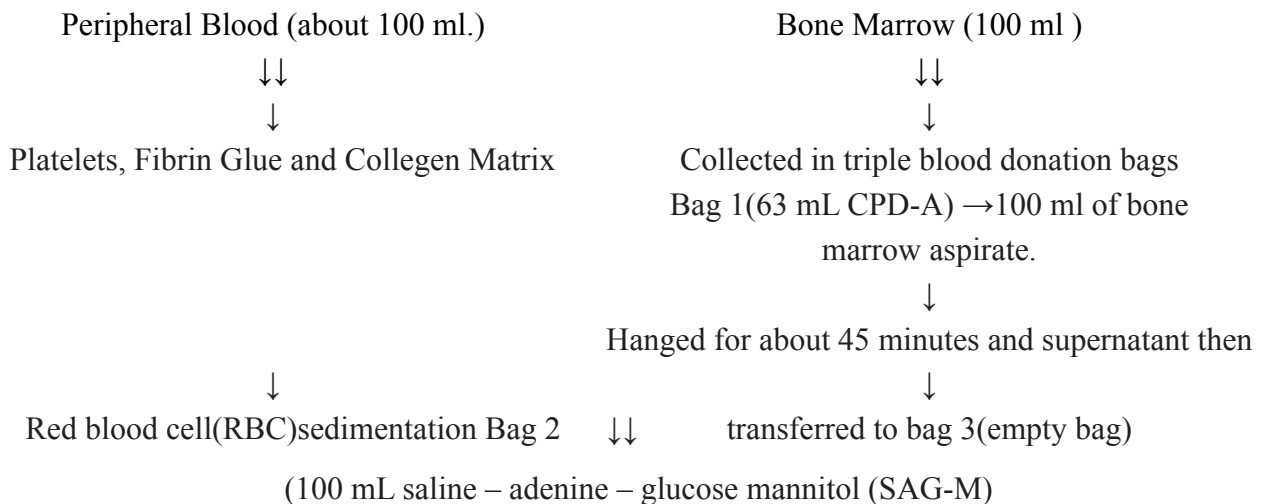
Exclusion criteria.

- Patient of more than 60 years of age and less than 18 years of age
- Women with Pregnancy
- Patient with Chronic elements such as cancer

Methods

The study protocol, informed-consent form and other study-related documents were reviewed and approved by Research Ethics Committee of B.J. GOVT. Medical college and Sasson General Hospital, Pune. All patients were willing to sign the informed consent form for the study. Two days before bone marrow aspiration, 100 mL peripheral blood were taken and platelets and fibrin glue were prepared according to standard procedures(17,18). Bone marrow was aspirated with bone marrow aspiration niddle under spinal anesthesia from the ileum, into commercial 450-mL triple blood donation bags, containing 63 mL CPD-A in bag 1 and 100 mL saline – adenine – glucose mannitol (SAG-M) in bag 2. Bag 1 was hung on a stand for 45 min to allow red blood cell (RBC) sedimentation. The supernatant was slowly expressed using a plasma extractor into bag 3 (an empty bag) and, as soon as red cells started to enter the connecting tube, the connecting tube was clamped temporarily. The connecting tube was temporarily clamped and bag 1 was shaken gently, hung for 45 min and the supernatant then transferred to bag 3. Bag 3 was centrifuged at 400 g for 12 min. After

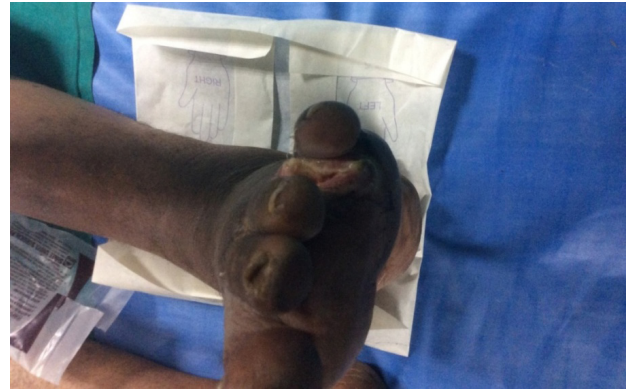completion of centrifugation, the supernatant plasma was transferred back to bag 2 using a plasma extractor and the cells were resuspended in about 8 mL of the remaining plasma. Prior to the application of BM-TNC, the area of necrotic and devitalized wound was debrided surgically until bleeding was recognized macroscopically. This allowed the bone marrow cells to come into contact with viable wound tissue. About 5 h after marrow aspiration, 5 mL of BM-TNC were implanted in the wound by 1.5-cm deep injections at various sites and the margin of the wound, using a 23-gauge needle. Following the injection, 2 mL BM-TNC were mixed with platelets and fi brin glue, applied to the wound and allowed to form a clot on the wound (fi brin matrix acts as a provisional scaffold for cells). Collagen matrix was then impregnated with 10 mL BM-TNC suspension (1 mL BM-TNC mixed with 9 mL serum) and placed on the fibrin clot. Finally, paraffi n gauze pads were placed over the wound and a bolster of rolled gauze pads placed over the paraffi n gauze. This dressing was then wrapped with rolled gauze. After 3 days, the entire dressing was removed and the wound irrigated with Normal Saline solution. The wound was then covered again with gauzes as described above, and each day the entire dressing was removed and irrigated with Normal Saline solution. The wound was closely observed for 6 weeks for the formation of granulation tissue and closure. BATES-JENSEN WOUND ASSESSMENT TOOL was used to asses the wound and accordingly scored.



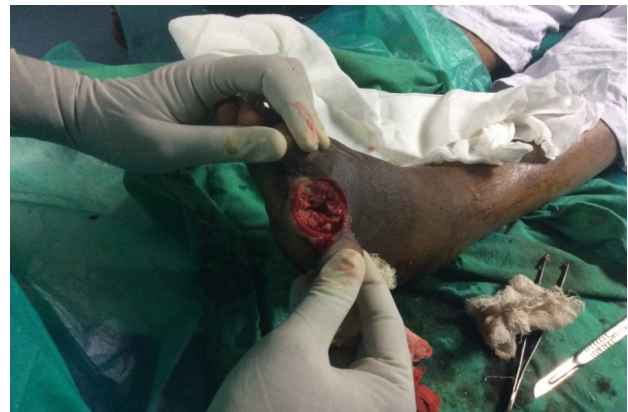Results and Conclusion

We have studied total number of 35 case. The GraphPad Instant statistical package (GraphPad Software Inc.) was used for statistical analysis. The level of statistical significance was set to $P < 0.05$. Wounds of 3 patients were completely closed after 6 weeks (BWAT Score 13). Wounds of 31 patients significantly reduced in the size ($p < 0.05$). One patient did not respond to the treatment ($p > 0.05$).

- The systemic and local treatment with BM-MSCs on diabetic wounds improved collagen levels in the wound bed. These growth factors (BM-MNC, Platelet, Fibrin glue, and collagen matrix) contribute to the repair, the regeneration, and the neovascularization in the diabetic wound. Non-healing diabetic ulcers that were treated successfully with a combination of bone marrow stem cells, platelets, fibrin glue and collagen matrix.
- The healing has been rapid in first three weeks and once the momentum has been gained the wound slowly progress towards complete healing.
- Patients with good diabetes control has better wound healing than patients with poorly diabetes control.
- The main benefit of the treatment presented here is that the procedure, because it is autologous, is very cost effective compared with current commercial wound care products. Strategic measures to improve overall health must focus on all the following aspects- good glucose control, detection and treatment of diabetic complications, patient education as well as specialised foot care. In the long run, a holistic approach like this is certain to be cost-effective. It becomes apparent that in this economically productive age group if the patient loses his limb then it is not just only economic loss to the nation but also a social burden.



Wound on day 1



Wound after 6th week

REFERENCES

1. Kleopatra Alexiadou and John Doupis Management of Diabetic Foot Ulcers PMID: PMC3508111
2. Abbott CA, Carrington AL, Ashe H, North-West Diabetes Foot Care Study et al. The North-West Diabetes Foot Care Study: incidence of, and risk factors for, new diabetic foot ulceration in a community-based patient cohort. *Diabet Med.* 2002;19:377–384. doi: 10.1046/j.1464-5491.2002.00698.x. [PubMed] [Cross Ref]
3. Centers for Disease Control and Prevention Lower extremity disease among persons aged ≥ 40 years with and without diabetes—United States, 1999–2002. *MMWR Morb Mortal Wkly Rep.* 2005;54:1158–1160. [PubMed]
4. Lauterbach S, Kostev K, Kohlmann T. Prevalence of diabetic foot syndrome and its risk factors in the UK. *J Wound Care.* 2010;19:333–337. [PubMed]
5. Viswanathan V. The diabetic foot: perspectives from Chennai, South India. *Int J Low Extrem Wounds.* 2007 Mar; 6(1):34-6.
6. Fard AS, Esmaelzadeh M, Larijani B. Assessment and treatment of diabetic foot ulcer. *Int J Clin Pract.* 2007;61:1931 – 8.



7. Brod M. Quality of life issues in patients with diabetes and lower extremity ulcers: patients and care givers. *Qual Life Res.* 1998;7:365 – 72.
8. Singh N, Armstrong DG, Lipsky BA. Preventing foot ulcer in patients with diabetes. *JAMA.* 2005;293:217 – 28.
9. Center for Disease Control and Prevention. National Diabetes Fact Sheet. National Estimates on Diabetes, 2000 – 2001. Center for Disease Control and Prevention, Atlanta, GA. <http://www.cdc.gov/diabetes/pubs/estimates.htm>. Accessed 18 November 2003.
10. Mendez MV, Stanley A, Phillips T, Murphy M, Menzoian JO, Park HY. Fibroblasts cultured from distal lower extremities in patients with venous reflux display cellular characteristics of senescence. *J Vasc Surg.* 1998;28:1040 – 50.
11. Raffetto JD, Mendez MV, Phillips TJ, Park HY, Menzoian JO. The effect of passage number on fibroblast cellular senescence in patients with chronic venous insufficiency with and without ulcer. *Am J Surg.* 1999;178:107 – 12.
12. Vande Berg JS, Rudolf R, Holland C, Haywood-Reid PL. Fibroblast senescence in pressure ulcers. *Wound Repair Regen.* 1998;6:38 – 49.
13. Trengove NJ, Stacey MC, MacAuley S, Bennett N, Gibson J, Burslem F, et al. Analysis of the acute and chronic wound environments: the role of proteases and their inhibitors. *Wound Repair Regen.* 1999;7:442 – 52.
14. Harding KG, Morris HL, Patel GK. Science, medicine and the future: healing chronic wounds. *Br Med J.* 2002;324:160 – 3.
15. Falanga V, Sabolinski M. A bilayered living skin construct (APLIGRAF) accelerates complete closure of hard-to-heal venous ulcers. *Wound Repair Regen.* 1999;7:201 – 7.
16. Badiavas EV, Falanga V. Treatment of chronic wounds with bone marrow-derived cells. *Arch Dermatol.* 2003;139:510 – 16.
17. Knighton DR, Ciresi KF, Fiegel VD, Austin LL, Butler EL. Classification and treatment of chronic nonhealing wounds. Successful treatment with autologous platelet-derived wound healing factors (PDWHF). *Ann Surg.* 1986;204:322 – 30.
19. Laurens N, Koolwijk P, de Maat MPM. Fibrin structure and wound healing. *J Thromb Haemost.* 2006;4:932 – 9.
20. Ichioka S, Kouraba S, Sekiya N, Ohura N, Nakatsuka T. Bone marrow-impregnated collagen matrix for wound healing: experimental evaluation in a microcirculatory model of angiogenesis, and clinical experience. *Br J Plast Surg.* 2005;58: 1124 – 30.
21. Rogers LC, Bevilacqua NJ, Armstrong DG. The use of marrow-derived stem cells to accelerate healing in chronic wounds. *Int Wound J.* 2008;5:20 – 5.
22. Humpert PM, Bartsch U, Konrade I, Hammes HP, Morcos M, Kasper M, et al. Locally applied mononuclear bone marrow cells restore angiogenesis and promote wound healing in a type 2 diabetic patient. *Exp Clin Endocrinol Diabetes.* 2005; 113:538 – 40.
23. Harding KG, Morris HL, Patel GK. Science, medicine and the future: healing chronic wounds. *Br Med J.* 2002;324:160 – 3.
24. Koliakos G, Alamdari DH, Tsagias N, Kouzi-Koliakos K, Michaloudi E, Karagiannis V. A novel high-yield volumereduction method for the cryopreservation of UC blood units. *Cytotherapy.* 2007;9:654 – 9
25. Krause DS, Theise ND, Collector MI, Henegariu O, Hwang S, Gardner R, et al. Multi-organ, multi-lineage engraftment by a single bone marrow-derived stem cell. *Cell.* 2001;105: 369 – 77.
26. Pittenger MF, Mackay AM, Beck SC, Jaiswal RK, Douglas R, Mosca JD, et al. Multilineage potential of adult human mesenchymal stem cells. *Science.* 1999;284:143 – 7.
27. Falanga V. Wound healing and its impairment in the diabetic foot. *Lancet.* 2003;366:1736 – 43.
28. Lorenz HP, Longaker MT. *Wounds: Biology, Pathology, and Management.* Stanford: Stanford University Medical Center; 2003. p. 77 – 88.

(ENDNOTES)

- 1 Prof and head of unit, Dept of Surgery, B.J. Govt. Medical College, and Sasson General Hospital, Pune(M.S)
- 2 Associate Professor, Dept of Surgery, B.J. Govt. Medical College, and Sasson General Hospital, Pune(M.S)
- 3 Resident JR 3, Dept of Surgery, B.J. Govt. Medical College, and Sasson General Hospital, Pune(M.S)
- 4 Resident JR 3, Dept of Surgery, B.J. Govt. Medical College, and Sasson General Hospital, Pune(M.S)