



Serum enzyme and histological studies of albino rat treated with ethanol/potash extract of *Sorghum bicolor* leaf sheath.

Ogunka-Nnoka C.U¹, Uwakwe A.A² and Nwachoko N.C^{1*}

¹Department of Chemistry, Rivers State University of Science and Technology, Port Harcourt, Nigeria.

²Department of Biochemistry, University of Port Harcourt, Choba, Nigeria

*blessedconfidence@yahoo.com

Abstract

The effect of ethanol/potash extract of the leaf sheath of *Sorghum bicolor* on the histology and serum enzymes was investigated using wistar albino rat placed in four groups of five rats each. The following quantities: 1000, 2000 and 3000mg of the extract was administered orally to the albino rats per kg body weight, while 0.5ml of 0.9% normal saline solution served as control to the fourth group. The rats were dissected after 14 days. Results for Alanine Transaminase (ALT), Aspartate Transaminase (AST) and Alkaline phosphatase (ALP) ranges as follows: 30-46 U/L, 07/137 U/L and 38-130U/L respectively. The high values of these liver enzymes (ALT, AST and ALP) relative to control values are indicative of severe intra hepatic cell damage. Histopathological examination also, revealed lesion or alteration in the morphological features of the liver and kidney in all the animals. This sample used in the management of anaemia has been observed in rats under the conditions of this study to be toxic to both the liver and the kidney.

Keyword: *Sorghum bicolor*, Ethanol/potash, Serum enzyme, Histological, Albino rat.

Introduction

In the last 2 to 3 decades, there has been renewed interest into research and utilization of medicinal plants, particularly, flora of the tropical rain forest (Sutejarto, 1996). In Nigeria today, there is an upsurge in the acceptance and utilization of these herbal medicine partly because of scientific support for some of their medicinal uses, and because of the belief that "Green medicine" is cheap, safe, more dependable and accessible than the costly conventional medicine (Parker & Chanda, 2006). Most part of the plant can be considered as herb including leaves, roots, seeds, leaf sheath, bark and sometimes pericarp of other portions.

Sorghum bicolor commonly called guinea corn is a short-term perennial plant and the species can grow in arid soils and withstand prolong drought. The leaves are broad and coarse similar to those of corn but shorter and wider (Bukantis, 1980). Sorghum is a major food crop in Africa and India and an important

livestock feed in America, Europe and Japan (Dogget, 1988).

Sorghum bicolor has a variety of uses. It is grown for grains, forage, syrup and sugar. Grain sorghum is a staple cereal in hot dry tropic. The medicinal properties of *sorghum bicolor* cannot be over emphasized as the root is used for malaria in Southern Rhodesia, the seed also for the treatment of breast disease, the stem for swelling treatment, while the sorghum leaf sheath has functioned therapeutically as a remedy against anaemia by traditional medicine healers. (Ogwumike, 2002). In Nigeria, the leaf sheath is commonly used by the Yorubas and Hausa, and is administered orally after extraction with water, ethanol or a mixture of ethanol and potash. It has been reported that dyes from sorghum bicolor leaf sheath may be Carcinogenic (Owolagba *et al.*, 2009, Avwioro *et al.*, 2009). Ogunmike (2002) in a haematological study conducted on albino rats supported the traditional use of *S.bicolor* as a

remedy for anaemia. Aviwioro et al. (2006) also reported that crude ethanolic extract of *S.bicolor* was used to stain red blood cells, collagen and muscle fiber; the resultant effect was that the dye might be apigenindin nature.

Potash, a powdery salt used primarily in fertilizer is known as boost the ethanolic extraction of the *Sorghum bicolor*. It is for this reason that the local consumers prefer taken it in combination with potash. However, there has been no scientific proof of the effect of this combination on human health. Therefore, the objective of this study is to evaluate the toxicity effect of this ethanol/potash extract of *Sorghum bicolor* leaf sheath on serum enzymes, liver and kidney of wistar albino rat.

Materials and methods

Collection of materials

Twenty male and female wistar albino rats weighting 125-160g were obtained from the animal house of the Department of Biochemistry, University of Port Harcourt, Choba, and Rivers State Nigeria. They were kept in rat cages in four groups of five each, and fed with dry pellet feed and water, *ad libitum*. All test animals were acclimated to their environment for two weeks before experiment begun. The leaf sheaths of sorghum bicolor were bought from the herb sellers at Mile 3 Market, Port Harcourt, and Rivers State. A Plant taxonomist in the Department of Biology, Rivers State University of Science and technology, Port Harcourt, identified the leaf sheaths. The air-dried leaf sheath was oven dried at 60°C for 18 hrs and subsequently grounded into powder. Five hundred gram of the powdered leaf sheath was exhaustively extracted with 500ml ethanol mixed with 0.5g of potash (WHO, 1996). The extract was concentrated in vacuum; the concentrated product is in a semi-solid form. It is then evaporated to dryness at 60°C for 1hr: The weight of the dried extract was 13.28g, thus giving a percentage yield of 2.66 of the starting sample. A fresh solution was prepared from the concentrated residue on each day of extract administration.

The dried extract was administered at 0.5% per kg body weight in doses of 1000, 2000 and 3000mg/kg body weight over a period of 14 days. The group 4 rats served as the control and received equivalent quantity of normal saline. Serum enzymes, liver and kidney were used to assess the effect of the various doses of the extract in the rats following sub acute administration (Sandabe *et al.*, 2005).

Blood and tissue collection

The rats were sacrificed after 4 days. Blood samples were collected into ethylene diamine tetra acetic (EDTA) acid treated sample bottles and was used for the determination of Serum Alanine Amino Transferase (ALT). Aspartate Aminotransferase (AST) and Alkaline Phosphatase (ALP) using standard procedures (Reitman & Frankel, 1957). Tissue samples of liver and kidney were harvested for histopathological examination.

Chemical analysis

Determination of serum alanine aminotransferase and Aspartate amino transferase (AST) were measured calorimetrically at 546µm using the proceeding described by Reitman and Frankel (1957). Commercial kits (Randox Reitman and Frankel ALT/AST level 2 control. Cat: No. SC 2643) were used for the manufacturer's instructions.

Tissue histopathology examination

The liver and kidney tissues were analyzed at the Histology Department of University of Port Harcourt Teaching Hospital, Rivers State, Nigeria.

Statistical analysis

The results are presented as mean \pm standards deviation. Significant ($P < 0.05$) differences between means were compared using ANOVA (Wahua, 1999).

Result

Serum Enzymes

Results obtained for serum liver enzymes in normal male and female albino rat treated with a mixture of ethanol/potash extract of sorghum bicolor leaf sheath are presented in Table 1. This extract increase all the serum enzyme studied. Values for ALT, AST and ALP

Ranged 33.2-46.6 u/L, 107-2 137.7 U/L and 38.5-130.1 U/L respectively. The increase was dose-dependent. Significant differences ($p \leq 0.05$) were observed at dose level of 3000mg/kg body weight for ALT and AST. While ALP values were significantly ($P \leq 0.05$) different at the various dose levels. Results of Serum enzymes for the tested animals were significantly different when compare to the control.

Histopathology examination

Histopathology of the liver and kidney Figures 1-8 below shows the morphology of the albino rat liver and kidney at different dose levels. The liver of the animals that were treated with 1000mg/kg body weight (Fig. 1) showed some distortion with mild lymphocytic cellular infiltration in the lumen of the blood vessels. The liver of the rats treated with 2000 and 3000mg/kg (Fig. 2 &3) extract dose had severe congestion showing ballooning degeneration, while the liver of the control rat showed intact structure (Fig. 4).

The kidney of the test animals were also distorted at the different doses compared with the control. The kidney of the rat treated with 1000mg/kg extract (Fig. 5) showed hemorrhage in the cortex adjacent to a Bowmans's Capsule while the kidney of rats treated with 2000mg/kg extract (Fig. 6) showed thickening of the glomeruli and interstitium. Rats treated with 3000mg/kg (Fig. 7) extract dose showed a more severe thickening of the tubules and vessels, the control however had its kidney intact (Fig. 8).

Discussion

Wistar albino rats, induced with ethanol/potash extract of *Sorghum bicolor* leaf sheath showed elevated levels of indicators of liver function AST and ALT. the increase appear to be extremely significant ($P \leq 0.05$) especially at 3000mg/kg body weight. It is known that these enzymes (ALT, AST & ALP) are mainly found in the liver in high concentration (although ALP also may be found in bone) and whenever the enzymes are found in high amount in the serum, it signifies

that the liver has problem (Owolagbe *et al.*, 2009, Abdulrahman *et al.*, 2007).

An elevated ALT is a sensible clinical indicator of hepatocellular injury (Tietz, 1994). The elevation of levels of alkaline phosphatase (ALP) as observed in this present study may be an indication of either liver problem or bone disease, since the two main sources of ALP are liver and bone. The high values of the activity of these enzymes relative to control values are indicative of severe intra-hepatic cell damage due to the compound administered. Aviwiwo *et al.*, (2006), using crude ethanol extract of sorghum bicolor leaf sheath to stain red blood cells, collagen and muscle fibers indicated that the dye may be apigeninidin. However, result from oral administration of the aqueous extract up to a concentration of 1500mg/kg did not show any adverse reaction, while rats that received 2500mg/kg and above died because of congestion and inflammation (Owolagba *et al.*, 2009).

Histopathological study showed that oral administration of the extract to rat at various doses appears to have adversely affected the liver and kidneys. The pathological changes observed in these two organs also appear to be dose dependent. The presence of pathological lesions in the liver and kidney may not be surprising since the kidney is the primary organ of the excretion while the liver is the main organ of biotransformation in the body. So, it is possible that the two organs may have been exposed to the toxic substances present in the extract. The above study appear to be in agreement with the observations of Abdulrahan *et al.*, (2007) and Jovanoic *et al.*, (1991). They reported on kidney and liver lesion on rats treated with aqueous root bark extract of *vitex doniana* and rats fed with feeds containing anti-Nutritive factors such as saponins and tannins. Increased sodium creatinine and urea levels have been reported (Ogunka-Nnoka *et al.*, 2012) when rats were treated with this extract for 14 days. Our report still confirms the reason for the organ Liaison observed.

Table 1. Effects of ethanol/potash extract of Sorghum bicolor leaf sheath on some serum enzymes (ALT, AST, ALP) in albino rats

Extract dose (ml/kg b.w)	ALT (U/L)	AST (U/L)	ALP (U/L)
1000 (group 1)	33.2 ^b ±3.0	120.5 ^b ±4.4	77.6 ^c ±3.6
2000 (group 2)	38.2 ^b ±2.1	125.4 ^b ±3.0	92.4 ^b ±1.3
3000 (group 3)	46.6 ^a ±1.4	137.7 ^a ±9.2	130.1 ^a ±2.0
Control (group 4)	30.4 ^c ±2.2	107.2 ^c ±1	38.5 ^d ±2.1

Values are Mean±SD of five replicate determinations. Means in the same column not followed by the same superscript differ significantly (p≤0.05).

Fig.1. Liver of rats exposed to 1000mg/kg, showing distortion.



Fig.2. Liver of rats exposed to 2000mg/kg of extract for 14 days

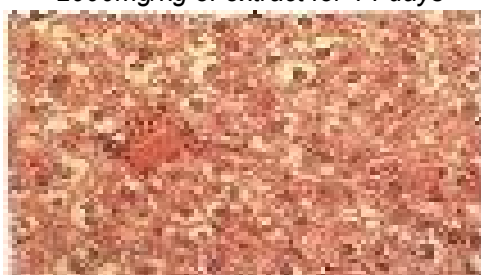

Fig.3. Liver of rats exposed to 3000mg/kg of extract showing ballooning degeneration



Fig.4. Liver of the control rat showed intact structure



Fig. 5. The kidney of the rat treated with 1000mg/kg extract



Fig.6. showed hemorrhage in the cortex adjacent to a Bowmans's Capsule while the kidney of rats treated with 2000mg/kg extract

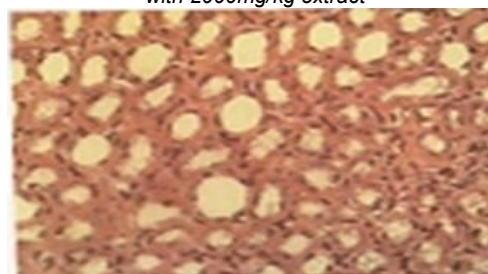


Fig. 7. Rats treated with 3000mg/kg extract dose showed a more severe thickening of the tubules and vessels

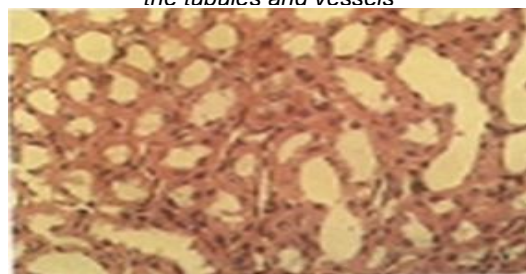
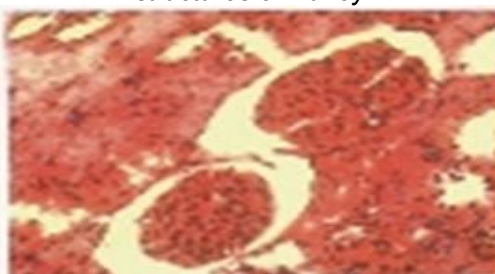


Fig.8. showing control intact structures of kidney



Our findings also agree with the theory of target organ toxicity by Heywood (1981), since metabolism of environmental chemicals take place mostly in the liver, while excretion occurs through kidneys (Clarke and Clarke, 1977; Parke, 1982). This medicinal plants used in the management of anemia has been prove to be toxic to both the liver and the kidney under the conditions of this study.

References

1. Abdulrahman FI, Onyeyili PA, Sanni S and Ogugbuaja VO (2007) Toxic effect of aqueous root-bark extract of *Vitex doniana* on liver and kidney functions. International Journal of Biological chemistry, I: 184-185.
2. Avwioro OG, Aloamarka CP, Olabampe OB and Oduola T (2006) Collagen and Muscle stain obtained from *Sorghum bicolor*. Scand. J. Clin. Lab. Invest. 66, 161-168.
3. Arwioro OG, Owoloagba GK, Anibor E, Bankole JK , Oduola T, Adeosun GO and Aloamarka CP (2009). Biochemical observations in wistar rats fed with the histological dye extract from *S.bicolor*. Int J. Med. Sci. 1(10), 464-466.
4. Bukantist R (1980) Energy Inputs in *Sorghum* production. In: Pimeritel, D (ed) Bocaraton, F.L. The encyclopedia of medicinal plants. London, Dorling Kinderstey Ltd.
5. Clark EGC and Clark ML (1977) Veterinary Toxicology, 2nd edn. Bailliere Tindall, NY. 10.
6. Dogget H (1988) Sorghum. Published by Halow: 2nd edn. Longman Scientific and Technical Tropical Agriculture series. International Development Research centre, Canada.
7. Heywood R (1981) Target organ toxicity. *Toxicol. Lett.* 8, 349-358.
8. Ogunmike OO (2002) Hemopoietic effect of aqueous extract of the leaf sheath of *sorghum bicolor* in albino rats. *African J. Biochemical Res.* 5, 69-71.
9. Owolagba GK, Avwioro OG, Oduola T, Adeosun OG, Enaowho TN, Wilson JJ and Ajumobi KO (2009) Histological observation of 24hrs oral administration of the extract of *S. bicolor* on albino Rat. *J. Cell Animal Biol.* 3(1), 001-003.
10. Parke DV (1982) The handbook of environmental chemistry. Spinger Verlag, Berlin.141-178.
11. Parker J and Chanda S (2006) In vitro Antimicrobial activities of Extract of *Launarea procumbens* Roxb (Labiatae), *vitis vinifera* L. (vitaceae) and *cyprus rotundus* L. (cyperaceae). African journal of ethnopharmacology 51,1-5.
12. Sandabe UK, Onyeyili PA and Chibuzo GA (2005) Prolonged administration of aqueous extract of *Ficus sycomonis* stem bark on haematological and some biochemical values in rats. *Sahu. J. Vet. Sci.* 1, 61-63.
13. Sutejarto DD (1996) Biodiversity, prospect and benefit sharing: perspective from the field. *J.of Ethnopharmacology.* 51,1-5.
14. Wahua TAT (1999) Applied Statistics for Scientific Studies. African press, Aba, Nigeria. 168-180.
15. WHO (1996) W.H.O. Guidelines for the Assessment of Herbal medicines. WHO expert committee on specification for pharmaceutical preparations. Technical Report series. No. 863 Geneva.