

Efficacy of dynamic brace on idiopathic spasmodic torticollis: A case study

Smita Nayak ^{*1}, Rajesh Kumar Das ²

^{*1} *Department of Prosthetics and Orthotics, National Institute for the Orthopedically Handicapped, B.T Road, Bon-Hooghly, Kolkata-700090, India.*

² *Prosthetist and Orthotist in Endolite India Ltd, B.P.O, Swami Vivekananda National Institute of Rehabilitation Training & Research, Olatpur, Bairoi, Cuttack, 754010, India.*
smitank7@gmail.com ^{*1}, rkdas.bpo@gmail.com ²

Abstract

Background: Idiopathic Spasmodic torticollis is an extremely painful disorder with an unknown etiology. Usually treated by static braces, in which restriction of movement is the major problem.

Methods: Dynamic brace was fitted to an 8 years boy presented with torticollis and gradual incremental forces were given by the turn buckle kit and kept under observation.

Result: Follow up was done after 3 months and assessed by the TWSTR scale. Result showed a marked reduction in symptoms.

Conclusion: A dynamic brace was an effective one for the treatment of Idiopathic Spasmodic Scoliosis.

Key words: Idiopathic spasmodic Torticollis, Dynamic brace, TWSTR scale, Turn buckle, Static brace

1. Introduction

The term torticollis is defined as wryneck or stiff neck. Contraction often results due to spasmodic condition of neck muscle, chiefly those supplied by the spinal accessory nerve; the head is drawn to one side & usually rotated however chin faces to other side [1]. This posture may be a result of muscular, skeletal, neurological, or visual conditions. Spasmodic torticollis is an extremely painful disorder causing the neck to involuntarily turn to the left, right, upwards, and/or downwards [2]. It has been reported that the incidence rate of spasmodic torticollis is at least 1.2 per 100,000 person years [3] and a prevalence rate of 57 per one million [4]. Conservative treatment and management of torticollis is generally accepted as the first treatment of choice. Surgery should only be considered when conservative treatment has failed, in spasmodic torticollis patient should be treated conservatively first [5, 6]. Though Botulinium toxin injection is one of the most recent forms of non-conservative treatment for spasmodic torticollis [7,8] major side effects of Botulinium include dysphagia, dystonia, paralysis of vocal cord & weakness of the neck muscle not to be neglected [8, 9]. The prime aim of the conservative treatment was readily implicated through a force framing network is known as Torticollis bracing system. Though various systems were available for the treatment of spasmodic Torticollis but less number of studies was showing the effectiveness of brace which is required for clinical purpose to provide a better management. So, the aim of this study is an attempt to check the effectiveness of dynamic brace on Idiopathic Spasmodic Torticollis.

2. Methods

The subject was an 8 yr old boy presented with a painful deviated neck reported in Department of Prosthetic and Orthotic OPD of Swami Vivekananda National institute Of Rehabilitation Training & Research. Subject was referred for orthopedic review. Then he diagnosed with idiopathic spasmodic torticollis (Fig 1a). Radiograph was taken on that day to rule out any bony involvement but, problem found only in muscular structure not in bone. Posture checked by marking pencil & measuring tape method (Fig 1b). Distance & level of PSIS & Scapula from midline found near about same in both side. Winginging of scapula present which was not the problem & it

considered normal for this age group. But occipital protuberance distance was vary (rt >lt). Subject also assessed by TWSTRS (Toronto western spasmodic torticollis rating scale) found total score 43/87, severity score 18/35, disability score 13/32 & pain score 12/20. Physical therapy was immediate commenced to provide rehabilitation. After therapeutic intervention the maintenance of stabilization remained an issue. In the supervision of senior orthotist a custom made Dynamic torticollis brace was fabricated to provide support, maintain & correct the deformity in a gradual manner. The subject was fitted with dynamic adjustable brace. This design promotes successive corrective forces through an incremental graduated system following the mechanism of Turn Buckle. The dynamic brace consists of Shoulder cap with chest strap, Temporo-mandibular support, Adjustable Chin support, Head control attachment & Turn buckle kit (Fig 2a-2c). The donning and doffing, Care and maintenance and wearing schedule of the brace were explained to the mother clearly. Post TWSTRS data was taken after three month of intervention.

Figure 1a. Anterior view of the subject with spasmodic torticollis

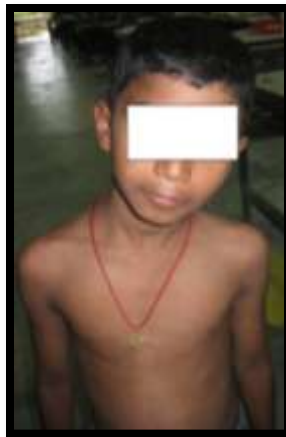

Figure 1b: Posterior view of the subject

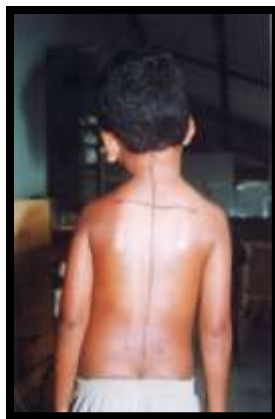
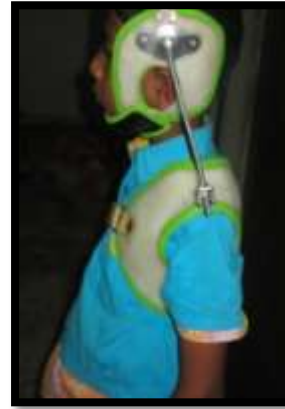
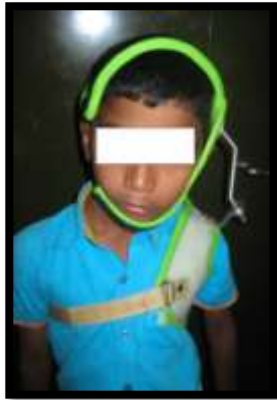Figure 2a. Turn buckle kit, 8" rod with wing nut, modified base plate retainer, base plate with rod



Figure 2b. Anterior view of subject with brace

Figure 2c. Lateral View of subject with brace



3. Result and Discussion

The score of TWSTRS at the time of reporting was 43/87, for severity 18/35, disability 13/32 and pain score 12/20. After three month of follow up it found reduction in overall score 28/87 and for [severity, disability and pain 12/35, 10/32 and 6/20 respectively (Table 1). Comparison of before and after score for all the parameters were shown in (Fig. 3).

Figure 3. Comparison of score of TWSTR without and with brace

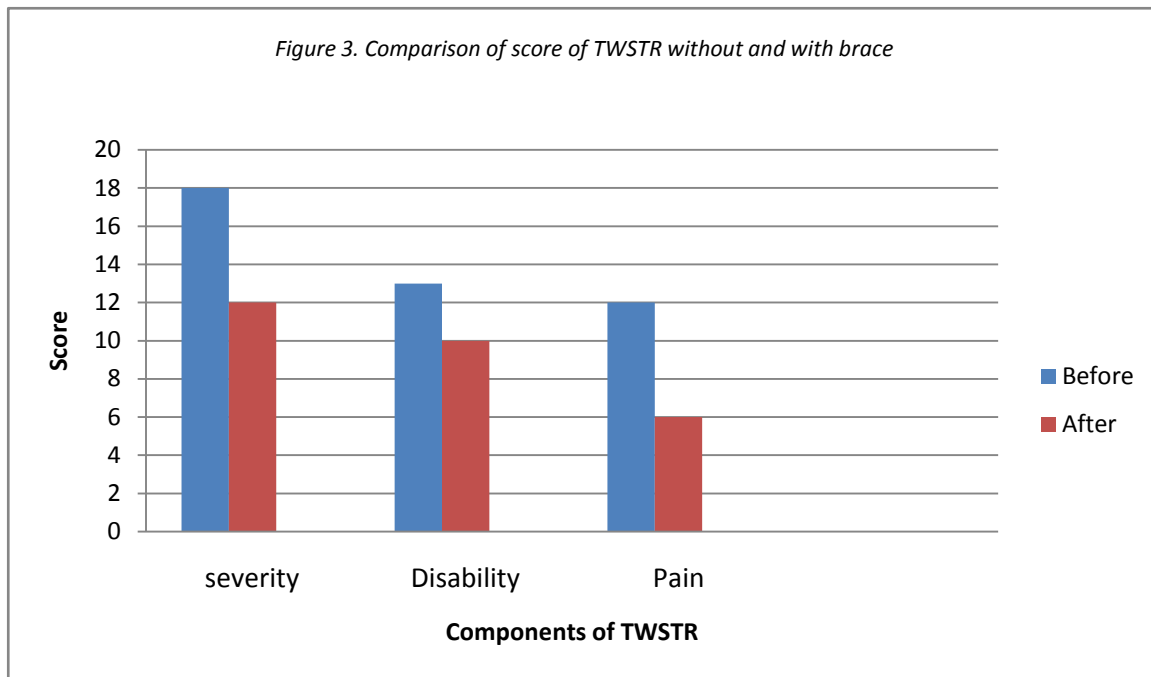


Table 1. Score of severity, disability and pain without and with brace

Parameters of TWSTRS	Severity	Disability	Pain	Total score (%)
Score without brace	18	13	12	49.4
Score with brace	12	10	6	32.1

#: Percentage of score from the total score of 87.

The natural history of torticollis is Idiopathic. In the treatment of torticollis, the use and design of cervical orthoses is varied depending on the severity of the deformity, surgical intervention, if any, and continued follow-up care relative to the initial success towards its resolution. Some of cases patient not willing to do the surgery these cases physical therapy along with braces are the treatment of choice. Previous literature described the Orthosis like collar; post devices are maximum immobilizing Orthosis. Static devices mostly restrict neck motions & maintain head in a constant position. Present study gives emphasis on dynamic positioning of head and it supported by Col. H.C. and Mathur 1985 [10] and Martin RM and Fish DE 2008 [11] they reported that a dynamic bracing in case of torticollis became very effective and this offer excellent control of the head in all planes, especially for rotational positioning. The result of present study found that TWSTRS total score reduced 35% from before. Significant reduction found in pain score (50%), 33% & 24% reduction found in severity and disability score respectively. The present study supports the recent principle of control the deformity by applying dynamic distraction force in incremental manner. Though this study found an effective result in the dynamic brace on TWSTR scale but it requires further evaluation on more subjects with quantitative measures.

4. Conclusion

The study concluded that dynamic torticollis brace is the effective one for the treatment of Idiopathic Spasmodic Torticollis. Use of dynamic brace with therapeutic intervention markedly reduces the symptoms. But, it was proposed that this form of intervention required further evaluation & investigation

5. Acknowledgement

We would like to thanks the subject and his family member for their active participation.

6. References

1. Stedman, Thomas Lathrop. Torticollis: Stedman's Medical Dictionary. 23 edn. 1976.
2. A. Richter, W. Loscher. Pathology of idiopathic dystonia: findings from genetic animal models. *Progress in Neurobiology*. 1998; 54 (6), 633–677.
3. DW. Claypool, DD. Duane. Epidemiology and outcome of cervical dystonia (spasmodic torticollis) in Rochester. *Movement Disorders*. 1995; 10(5), 608- 614.
4. T. Warner, L. Camfield, CD. Marsden, AH. Nemeth, N. Hyman, D. Harley, J. Wissel, W. Poewe, RJ .Marttila, H. Erjanti, P. Burbaud, A. Lagueny, C. Kamm, T. Gasser, D. Franz, E. Castelon-Konkiewitz, Trender, A. Ceballos-Baumann, A. Nebe, B. Freudenberg, A. Bentivoglio, E. Cassetta, A. Albanese, A. Curra, L. Vacca, A. Berardelli, J. Ferreira, C. Sampaio, V. Passao, F. Marti, E. Tolosa, L. Claveria, J. Duarte, Y. Ben-Shlomo, A. Newton, Eu. The epidemiological study of dystonia in Europe (ESDE) collaborative. A prevalence study of primary dystonia in eight European countries. *Journal of Neurology*. 2000; 247 (10), 787–792.
5. M. Webb. Acute torticollis. *Post Graduate Medicine*. 1987; 82(3), 121-126.
6. C . Jorgenson, H.Porphysis. Idiopathic spasmodic torticollis. *Journal of Neurosurgical Nursing*. 1985; 17(3), 169-174.
7. M. Jahanshahi, C.D. Marsden. Treatment for torticollis. *Journal of Neurology, Neurosurgery & Psychiatry*. 1989; 52(10), 1212-1220.
8. R. Stell, PD. Thompson, CD. Marsden. Botolinum toxin in spasmodic torticollis. *Journal of Neurology, Neurosurgery & Psychiatry*. 1988; 51: 920-923.
9. C.E. Koay. Pharyngeal paralysis due to botolinum toxin injection. *Journal of Laryngology & Otology*. 1989; 103, 698-699.
10. H.C. Col, Mathur. Role of cephalo cervico thoracic dynamic splint in management of congenital torticollis. *Orthotics and Prosthetics*. 1985; 38(4), 54-57.
11. RM. Martin, DE. Fish. Scapular winging: anatomical review, diagnosis, and treatments. *Current Reviews in Musculoskeletal Medicine*. 2008; 1 (1), 1–11.

The Publication fee is defrayed by Indian Society for Education and Environment (www.iseeadyar.org)

Cite this article as:

Smita Nayak, Rajesh Kumar Das. Efficacy of dynamic brace on idiopathic spasmodic torticollis: A case study. *Indian Journal of Medicine and Healthcare*. 2014; 3 (2), 337-340.