

**Wound healing property of aqueous extract of seed and outer layer of *Momordica charantia* L. on albino rats**Rajaram Prashanthi<sup>1\*</sup>, Natarajan Mohan<sup>2</sup> and Ganesan Vijayan Siva<sup>1</sup><sup>1</sup>Department of Biotechnology; <sup>2</sup>C.A.S.in Botany, University of Madras, Maraimalai (Guindy) Campus, Chennai-600025, India.

prashanthirajarambt@gmail.com\*; mohannatarajan@hotmail.com

**Abstract**

*Momordica charantia* is a tropical vine bearing edible fruit which is among the most bitter of all vegetables. Several reports indicate that the extracts obtained from the fruits of *M. charantia* have significant wound healing activity and antidiabetic property. Aqueous extract is routinely used as traditional medicine to treat various ailments. In this report, the effect of aqueous extract of the seed and outer layer of the fruits of *M. charantia* on wound healing of albino rats is presented. Wounded albino rats treated with seed and outer layer extracts recovered faster than the untreated control animals. After 4 days, there was 20% reduction of the wound area on control animals while 45.75% and 47.5% reduction noticed on animals treated with seed and outer layer of the fruits of *M. charantia*, respectively. Further, animals treated with extracts showed significant increase in protein, hydroxyproline, hexosamine and uronic acid contents compared with respective controls. These data permit the observation that the extracts of *M. charantia* promote wound healing in animal model and indicated that the outer layer extract of *M. charantia* has potential use to treat different types of wounds in human beings too.

**Keywords:** *Momordica charantia*, hydroxyproline, hexosamine, Uronic acid, wound contraction, Rat model.**Introduction**

Bitter gourd (*Momordica charantia* L) is a tropical and subtropical vine of the family Cucurbitaceae, widely grown for its edible fruit, which is among the most bitter of all vegetables. Significant wound healing activity was observed in animals treated with benzene-and ethanol extract of leaves of *M. charantia* compared with untreated animals (Sharma *et al.*, 2009a,b). Prasad *et al.*, (2006) have evaluated the fruit powder of *M. charantia* in the form of an ointment (10% w/w dried powder in simple ointment base), for wound-healing potential in an excision, incision and dead space wound model in rats and found to reduce the healing time compared to control. Teoh *et al.*, (2009) have studied the effect of topical extract of bitter gourd on wound healing in nondiabetic rats and in rats with diabetes induced by streptozotocin. Their results showed that administration of *M. charantia* extract improves and accelerates the process of wound healing in diabetic animals. This fruit has also shown the ability to enhance cells' uptake of glucose, to promote insulin release, and to potentiate the effect of insulin (Jayasooriya *et al.*, 2000).

*M. charantia* contains biologically active chemicals such as momorcharins, momordenol, momordicin, momordicins, momordicin, momordin, momordolol, charantin, charine, cryptoxanthin, cucurbitins, cucurbitacins, cucurbitanes, cycloartenols, diosgenin, elaeostearic acids, erythrodiol, galacturonic acids, gentisic acid, goyaglycosides, goyasaponins, multiflorenol. The fruit juice and/or a leaf tea is employed for diabetes, colic, sores and wounds, infections, worms and parasites, as an emmenagogue, and for measles, hepatitis, and fevers.

Here we studied the effect of seeds and outer layer of the fruits of *M. charantia* on wound healing in albino rats.

**Materials and methods**

The animal care and handling were carried out according to the guidelines set by the WHO, Geneva, and the INSA (Indian National Science Academy, New Delhi). Albino rats (*Rattus norvegicus*) of 8 to 10 week old, weighing 120 to 150g were selected from an inbred colony maintained under the controlled conditions of temperature (23 ±2° C), humidity (50±5%) and light (10 and 14 hours of light and dark, respectively). The animals were divided into three groups, each group containing three rats namely: 1) animals which received bitter gourd seed extract 2) Animals which received bitter gourd outer layer extract and 3) animals which did not receive any treatment (Control).

**Sample preparation**

Dried powder (5 g) of seeds and outer layer of bitter gourd was extracted with 100 ml of sterile distilled water kept on rotary shaker for 24 h. Thereafter, it was filtered through Whatmann No 1 filter paper and centrifuged at 5000g for 15 min. The supernatant was collected and filtered through Millipore filter. It was stored at 4° C in air tight bottles (Parekh *et al.*, 2005).

**Production of full-thickness skin wounds**

The animals were anesthetized using diethyl ether before creation of wound and decontaminated by wiping the whole body with sterile disinfectant. The fur of the dorsum (below the rib cage) of each animal was removed and the cleared dorsal surface of skin was marked with a sterile square (2 X 2 centimeter) stencil. A full-thickness wound was created by excising the skin flap in an aseptic environment using sterile scissors and forceps. Each wounded animal was housed in a separate sterile polypropylene cage. Grouped animals were treated with 100 µl of bitter gourd seed and outer layer extract. Control animals received sterile distilled water instead of the

extract. Sterile gauze was tied on the wound to prevent the animals from licking them. The extract was reapplied over alternate day and the wound size was calculated every fourth day and the granulation tissue was also removed every fourth day for biochemical analysis.

#### *Measurement of wound contraction*

The progression of wound healing was judged by the periodic assessment of the contraction of excision wounds. Wound contraction was monitored by tracing the outline of the wound on tracing sheet and then using graph sheet to calculate the area of the wound size. All animals in each group were monitored until complete healing of wounds occurred and the day at which each wound healed was recorded. Mean of all healed wounds was determined.

#### *Estimation of hydroxyproline (Woessner, 1961)*

Known amount of tissue (50 mg) was taken in glass tubes and 4ml of 6N HCl was added to each tube to hydrolyse the tissue sample. The glass tubes were sealed and were incubated for 22 hours. The tubes are then opened and the contents are decanted into a china dish. HCl was then removed by evaporation and the residue was dissolved in water and made up to known volume (10ml) using a standard flask. A series of standards were prepared containing 20-200  $\mu\text{g}$  of hydroxyproline with a final volume of 2ml.

One millilitre of the hydrolysed tissue samples was used to estimate the contents of hydroxyproline. Hydroxyproline oxidation was initiated by adding 1ml of chloramine-T to each tube in a predetermined sequence. The tube content were mixed by shaking a few minutes and allowed to stand for 20min at room temperature. Chloramine-T was then destroyed by adding 1ml of perchloric acid to each tube in the same order as before. The contents were mixed and allowed to stand for 5min. Finally 1ml of p-Dimethyl aminobenzaldehyde solution was added and the mixture was shaken well. Tubes were placed in a 60°C water bath for 20min and then cooled in tap water for 5min. The colour developed was read spectrophotometrically at 557nm. Hydroxyproline value was determined from the standard curve.

The procedure is based on alkaline hydrolysis of the tissue homogenate and subsequent determination of the free hydroxyproline for the production of a pyrole. The addition of Ehrlich's reagent resulted in the formation of a chromophore that can be measured at 557 nm. Optimal assay conditions were determined using tissue homogenate and purified acid soluble collagen along with standard hydroxyproline. Critical parameters such as the amount of chloramine-T, sodium hydroxide, p-dimethylaminobenzaldehyde, pH of the reaction buffer, and length of oxidation time were observed to obtain satisfactory results.

#### *Estimation of hexosamine (Rondle & Morgan, 1955)*

Tissue samples (50 mg) were hydrolysed with 2N HCL (5 ml) at 100°C for 6 hrs. Hydrochloric acid was then

removed by evaporation, then the residue was dissolved in water and made up to a known volume (10ml) using a standard flask.

The method was based on the observation that in alkaline solution at 100 °C, the amino sugars react with acetyl acetone to form chromogenic material which gives a chromophore or chromophores on treatment in acid solution with ethanolic p-dimethyl amino benzaldehyde. The method described is suitable for the estimation only for free amino sugars where a determination is carried to ascertain the amino sugar content of a polysaccharide or other material of high molecular weight. Any amino sugar units remaining as oligosaccharide or substituted amino sugar gives less color per unit weight of amino sugar than that found for free amino sugar. Therefore it is essential that the hydrolysis of granulation tissue is done without destruction of the amino sugar.

Aliquots containing 10-50 mg hexosamine were treated with 1ml of freshly prepared 2% acetyl acetone in 0.5M sodium carbonate in capped tubes and kept in boiling water bath for 15min. After cooling in tap water, 5 ml of 95% ethanol and 1ml of Ehrlich's reagent (1.33% Dimethyl amino benzaldehyde in 1:1 ethanol: concentrated hydrochloric acid mixture) were added and mixed thoroughly. The purple red colour developed was read after 30 min at 530 nm. Water blank and standard glucosamine solution of various concentrations were also treated similarly to get a standard curve.

#### *Estimation of total protein*

Total protein content of the granular tissue was determined by following Bradford (1976) method.

#### *Estimation of uronic acid*

Uronic acid was extracted from granulation tissue as described by Schiller *et al.*, (1961). Tissue was briefly digested with papain (10 mg/g wet wt. of tissue) in 0.5 M acetate buffer, pH 5.5, containing 0.005 M cysteine and 0.005 M disodium salt of EDTA at 65°C for 24 h. An aliquot of this digest was used for the estimation of uronic acid by the spectrophotometric method of Bitter and Muir (1962).

#### *Tensile strength*

The tensile strength of the samples was tested using Universal Testing Machine -Instron 450I. Speed was set at 100 mm per minute and the force applied was 5 Newton.

The jaws of the tensile tester were set 20 mm, apart for the samples. The test specimen was clamped in the jaws and the machine was run at the rate of 100±2 mm/min. until the specimens tore apart. The highest load reached was recorded while the sample is subjected to breaking. The distance between the jaws when rupture of the test specimen occurred was noted.

#### *Histology*

Histological studies of wounded tissues provide accurate diagnosis of level of healing of the wound. The tissues were mechanically and biochemically stabilized in

Table 1. Wound size reduction at different stages in albino rats.

Sample	Day 0		Day 4		Day 8		Day 12		Day 16	
	Wound area(cm <sup>2</sup> )	% Reduction	Wound area(cm <sup>2</sup> )	% Reduction	Wound Area(cm <sup>2</sup> )	% Reduction	Wound area (cm <sup>2</sup> )	% Reduction	Wound area(cm <sup>2</sup> )	% Reduction
Control	4	0	3.20	20	1.50	62	0.7	72.5	0.56	86
Bitter gourd seed	4	0	2.25	43.75	1.20	70	0.3	92.5	0.06	98.5
Outer layer	4	0	2.10	47.5	1.00	75	0.2	95	0.02	99.5

neutral buffered formalin (10% formaldehyde in phosphate buffered saline (PSB) pH 7.0). Then the samples were immersed in multiple baths of progressively more concentrated ethanol to dehydrate the tissue, followed by a clearing agent, such as xylene or HistoClear and finally immersed in hot molten paraffin wax (impregnation). During this 12 to 16 hour process, paraffin wax replaces the xylene. The tissue is then sectioned into very thin (2-8 micrometer) sections using a microtome. These sections are then placed on a glass slide for staining. The staining method involves application of the basic dye hematoxylin, which colors basophilic structures with blue-purple blue, and alcohol-based acidic eosin Y, which colors eosinophilic structures as bright pink.

## Results and discussion

### Wound contraction

Wound contraction can be defined as the centripetal movement of the edges of a full-thickness wound in order to facilitate closure of the defect (Peacock, 1984). The data obtained on wound size reduction (Table 1) revealed that bitter gourd outer layer and seed extracts induced early healing compared to control. The faster wound contraction rate of the extracts may be due to stimulation of interleukin-8, an inflammatory  $\alpha$ -chemokine and various growth factors or inhibition of proinflammatory markers like IL  $1\beta$  and TNF- $\alpha$  which affect the function and recruitment of various inflammatory cells, fibroblasts and keratinocytes (Robson, 1991). As growth factors and cytokines have important roles in wound healing, further studies required on *M. charantia* extracts on these factors to assess their effect in granulation tissues and wound healing.

### Protein and hydroxyproline level

Protein and hydroxyproline levels were estimated from the granulation tissue taken on every fourth day till 16<sup>th</sup> day. Total protein content of the granulation tissue of the wound treated with bitter gourd outer layer extract

was found to be higher than treated with bitter gourd seed. For any metabolic reaction to take place, protein plays a crucial role. Any protein can affect either the intra cellular mechanism of tropocollagen synthesis or the extra cellular mechanism of precipitation and organization of collagen fibers and thus will alter the evolutionary repair process.

Hydroxyproline content of the granulation tissue of the wound treated with bitter gourd outer layer was found to be higher than seed extract and control. Wound healing process is characterized by increased hydroxyproline levels in the granulation tissue. Our results conform with the early reports (Novikova *et al.*, 1988, Evans *et al.*, 1993, Shivananda Nayak, 2006; Shivananda Nayak *et al.*, 2006; Shenoy Ashok *et al.*, 2011)

Hydroxyproline is a major component of the protein collagen. Hydroxyproline and proline play key roles for collagen stability. The collagen composed of amino acid (hydroxyproline) is the major component of extra cellular tissue, which gives strength and support. Breakdown of collagen liberates free hydroxyproline and its peptides. Measurement of the hydroxyproline could be used as an index for collagen turnover. The data on protein and hydroxyproline content (Table 2) showed that the hydroxyproline content of the granulation tissue of the animals treated with aqueous extracts of seed and outer layer of *M. charantia* was significantly increased when compared to the control.

### Hexosamine and uronic acid level

The hexosamine and uronic acid content (Table 3) of the granular tissues of animals treated with *M. charantia* extracts and untreated (control).

Hexosamine content of the granulation tissue of the wound treated with bitter gourd outer layer extract and seed extract was found to be higher than control. Our result is in conformity with the early report by Shivananda

Table 2. Protein and hydroxyl proline level in granulation tissues

Sample	Day 0		Day 4		Day 8		Day 12		Day 16	
	Protein	Hydroxy proline	Protein	Hydroxy proline	Protein	Hydroxy proline	Protein	Hydroxy proline	Protein	Hydroxy proline
Control*	2200 ±16	17 ±1.5	2757 ±16	19 ±1.3	4890 ±18	25 ±1.2	5915 ±21	60 ±1.8	6115 ±19	76 ±1.2
Bitter gourd seed*	2240 ±14	24 ±1.2	4580 ±15	28 ±1.1	6165 ±23	31 ±1.4	6840 ±21	76 ±1.9	6945 ±21	98 ±1.6
Outer layer*	2210 ±14	58 ±2.4	6815 ±19.5	76 ±2.2	7870 ±21	142 ±2.6	8545 ±26	211 ±2.5	8640 ±28	216 ±2.2

(\* Values are expressed in  $\mu\text{g}/100\text{ mg}$  of granulation tissue)

Table 3. Hexosamine and uronic acid level

Sample	Day 0		Day 4		Day 8		Day 12		Day 16	
	Hexosamine	Uronic acid	Hexosamine	Uronic acid	Hexosamine	Uronic acid	Hexosamine	Uronic acid	Hexosamine	Uronic acid
Control*	118 ±1.8	79 ±1.2	125 ±1.2	100 ±2.3	386 ±3.2	134 ±1.3	422 ±3.8	150 ±1.4	401 ±3.8	147 ±1.3
Bitter gourd seed*	127 ±2.1	80 ±1.3	280 ±2.6	176 ±2.6	618 ±5.4	198 ±1.4	714 ±4.8	248 ±1.8	690 ±5.2	212 ±1.9
Outer layer*	120 ±2.1	76 ±1.2	396 ±3.4	198 ±2.7	824 ±6.6	226 ±2.0	882 ±6.1	274 ±2.4	810 ±6.8	222 ±2.2

(\* Values are expressed in  $\mu\text{g}/100\text{ mg}$  of granulation tissue)

Nayak (2006) where it was found that hexosamine content doubled when aqueous extract was applied topically on a wounded rat. Moreover, Hexosamine, which is a ground substratum for collagen synthesis, is known to increase during early stages of wound healing and decrease thereafter (Chitra *et al.*, 1998a,b). A similar trend has been observed in the present study in hexosamine content of granular tissues. By correlating hexosamine content it can be judged how fast the wound heals. It is important to note that hexosamine content will increase during wound healing process and decreases when maturation and remodelling phase is attained.

We observed an increase in uronic acid content in treated animals than in control. An increase in uronic acid level in treated animals as compared to control animals represents an enhanced synthesis of glycosaminoglycans which is similar to earlier observations (Chitra *et al.*, 1998a).

#### Tensile strength

Tensile strength is the maximum force a material under testing can withstand per unit area. In our studies, healed skin tissues of animals treated with *M. charantia*

Table 4. Tensile strength of healed skin of albino rat

Sample	Load at maximum load (N)	Displacement at Max. Load (mm)	Stress at Max. Load (MPa)	Percentage at Max. Load (%)
Control	12.065	5.384	0.316	26.923
Bitter gourd outer layer	14.295	8.313	0.447	41.563
Seed	12.810	7.334	0.400	36.670

extract have shown significant tensile strength when compared to control animals (Table 4). Our result conforms with the earlier report by Agarwal *et al.* (2009) in which they have reported that the increase in hydroxyl proline content of the granulation tissue in treated animal indicates the presence of higher collagen content and its turnover leads to rapid healing with concurrent increase in the tensile strength of the treated wounds. An increase in tensile strength of the treated wounds may be due to the increase in collagen concentration and stabilization of the fibers. The collagen molecules synthesized are laid down at the wound site and become cross linked to form fibers. Tensile strength is acquired from both remodeling of collagen and the formation of stable intra and inter-molecular crosslink (Udupa *et al.*, 2009).

Fig.1. Granulation tissue of albino rats (control) obtained on the 12<sup>th</sup> day. Epidermal proliferations were seen above the wound. Fibrosis inflammatory cells were seen.

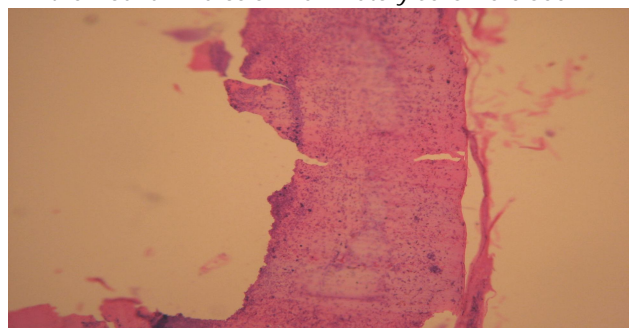
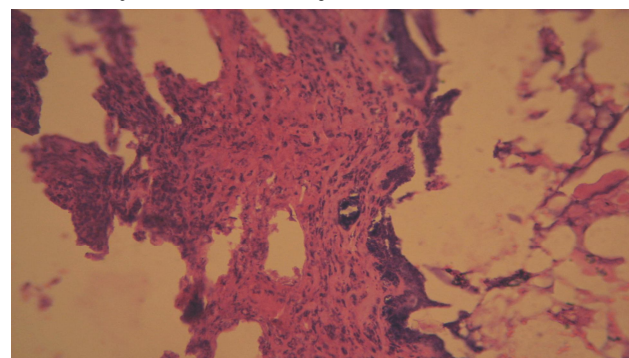


Fig.2. Granulation tissue of albino rats treated with bitter gourd seed extract on the 12<sup>th</sup> day. Fibrous bundle with adjacent inflammatory cells were observed.



#### Histological studies

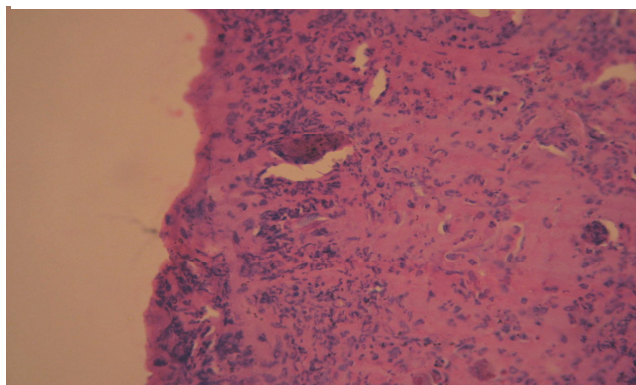
From histological studies, it was observed that the phases of wound healing occurred in a timely manner. The untreated (control) wound healed slowly when compared to the wounds treated with bitter gourd extracts. The granulation tissues of animals treated with *M. charantia* extracts showed larger number of inflammatory cells, and lesser collagen when compared with control animals (Fig.1-3).

#### Conclusion

Animals treated with the *M. charantia* extracts showed a significantly faster reduction in wound area compared to control. Further, animals treated with extracts showed significant increase in protein, hydroxyproline, hexosamine and uronic acid contents compared with respective controls. These data permit the

observation that the extracts of *M. charantia* promote wound healing in animal model and indicated that the outer layer extract of *M. charantia* can be used to treat different types of wounds in human beings too. The results presented in this report are preliminary in nature and at this stage; it is difficult to say which component(s) of the extracts are responsible for this wound healing activity. However, further phytochemical studies are needed to isolate the active compound(s) responsible for these wound healing activities.

*Fig.3. Granulation tissue of albino rats treated with bitter gourd outer layer extract on the 12<sup>th</sup> day. Regenerating with epithelium, collagenization and less inflammatory cells were observed compared with bitter gourd seed.*



## References

- Agarwal PK, Singh A, Gaurav K, Shalini Goel, Khanna HD and Goel RK (2009) Evaluation of wound healing activity of extracts of plantain banana (*Musa sapientum* var. *paradisiaca*) in rats. *Indian J. Exptl. Biol.* 47, 32-40.
- Bitter T and Muir HM (1962) A modified uronic acid carbazole reaction. *Anal. Biochem.* 4, 330-334.
- Bradford MM (1976) A rapid and sensitive method for the quantitation of microgram quantities of protein utilizing the principle of protein-dye binding. *Anal. Biochem.* 72, 248-254.
- Chitra P, Sajithlal GB and Chandrakasan G (1998a) Influence of *Aloe vera* on the glucoaminoglycans in the matrix of healing dermal wounds in rats. *J. Ethnopharmacol.* 59,179-186.
- Chitra P, Sajithlal GB and Chandrakasan G (1998b) Influence of *Aloe vera* on the healing of dermal wounds in diabetic rats. *J. Ethnopharmacol.* 59,195-201.
- Evans DM, McAree K, Guyton DP, Hawkins N, and Stakleff K (1993) Dose dependency and wound healing aspects of the use of tissue plasminogen activator in the prevention of intra-abdominal adhesions. *Am J. Surg.* 165, 229-32.
- Jayasooriya AP, Sakono M, Yukizaki C, Kawano M, Yamamoto K, and Fukuda N (2000) Effects of *Momordica charantia* powder on serum glucose levels and various lipid parameters in rats fed with cholesterol-free and cholesterol-enriched diets. *J. Ethnopharmacol.* 72, 331-336.
- Novikova AN, Mamedov A, Egorova ND, Shekhter AB and Nikolaev AV (1988) Ascorbic acid and hydroxyproline levels in the serum and granulation tissue of rats with aseptic and infected wounds. *Bull. Eksp. Biol. Med.* 106, 355-358.
- Parekh J, Jadeja D and Chanda S (2005) Efficacy of aqueous and methanol extracts of some medicinal plants for potential antibacterial activity. *Turk J. Biol.* 29, 203-210.
- Peacock EE (1984) Contraction. In: *Wound Repair, Third Edition*. Philadelphia, PA, WB Saunders.
- Prasad V, Jain V, Girish D and Dorle AK (2006) Wound-healing property of *Momordica charantia* L. fruit powder. *J. Herb. Pharmacother.* 6,105-15.
- Robson MC (1991) Growth factors as wound healing agents. *Curr. Opin. Biotechnol.* 2, 863-867.
- Robson MC (2003) Cytokine manipulation of the wounds. *Clin. Plast. Surgery.* 30, 57-65.
- Rondle CJM and Morgan WTJ (1955) The determination of glucosamine and galactosamine. *Biochem J.* 61, 586-590.
- Schiller S, Slover G, Dorfman AA (1961) A method for the separation of acid mucopolysaccharides: Its application to the isolation of heparin from the skin of rats. *J. Biol. Chem.* 236, 983-987.
- Sharma S, Chandra Sharma M, Kohli DV and Chaturvedi SC (2009a) Formulation, evaluation, wound healing studies of benzene-95% and absolute ethanol extract of leaves. *J. Optoelectronics & Biomed. Materials.* 1,375-378.
- Sharma S, Sharma MC and Kohli DV (2009b) Wound healing activity of the ether-chloroform benzene-95% extract of *Momordica charantia* fruits in albino rats. *J. Optoelectronics & Biomed. Materials.* 1 (4), 389-392.
- Shenoy Ashok M, Shastry C. Shashidhar and Shetia Prakash (2011) Evaluation of wound healing property of *Heliotropium indicum* leaves. *Intl. Res. J. Pharmacy.* 2, 279-284.
- Shivananda Nayak B (2006) *Cecropia peltata* L (Cecropiaceae) has wound-healing potential: A preclinical study in a Sprague Dawley Rat model. *Intl. J. Lower Extremity Wounds.* 5, 20-26.
- Shivananda Nayak, Poorna Nalabothu, Steve, Sandiford, Vidyasagar Bhogadi and Andrew Adogwa (2006) Evaluation of wound healing activity of *Momordica charantia* L. extracts on rats. *BMC Complementary & Alternative Med.* 6,12.
- Teoh SL, Latiff AA and Das S (2009) The effect of topical extract of *Momordica charantia* L. (bitter gourd) on wound healing in nondiabetic rats and in rats with diabetes induced by streptozotocin. *Clin. Exptl. Dermatol.* 34, 815-22.
- Udupa AL, Kulkarni DL and Udupa SL (2009) Effects of *Tridax procumbans* extracts on wound healing. *Intl. J. Pharmacognosy.* 33, 37-41.
- Woessner JF (1961) The determination of hydroxyproline in tissue and protein samples containing small proportions of this amino acid. *Archiv. Biochem. Biophys.* 93, 440-447.