



## Hepatoprotective effect of amukkarac curanam in acetaminophen intoxicated rats

A. Saraswathy\*, R.V. Pradeep Chandran, S. Nandini Devi

Captain Srinivasa Murti Drug Research Institute for Ayurveda (CCRAS), Arumbakkam, Chennai – 600 206, India

### Abstract

**Objective:** The hepatoprotective action of Amukkarac curanam (AC), a widely used Siddha medicine was evaluated using acetaminophen-induced hepatic damage in rats. **Material and methods:** AC was administered orally at a dose of 500 mg/kg body weight for 7 days. Serum levels of transaminase (AST, ALT), alkaline phosphate (ALP), bilirubin, Total protein (TP) and albumin (Alb) were used as the biochemical markers of hepatotoxicity. Liver thiobarbituric acid reactive substances and histopathological studies were also done to confirm the biochemical changes. **Results and Discussion:** The results of the study indicate that pretreatment with AC significantly reversed the increased levels of serum marker enzymes such as AST, ALT, ALP and bilirubin, when compared to acetaminophen-induced group. The level of liver thiobarbituric acid reactive substances was also brought to near normal. AC has protected the liver from acetaminophen-induced damage. Probable mechanism of action is by protection against oxidative damage produced by acetaminophen.

**Keywords:** Acetaminophen, Amukkarac curanam, Marker enzymes, Thiobarbituric acid reactive substances, Histopathological studies.

### 1. Introduction

Amukkarac curanam (AC) is a popular drug in Siddha system of medicine containing amukkara root as the major ingredients. Amukkara is botanically equated to *Withania somnifera* Dunal [1]. It is used in treatment of colic, hiccup, tumours, chlorosis and spermatorrhoea. It is also used in rheumatic diseases, sexual insufficiency and insomnia. It is considered to be a general tonic and anabolic [1, 2]. Its preparation consists of 7 ingredients including amukkara root, all

powdered and mixed with sugar [1]. The present investigation has been designed to study the effect of amukkarac curanam on their biochemical parameters against acetaminophen-induced liver damage in rats.

### 2. Materials and Methods

#### 2.1 Preparation of Amukkarac curanam

Amukkarac curanam (AC) was prepared according to the method given in The Siddha Formulary of India [2].

\* Corresponding author  
Email: saraswathy20042000@yahoo.co.in

## 2.2 Reagents

All chemicals were of the high quality from BDH Chemicals and Sigma Aldrich Chemicals Co. Biochemicals were obtained from Merck Ecoline. All solutions were prepared in double-distilled deionized water.

### 2.2.1 Animal stock

Adult Male albino rats (150-220 g) of Wistar strain obtained from the Tamil Nadu University of Veterinary and Animal Science, Chennai, India were used. They were housed in clean polypropylene cages and fed with commercial pelleted red chow (Gold-Mohur, M/S Hindustan Lever Ltd, Mumbai, India) and water *ad libitum*. Before starting the experiment, permission from Institutional Animal Ethics Committee was obtained.

### 2.3 Experimental procedure

The AC/distilled water were given with the help of feeding cannula. A total of 18 animals were equally divided into 3 groups (n=6 in each group). Group 1, served as normal control, received distilled water. Group II received acetaminophen (640 mg/kg of body weight, orally) [3] administered 24 hours post-treatment of the last dose. Group III received AC (500 mg/kg of body weight, orally in distilled water) for 7 days and acetaminophen administered 24 hours post-treatment of the last dose. At the end of the treatment animals were sacrificed by cervical decapitation (after anaesthesia), 24 hours *ph* after the last dosage of drug or vehicle administration. The serum and liver (homogenized in 0.1 M Tris, *ph* adjusted to 7.4 with HCl) obtained from the animals were used for the estimation of the assessed parameters.

#### 2.3.1 Enzyme assays

The activities of serum hepatic marker enzymes namely aspartate aminotransferase (AST), alanine aminotransferase (ALT), alkaline

phosphatase (ALP), bilirubin were assayed in serum using was done by using commercially available kits from E. Merck in a E. Merck model 200 Semi autoanalyser. Similarly total protein (TP) and albumin (Alb) in serum were also estimated using E. Merck kits.

#### 2.3.2 Thiobarbituric acid reactive substances (TBARS)

The concentration of TBARS was measured in liver using the method of Ohkawa *et al.*, (1979) [4]. The concentration of TBARS was expressed as *n* moles of malondialdehyde per mg of protein using 1,1,3, 3-tetra-ethoxypropane as the standard.

### 2.4. Statistical analysis

Data were statistically evaluated using ANOVA, expressed as mean  $\pm$  S.E.M followed by Post Hoc Dunnett T3 multiple comparisons test using the 10 version of SPSS computer software. Results were considered as significant when  $P < 0.05$ .

## 3. Results

Rats treated with acetaminophen resulted in a significant hepatocellular damage as evident from a significant ( $P < 0.05$  and  $P < 0.001$ ) elevation in serum activities of AST, ALT, ALP and bilirubin concentration. A significant ( $P < 0.05$  and  $P < 0.001$ ) reduction in the levels of TP and Alb was also observed in the Group II acetaminophen-intoxicated rats as compared to Group I control rats (Table 1). Pretreatment with AC (Group III) retained the activities of these enzymes to near normal levels ( $P < 0.05$  and  $P < 0.001$ ) in serum as compared to (Group II) acetaminophen-intoxicated rats.

A significant ( $P < 0.001$ ) elevation of liver thiobarbituric acid reactive substances of acetaminophen treated group with concomitant increase in serum AST, ALT, ALP activity was observed as compared to Group I control rates

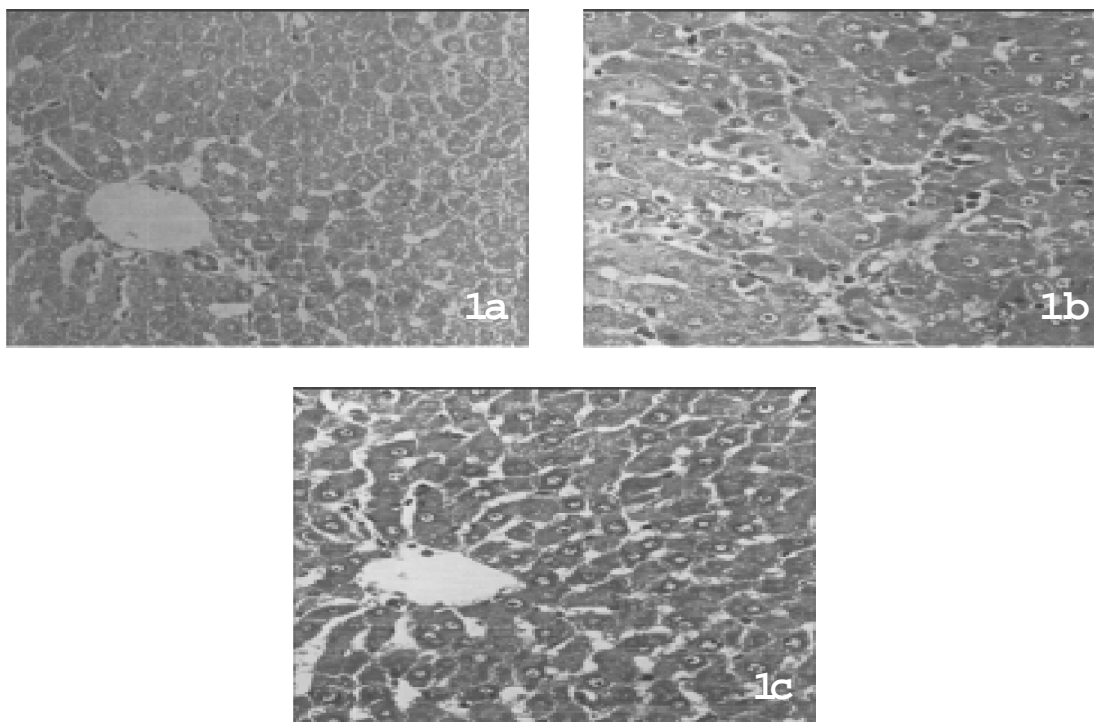
(Table 2). AC pretreatment (Group III) significantly reduced ( $P < 0.001$ ) the level of liver TBARS as compared to acetaminophen-intoxicated Group II rats.

Microscopic examination of liver tissue of Group I control rats (Fig. 1a) showed normal hepatic cells with well intact central vein and sinusoids and kupffer cells were normal. Liver tissue of Group II acetaminophen-intoxicated rats (Fig. 1b) showed drastic alterations in histoarchitecture with the formation of hepatoma eosinophilic nodules. Scattered microgranuloma with isolated hepatocellular necrosis and hyperchromatism caused by acetaminophen administration were also seen.

Pretreatment with AC Group III showed mild fatty and scattered vesicular degenerative changes in the hepatocytes around central vein (Fig. 1c).

## 5. Discussion

Therapeutic doses of acetaminophen does not produce pathological changes [3,5]. On the other hand, overdoses causes major hepatic lesions and even toxic fulminant hepatitis type with massive increase in transaminases and liver damage. The non-toxic therapeutic dose range in humans in between 10-25 mg/kg body weight [6]. During the bioactivation process, acetaminophen is converted into a free radical *N*-acetyl *p*-benzoquinonime-NAPQI by the



**Fig. 1:** Histological examination of liver tissue sections in control and experimental animals (Hematoxylin and Eosin, 100x). Section of liver tissue from (a) control rat showing normal architecture; (b) Acetaminophen-intoxicated rat showing degenerative changes, hepatoma eosinophilic nodules, scattered microgranuloma and fatty change; (c) AC pretreated rat reveals less cellular infiltration, showing uniform hepatocytes and the hepatoprotective effect are evident from reduced hepatic damage even after acetaminophen administration.

**Table 1.** Effect of Amukkarac Curanam on serum marker enzymes in control and experimental group of rat.

Treatment	AST ( $\mu$ mol of pyruvate liberated mg/protein/min.)	ALT ( $\mu$ mol of pyruvate liberated mg/protein/min.)	ALP ( $\mu$ mol of phenol liberated mg/protein/min.)	Bilirubin (mg/dL)	Total protein (g/dL)	Albumin (g/dL)
Control (Group I)	73.72 $\pm$ 3.25	22.69 $\pm$ 0.56	418.07 $\pm$ 53.87	1.00 $\pm$ 0.04	5.44 $\pm$ 0.28	4.58 $\pm$ 0.21
Acetaminophen (Group II)	263.54 $\pm$ 2.97 <sup>a</sup>	122.35 $\pm$ 4.31 <sup>a</sup>	806.57 $\pm$ 19.54 <sup>*</sup>	2.22 $\pm$ 0.15 <sup>*</sup>	2.61 $\pm$ 0.17 <sup>a</sup>	3.02 $\pm$ 0.21 <sup>*</sup>
AC + Acetaminophen (Group III)	125.06 $\pm$ 2.39 <sup>c</sup>	38.32 $\pm$ 3.77 <sup>c</sup>	503.16 $\pm$ 18.23 <sup>c</sup>	1.20 $\pm$ 0.04 <sup>b</sup>	4.95 $\pm$ 0.05 <sup>c</sup>	4.85 $\pm$ 0.04 <sup>b</sup>

AC = Amukkarac Curanam, *P* values: <sup>\*</sup>< 0.05 statistically significant when compared with Group I; <sup>a</sup><0.001 statistically significant when compared with Group I; <sup>b</sup>< 0.05 statistically significant when compared with Group II; <sup>c</sup>< 0.001 statistically significant when compared with Group II; n= 6.

cytochrome -P-450 enzyme system [7,8,5] which conjugates with glutathione SH to form glutathione-S-acetaminophen. Following acetaminophen toxicity, induction of cytochrome - P-450 or depletion of hepatic glutathione occurs and the reactive metabolite binds with cell proteins, producing toxic effects [9]. Thus it is evident that both the toxins cause liver damage by different modes and our results confirm that AC is able to safeguard the liver from both of these toxins, suggesting versatility in its hepatic protection.

Further, stimulation of hepatic regeneration [10], activation of the function of the reticuloendothelial system [11] or inhibition of protein biosynthesis [12] are some of the known mechanisms which can reduce the hepatic damage of acetaminophen.

In conclusion, it is observed that amukkarac curanam exhibited a significant hepatoprotective action through antioxidant and normalization of the marker enzyme, thereby preventing the leakage of enzymes from the cells into the blood and also by increasing the stability of membrane.

**Table 2.** Effect of Amukkarac curanam on liver thiobarbituric acid reactive substances in rats subjected to acetaminophen intoxication.

Treatment	TBARS (nmol of MDA/g of wet tissue/h)
Control (Group I)	4.40 $\pm$ 0.16
Acetaminophen (Group II)	11.94 $\pm$ 0.05 <sup>b</sup>
AC + Acetaminophen (Group III)	5.10 $\pm$ 0.03 <sup>c</sup>

AC = Amukkarac curanam,

*P* values: <sup>a</sup>< 0.01 statistically significant when compared with Group I; <sup>b</sup>< 0.001 statistically significant when compared with Group I;

<sup>c</sup>< 0.00 statistically significant when compared with Group II; n=6.

## 6. Acknowledgement

The authors wish to thank the Project Director, Tamil Nadu State AIDS Control Society (TANSACS), Chennai for financial support and Director CCRAS, AYUSH for providing laboratory facilities.

### References

1. Anonymous. (1992) *The Siddha Formulary of India*, Vol. I, Government of India Publication: New Delhi; 152,195.
2. Anonymous.(1993) *Formulary of Siddha Medicines*, 4th edn. IMPCOPS Publication Pvt, Ltd,: Chennai-40.
3. Janbaz KH, Gilani HA. (1995) *J. Ethnopharmacol.* 47:43-47.
4. Ohkawa H, Ohishi N, Yagi K. (1979) *Anal. Biochem.* 95: 351-358.
5. Gibson JD, Pumford NR, Samokyszyn VM, Hinson JA.(1996) *Chem. Res. Toxic.* 9;580-585.
6. Hinson JA, Pumford NR, Robert DW. (1995) *Drug Metab. Rev.* 27: 73-92.
7. Savides MC, Oehme FW. (1983) *J. Appl. Toxicol.* 3: 95-111.
8. Nelson SD. (1995) *Drug Metab. Rev.* 27: 147-177.
9. Mitchell JR, Jollow DJ, Potter WZ. Gillette JR, Brodie BB. (1973) *J. Pharmacol. Exp. Ther.* 187: 211-217.
10. Lesch R, Reutter W, Keppler D, Decker K. (1970) *Exp. Mol. Pathol.* 12: 58-69.
11. Gruen M, Liehr H, Gruen W, Rasenack U, Branswig D. (1974) *Acta Hepato Gastroenterol.* 21: 5-15.
12. Castro JA, Ferreyra EC, de Castro CR, de Fenos OM, Dias Gomes MI, Gram TE, Regan RL, and Guarina AM. (1977) *Toxicol. Appl. Pharmacol.* 41: 305-320.