

POPLITEAL SCIATIC AND SAPHENOUS NERVE BLOCK FOR ANKLE AND FOOT SURGERIES – A CASE SERIES

Authors Dr.Anand H. Kulkarni*
Dr.Sudhindra G. Kulkarni**
Dr.Ambareesha .M***

Summary

Combined popliteal and saphenous nerve blocks at the knee can offer a desirable and effective alternative to general and spinal anesthesia for ankle and foot surgery. However, it's a relatively underused technique. We present here five patients with severe co- morbid illnesses managed by the popliteal – sciatic and saphenous nerve block.

Key words

regional anesthesia, sciatic , common peroneal, saphenous nerve block, nerve stimulator

Introduction

Regional nerve blocks are based on the concept that pain is conveyed by nerve fibres, which are amenable to interruption anywhere along their pathway.¹ Popliteal fossa block was first described by Labat in 1923.² Sciatic nerve block in the popliteal fossa is an anesthetic technique well suited for operations below the knee.³ In addition, performing the saphenous nerve block provides anesthesia of the entire lower leg, thus permitting a greater variety of procedures to be performed as compared to ankle block.

Anatomy

The sciatic nerve divides into the tibial and common peroneal nerves, high in the popliteal fossa.⁴ The popliteal fossa is a diamond shaped fossa bounded laterally by the biceps femoris tendon and medially by the semi-tendinosus and semi- membranous tendons. Fig 1

Cephalad to the flexion crease of the knee, the popliteal artery is lateral to the semi-tendinosus tendon. The popliteal vein is lateral to the artery, and the tibial and common peroneal nerves (within a sheath) are just lateral to the vein and medial to the biceps tendon, 4-6 cm deep to the skin. The tibial nerve continues deep behind the gastrocnemius muscle, whereas the common peroneal nerve leaves the popliteal fossa by passing between the head and neck of the fibula to supply the lower leg.

*MD., DNB Assistant Professor

** Post Graduate

***MD., DA Prof and Head

Dept of Anesthesia,
Kasturba Medical College, Mangalore

Correspond to :

Dr. Anand H.Kulkarni
C 3-20, KMC Staff Quarters,
Lighthouse Hill Road,
Mangalore -575003.
Karnataka, India.
Tel- No : +919886281218
E-mail: kulkarni1616@rediffmail.com

Case Series

Five patients presented to us with diabetic ulcer of the foot extending above the ankle for surgical debridement, where ankle block was not feasible. Details of the patients are given in the table below.

Patient	Age	Sex	Co- existing illness	Other problems
1	62	M	ESRD; Hypertension IHD with MI 6 months back	S.Creat 8.9, INR 1.6, Na+ 126
2	45	M	Hypertension, IHD	chronic smoker widespread crepts + , ECG T wave inversion in V1-V3, ECHO→EF 35% with RWMA
3	54	F	Hypertension on multiple drugs , COPD	chronic smoker and alcoholic ; productive cough +; widespread crepts +; Pt not willing for spinal anesthesia.
4	75	M	Asthmatic; ESRD , IHD	ECHO→ EF 30% RWMA, tachypnea, basal crepts + INR 1.8
5	59	F	Hypertension; dilated cardiomyopathy;	Chronic alcoholic; INR 1.9, ECHO→ EF 28%, Grade IV Dyspnea +

EF: Ejection fraction INR: International Standardized Ratio ESRD: End Stage Renal Disease
MI: Myocardial Infarction IHD: Ischemic Heart Disease RWMA: Regional Wall Motion Abnormality

Due to the above reasons the patients were unfit for general anesthesia and neuraxial blockade. Thus we contemplated the popliteal and saphenous nerve block in these patients.

Technique⁵

Popliteal-sciatic nerve block

The patient was positioned prone and the outline of the popliteal fossa was identified proximal to the flexion crease of the knee. If not, the midline is identified. Two inches proximal to the crease, a skin wheal was raised.

A 2-inch, 22 gauge insulated stimulating needle connected to nerve stimulator was inserted 1 cm lateral to the pulse or in the midline if the pulse could not be felt, and advanced 2-4 cm and motor response was sought in the distal ankle

and foot. When motor response was still present on reducing the stimulation current to less than 0.5 mA indicating proximity to of the needle tip to the nerve, 25-30 ml of 0.25% bupivacaine was injected. It may be necessary to block the common peroneal nerve separately, if it branches above the popliteal fossa. Therefore, it was also separately blocked in all cases to ensure success of the block

Common peroneal nerve block

The common peroneal nerve is usually palpable sub- cutaneously at the junction of head and neck of fibula, just below the knee. At this point 8-10 ml of 0.25% bupivacaine was injected postero-inferior to the head of fibula.

Saphenous nerve block

Sub- cutaneously 8-10 ml of 0.25% bupivacaine was injected starting from tibial tuberosity and directed medially across the antero-medial surface of head of tibia.

The use of the nerve stimulator enhanced the success of the blockade for the sciatic nerve and anesthesia satisfactory to complete the procedure was achieved in all the patients, without the need of additional sedation or analgesia. No hematomas, infections or paraesthesia were seen in any of the patients.

Discussion

This case series indicates that block of the sciatic nerve and its terminal branches in the popliteal fossa can be used to provide anesthesia for surgical procedures involving ankle and foot. The technique is simple, it involves eliciting a motor response using nerve stimulator and then depositing the local anesthetic solution.⁶ Thus, placement of the local anesthetic solution in close proximity to the nerve trunk is assured.

Advantages over general anesthesia.⁷

1. Good choice in a patient unfit for general anesthesia
2. Better postoperative analgesia
3. Stable hemodynamics
4. No airway manipulation
5. Lower risk of deep vein thrombosis, respiratory depression
6. No postoperative nausea and vomiting
7. Less time in post-operative ward
8. Avoidance of narcotic related side effects

Advantages over neuraxial blockade

1. Site specific analgesia
2. Stable haemodynamics
3. No risk of post dural puncture headache
4. No danger of meningitis
5. No danger of extradural haematoma/ abscess
6. Advantageous in “back –prick” anxious patients

Conclusion

Popliteal-Sciatic and saphenous nerve block is an effective alternative to general anesthesia and neuraxial blockade for ankle and foot surgeries, especially in sick and moribund patients. But it is a relatively underused technique. With the availability of nerve stimulator and lately the ultrasound guidance this nerve block is likely to become a routine technique in our clinical practice.

References

- 1. Rorie DK , Byer DE , Nelson DO et al. Assessment of block of the sciatic nerve in the popliteal fossa. *Anesth. Analg*, 59; 371-376, 1980.**
- 2. Prithvi Raj P Popliteal fossa block. In: P Prithvi Raj . Textbook of Regional Anesthesia. Philadelphia : Churchill Livingstone, 2002:370-371.**
- 3. Vloka JD, Hadzic A, Koorn R, Thys: Supine approach to the sciatic nerve in the popliteal fossa. *Can journal of Anesthesia*, 43; 964-967,1996.**
- 4. Michael F Mulroy Popliteal fossa blockade. In: Paul G Barash, Bruce F Cullen, Robert Stoelting. *Clinical anesthesia Williams and Wilkins*, 2006:743.**
- 5. Edward Morgan Jr. Popliteal block. In Edward G Morgan Jr, Maged S Mikhail, Michael J Murray *Clinical Anesthesiology. Lange medical books*, 2006:350-352**
- 6. Brown DL. Popliteal block. In: Brown DL. *Atlas of Regional Anesthesia*. Philadelphia; W B Saunders, 1992 ;109-113.**
- 7. Zetlaoui PJ, Bouaziz H. Lateral approach to the sciatic nerve in the popliteal fossa. *Anesth. Analg*, 87; 79-82, 1998.**

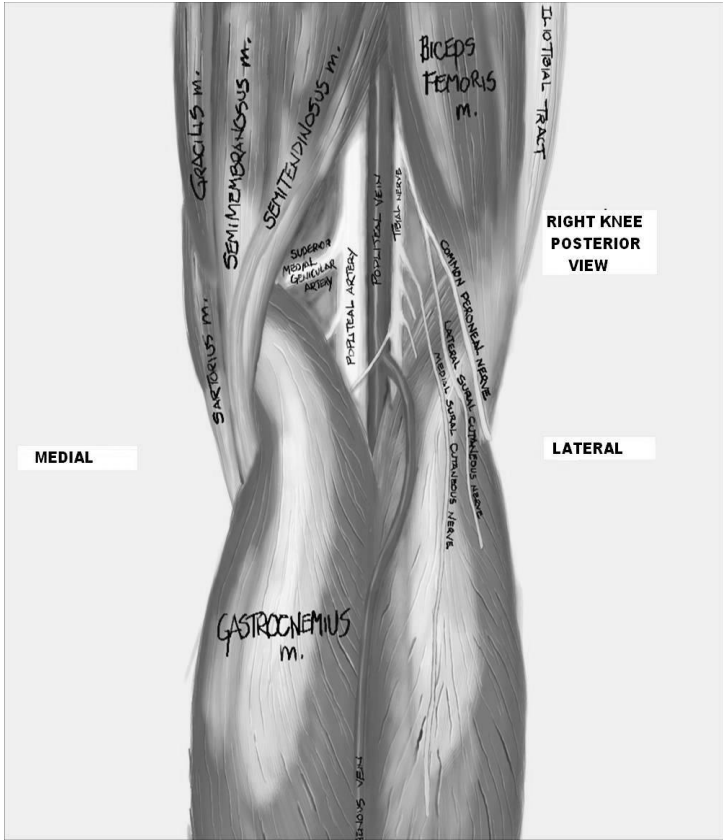


Fig 1