

Flexible Fibreoptic Bronchoscopy

S. Bala Bhaskar

Department of Anaesthesiology, Vijayanagar Institute of Medical Sciences (VIMS), Ballari - 583104, Karnataka, India; sbalabhaskar@gmail.com

Abstract

Among the various options available for difficult airway management, flexible fibreoptic bronchoscopy is still considered as the Gold Standard technique, even after the recent revolutionary inventions such as the supraglottic airway devices and the video laryngoscopes. The utility has expanded to involve combined use with these new devices also, complementing one another. Familiarity with the device and its components and training are very important for successful use. The patient cooperation, the techniques and drugs for airway blocks, role of continuous oxygenation, sedation, anticholinergics and positioning are some of the important considerations. It is mandatory for the endoscopist to follow a strict protocol in the operating room in terms of care and maintenance of this costly equipment.

Keywords: Anaesthesia Fibreoptic Intubation, Awake Fibreoptic, Difficult Airway, Intubation

1. Introduction

The first Fibre-Optic Bronchoscope (FOB) was designed and produced on the basis of specifications provided by Ikeda in 1966¹. Murphy P reported use of a flexible fibreoptic choledochoscope for nasotracheal intubation in 1967 on a patient with Still's disease². Fibreoptic bronchoscope (FOB) was used for nasotracheal intubation in patients with severe rheumatoid arthritis about 5 years later^{3,4}. Stiles and colleagues in 1972 reported fibreoptic endotracheal intubations, both oral and nasal⁵. FOB has been one of the most revolutionary inventions for airway management of patients.

2. The Parts of the Device

Fibreoptic laryngoscope / bronchoscope consists of the various components^{6,7} (Figure 1,2):

a. Handle: This includes an adjustable eyepiece for viewing, a lever for controlling the bending section of the tip, the suction button, and the access port to the suction channel.

b. Insertion cord: It is the flexible portion inserted into the patient and over which the endotracheal tube (ET tube/ ETT) is passed. It has light and image transmission bundles, the suction channel, and the tip bending control wires. The outside diameter of the insertion cord is what determines the size of the smallest ETT that can be used.

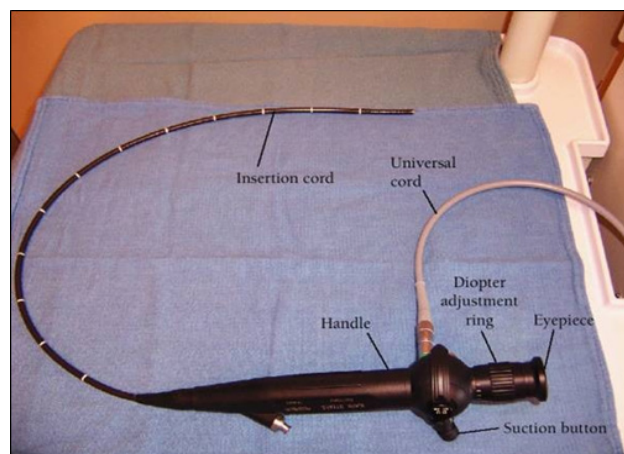


Figure 1. Components of Fibreoptic Bronchoscope.

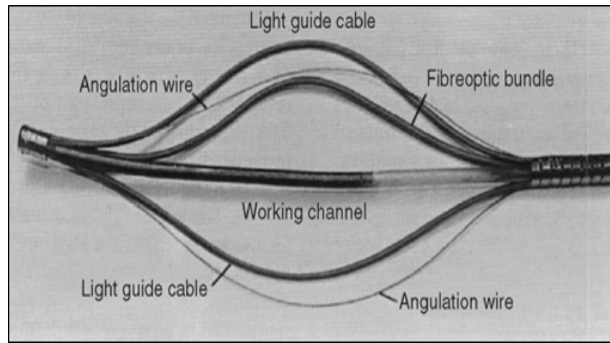


Figure 2. Inside a Fibre-Optic Bronchoscope (FOB) insertion cord⁶.

Light is transmitted through one or two light transmission bundles to the tip of the FOB. The suction or working channel can be used to suction secretions, spray local anesthetics, pass various biopsy and brush instruments, or insufflate oxygen.

c. The universal cord: It contains the light transmission fibre bundle and electrical wiring for the automatic exposure system. It is plugged into the light source before use of the FOB. The venting connector is where the Ethylene Oxide (ETO) sterilization-venting cap and leakage tester are placed. When the ETO cap is attached, it vents the interior of the FOB to equalize internal and external pressures. The ETO cap must be installed when FOB is subjected to gas sterilization and aeration and during airfreight transportation. The ETO cap must be removed before immersion of the FOB into water or disinfectant solution or when the FOB is in use.

d. The light source: An intense light is generated and is focused on the proximal end of the light guide cable by a source lens or a spherical reflecting mirror.

Diameter of the insertion cord, length of the insertion cord, diameter of the working channel, degree of bending of the tip and field of view vary with different sizes, which are designed based on the age of patients and the type of application. Field of view ranges between 75° to 120° and the tip can be bent up and down between 120° to 180°^{6,7}.

3. Uses of Fibreoptic Bronchoscopy

FOBs have been used for diagnostic and therapeutic

procedures of airways. In anaesthesia practice, FOB is used for oral or nasal intubation, intubation through LMAs, for retrograde intubation, confirmation of double lumen tube placement, etc. FOB can be used in evaluation of preoperative or post-extubation stridor, diagnosis of acute atelectasis or unintentional endobronchial intubation causing unexpected hypoxemia, ETT blockage by secretions, kinking, or cuff herniation and incidental discoveries of laryngeal polyps or other airway lesions. Indications are listed in Table 1⁶.

Table 1. Indications for Fibreoptic Intubation

1. Routine intubation
2. Difficult intubation
 - a. Known or anticipated
 - b. Unanticipated failed intubation
3. Compromised airway
 - a. Upper airway
 - b. Lower airway (tracheal compression)
4. Intubation of the conscious patient preferred
 - a. High risk of aspiration
 - b. Movement of neck not desirable
 - c. Known difficult mask ventilation
 - d. Morbid obesity
 - e. Self-positioning
5. High risk of dental damage
6. Previous tracheostomy or prolonged intubation

4. Preparation of Equipment before FOB

a. Fibreoptic bronchoscope and cart: The cart is necessary for easy transport and have stable shelves for FOBs, a light source, endo camera, drugs for application of topical anaesthesia, and various other airway supplies such as gauzes, tongue blades, intubating and nasal airways, cotton-tipped swabs, bronchoscopy swivel adapter, lubricant, and endoscopy masks, which may be needed for fibreoptic intubation (Figure 3). The cart can be integrated with difficult airway cart. In the OT, the fibreoptic cart is placed at the left side of the endoscopist, FOB is connected to the light source, the light is turned on, and the focus is adjusted by looking at written material until a clear view is obtained. The insertion cord of the FOB and the ET are placed in warm water; the insertion

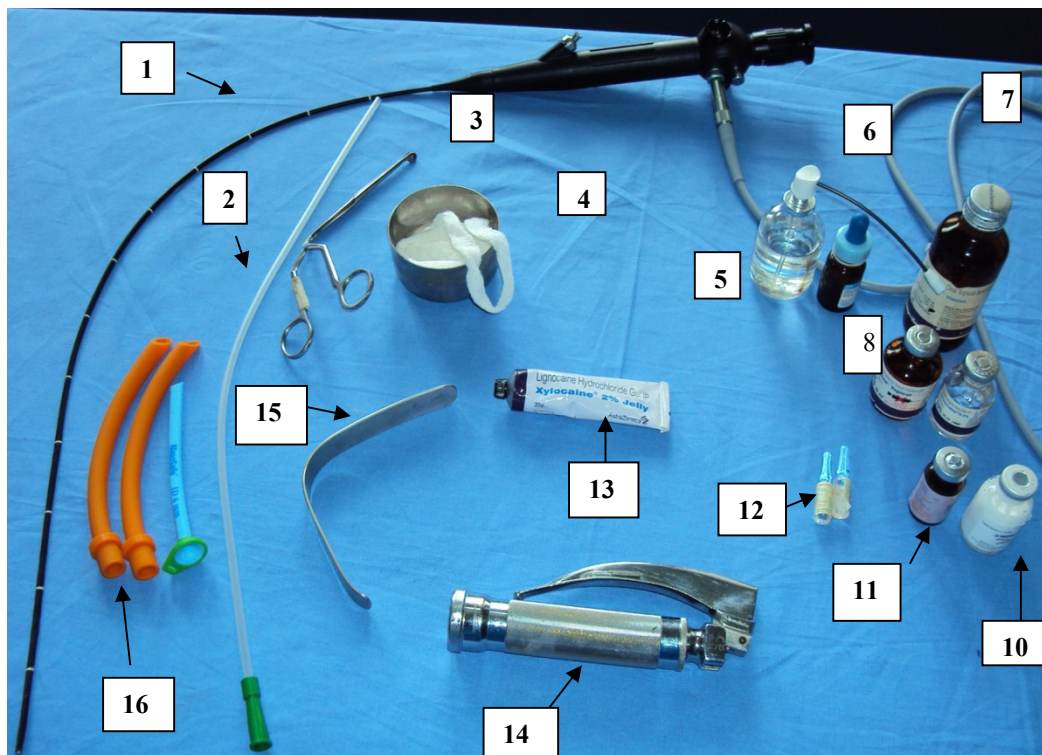


Figure 3. Set up for flexible fiberoptic nasotracheal intubation. 1. Flexible fiberoptic scope, 2. Suction catheter, 3. Magill's forceps, 4. Lignocaine-soaked gauze for nasal packing, 5. Lignocaine spray, 6. Nasal decongestant, 7. 2% lignocaine viscous solution, 8. 4% lignocaine, 9. 0.5% Bupivacaine, 10. Propofol, 11. Midazolam, 12. Glycopyrrolate, 13. Lignocaine jelly, 14. McIntosh laryngoscope, 15. Tongue depressor, and 16. Nasal airways.

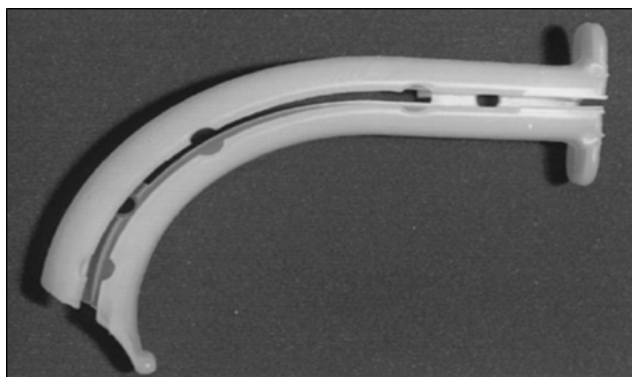


Figure 4. Berman Airway.




Figure 5. Ovassapian airway.

cord, to prevent fogging and the ET tube, to soften and to improve its pliability. (Commercial defogging solution may be used instead). Suction is kept ready.

b. Ancillary Equipment: These include intubating airways, (Figure 4&5) nasopharyngeal airways, endoscopy masks, and bronchoscopy swivel adapters. **Some examples of**

intubating Airways are Berman II intubating airway (disposable), Ovassapian fibreoptic intubating airway and Patil fibreoptic airway (aluminium). **Endoscopy Masks** are face masks with an endoscopy port to assist fibreoptic intubation in an anesthetized patient being ventilated by face mask. Because a rubber diaphragm covers the port, an air leak is not developed and mask ventilation can be continued throughout the procedure.

5. Fibreoptic Intubation - Approaches

FOB intubation can be performed by oral or nasal approach and in an awake patient or an anaesthetised patient. Indications and procedures vary with individual approaches.

5.1 General Principles of FOB Intubation in Conscious Patient

Indications: Awake Intubation (AI) with or without conscious sedation is indicated if airway is compromised or difficult intubation is expected. Other possible indications include patients at high risk for gastric aspiration, unstable cervical spine, morbid obesity, etc. FOB intubation is easier in the awake patient because the tongue does not fall back in the pharynx, and spontaneous ventilation tends to keep the airway open. In addition, by deep breathing the patient can assist the operator in locating the glottis when the airway anatomy is distorted.

Preparation: Good psychological, pharmacologic preparation of the patient, monitoring and delivery of oxygen during preparation and the procedure,

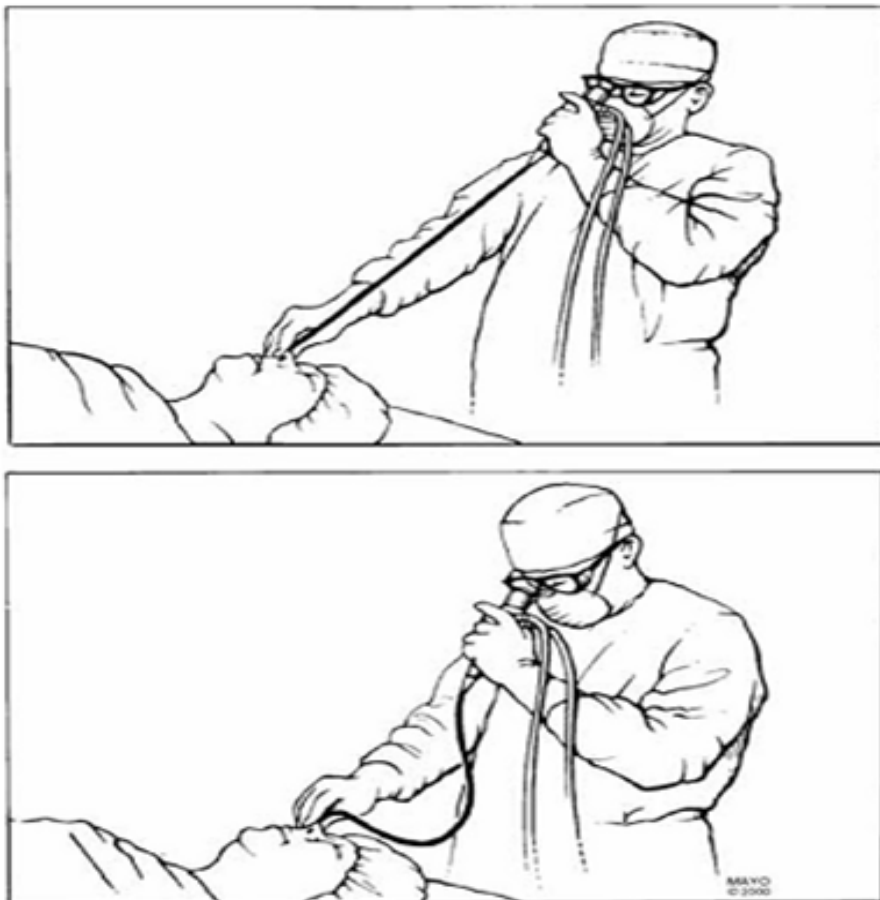

Figure 6. Correct technique of manipulating a fibreoptic bronchoscope through a tracheal tube (top); Wrong technique with curvature in the bronchoscope, making manipulation difficult (Mayo Clinic- 2003).

adequate topical anaesthesia, a good endoscopist and a well-functioning FOB are the secrets for success of the procedure. The insertion cord should always be kept straight and taut while introducing and manoeuvring inside (Figure 6).

Sedation and dry FOB access are the main goals of premedication. Conscious sedation is desirable to minimize awareness of the procedure and to increase the patient's acceptance, provided that safety is not compromised. Patient should be able to follow verbal commands and maintain adequate oxygenation and ventilation. Diazepam 5 to 10 mg (oral), midazolam 1 to 3 mg (IM), or 10 to 20 mg (oral), provide adequate sedation. Fentanyl remifentanyl, fentanyl with midazolam, and recently, dexmedetomidine have been used beneficially.

Anti-sialogogues (glycopyrrolate 0.2 mg intravenous, 15 mins before) reduce secretions, increase visibility and may allow for better action of local anaesthetic applied locally, preventing its dilution.

Oxygen is provided by nasal cannula at a flow rate of 3 L/min for awake FOB. Pharyngeal, laryngeal, and tracheobronchial reflexes can be obtunded with topical anaesthesia of mucous membranes

6. Techniques of Insertion^{6,7}

6.1 FOB Orotracheal Intubation of the Conscious Patient

a. Topical Anaesthesia: For oropharynx, 4% solution or a 10% aerosol of lignocaine spray provides excellent topical anaesthesia by abolishing pain sensation and obtunding gag and swallowing reflexes. For larynx and trachea, 4% lignocaine can be given by translaryngeal injection technique or sprayed through the FOB. Nebulisation with lignocaine is also described. Lignocaine 5% is applied to the base of the tongue and to the anterior tonsillar pillars with a tongue blade at approximately 60 to 90 seconds after translaryngeal injection. This manoeuvre checks the adequacy of the oropharyngeal topical anaesthesia by the lignocaine spray and supplements the block if it is not adequate. The Spray-As-You-GO (SAYGO) is another technique of topical anaesthesia, with spraying of the anaesthetic through the suction channel of an advancing

FOB (Epiglottis, vocal cords, anterior wall; incremental doses are sprayed on the walls of the tracheobronchial tree). An epidural catheter (internal diameter 0.5 to 1 mm cut to the length of the insertion cord) through the suction channel can deliver fine spray of the local anaesthetic. Bilateral superior laryngeal and lingual nerve blocks supplement airway block.

b. Procedure: The head is put into a neutral position, an airway intubator is placed in the mouth, the oropharynx is suctioned, and the lubricated ET is placed 4 to 5 cm inside the intubating airway. The fourth and fifth fingers of the right hand hold the ET to prevent premature advancement of the ET, while the index finger and thumb advance the FOB through the ET. As the FOB is advanced toward the oropharynx, the white pharyngeal surface of the airway and the patient's soft palate and uvula come into view. As the FOB is advanced, its tip is deflected anteriorly to expose the epiglottis and vocal cords. In the presence of a large, floppy epiglottis, the tip of the FOB must be manipulated underneath the epiglottis to visualize the vocal cords (Figure 7). Extending the head at the atlanto-occipital joint and keeping the mouth closed keeps the epiglottis away from posterior pharyngeal wall. Sometimes, an assistant must perform a jaw thrust or pull the tongue forward to facilitate glottic exposure. These manoeuvres increase the pharyngeal space by elevation of the tongue and epiglottis away from the posterior pharyngeal wall. This improves visualization of the larynx and provides more room to manoeuvre the FOB tip.

After the vocal cords are visualized, they are maintained in *the centre of the field of view* and the laryngeal inlet and tracheal lumen come into view. The FOB is then advanced into the mid trachea, and the ET is slipped over the firmly held stationary FOB into the trachea. Ideally, the tip of the ET is positioned 3 to 4 cm above the carina by direct visualization through the FOB. The oral approach is somewhat more difficult than the nasal approach because of the sharp curve leading from the oral cavity into the larynx. Orientation of the leading-edge bevel is the most important determinant of successful passage of the ET. Advancing the ET while instructing the patient to take a deep breath improves successful passage. An ET made more pliable by placement in warm water may also maximize success. Additional topical anaesthesia applied through the FOB improves conditions for intubation.

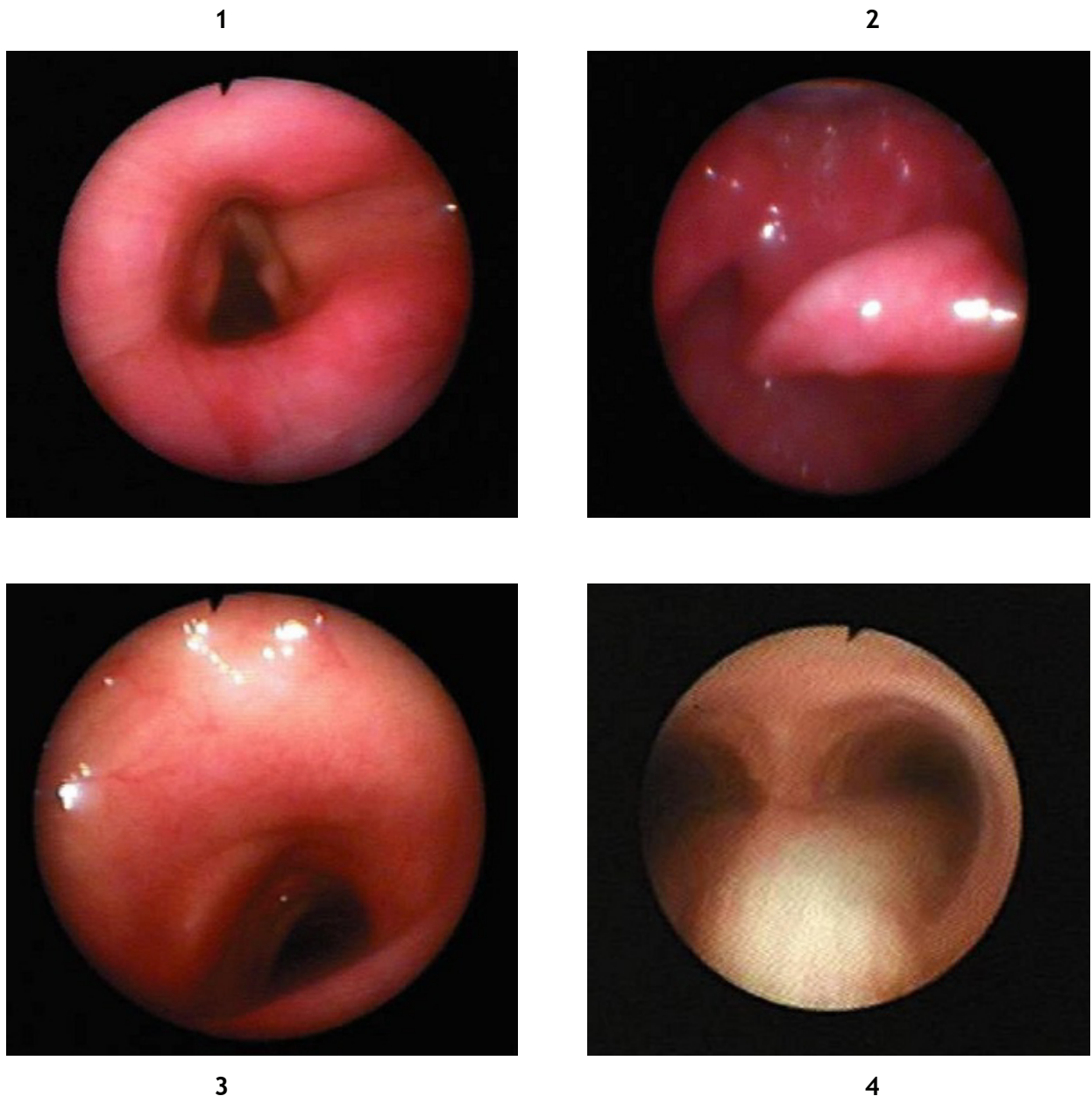


Figure 7. Fibreoptic bronchoscopic view: 1. Epiglottis, 2. Vocal cords, 3. Tracheal rings, and 4. Carina.

6.2 FOB Nasotracheal Intubation of the Conscious Patient

a. Topical Anaesthesia: The more patent nostril is selected and filled with 2% lignocaine gel or 4% lignocaine (3 ml) soaked gauze can be packed into the nostril, with / followed by oxymetazoline (0.05%). These agents provide topical

anaesthesia and shrinkage of the nasal mucosa. Maximal anaesthetic and vasoconstrictive effect is achieved in 4-5 mins. Laryngotracheal anaesthesia is achieved by translaryngeal injection or by spraying through the FOB during the process of intubation. Topical anaesthesia to the oropharynx is not needed because the gag reflex is not stimulated by the nasal route.

b. Procedure: Nasotracheal intubation is often easier than the oral approach because the FOB is usually pointed straight at the glottis as it enters the oropharynx, there is no sharp turn to negotiate, and the vocal cords are usually visible from a distance. Either the ET is placed in the nostril first and the FOB is passed through it or the ET is mounted over the FOB, which is then passed through the nostril. Placing the ET first avoids the possibility of nasal secretions covering the objective lens and obscuring the view, and a tight nasal passage can be recognized when the FOB is being advanced. Once the FOB has been passed through the ET into the trachea, advancement of the ET over the FOB is easily accomplished. The disadvantages of placing the ET into the nostril first are- increased possibility of causing nasal bleeding and, in some patients, the direction established by the ET prevents manipulation of the FOB into the glottis. The main disadvantage of passing the FOB first is that the adequacy of the nasal passage cannot be judged. If ETT is first passed, the ET tip is placed in the oropharynx, secretions are suctioned through the ET. Then the lubricated FOB is advanced through it into the oropharynx. In 80% to 85% of patients the epiglottis and vocal cords are seen with minimal or no manipulation of the tip of the FOB. In heavily sedated patients or in elderly, edentulous patients, the tongue and pharyngeal tissue may fall back and block the exposure of the larynx and vocal cords. Extending the head, applying jaw thrust, or pulling the tongue forward often helps in visualizing the vocal cords. The FOB is advanced into the mid-trachea, followed by the ET. With nasotracheal intubation the incidence of the ET meeting resistance and not entering the trachea is relatively low. However, to improve successful ET passage the ET should be turned *90 degrees clockwise* from its usual orientation so that the *bevel is facing up*, thus avoiding the epiglottis. This is the opposite of the ET orientation recommended for oral fiberoptic intubation.

6.3 Fiberoptic Intubation in the Anesthetized Patient

FOB intubation with the patient under general anaesthesia is accomplished with the patient either breathing spontaneously or paralyzed and receiving controlled ventilation. The main disadvantage of intubation under general anaesthesia is that the tongue and pharyngeal

tissues lose their tonicity and close down the pharyngeal space, blocking visualization of the larynx. To minimize apnoea time when the patient is paralyzed and to facilitate laryngeal exposure, an assistant is needed. The assistant will mount the ETT on the lubricated FOB and have it ready to hand to the anesthesiologist as soon as the anaesthesia mask is removed; apply jaw thrust to maintain an open oropharynx; and observe the apnoea time and monitor the patient. The endoscopy cart is placed at the head of the table on the left side of the patient while the assistant stands on the patient's left side facing the anesthesiologist.

If the patient is breathing spontaneously: Supplemental O₂ may be provided by nasal cannula, by blow-by from the anaesthesia circuit, by use of an insufflation catheter, by standard face mask used over only the oropharynx or nasopharynx, or by endoscopy mask or nasopharyngeal airways. If patient is apnoeic, or has difficult airway, ventilation may be performed with an endoscopy mask or a small standard face mask applied over the oropharynx or nasopharynx or with difficult mask ventilation, jet ventilation by a modified Fogarty embolectomy catheter or transtracheal catheter can be used or even 5 L of O₂ by nasal cannula.

a. FOB Orotracheal Intubation of the anesthetized Patient: After GA and muscle relaxation are established, the intubating airway is placed inside the mouth, and the oropharynx is suctioned. Ventilation is resumed by mask for 30 to 60 seconds. The anaesthesia mask is removed, and the anesthesiologist grasps the body of the FOB (with the ETT mounted) with the left hand and the tip of the insertion cord with the right hand. The tip of the insertion cord is placed inside the intubating airway and advanced into the oropharynx. The assistant applies a jaw thrust, and this is the most important step in F O intubation under G A. If no intubating airway is available, gentle pull of the patient's tongue by the assistant forward away from the palate moves the epiglottis away from the posterior pharyngeal wall, thus assisting exposure of the vocal cords. The assistant may also use both hands to apply jaw thrust, while simultaneously opening the mouth by downward pressure on the chin. Exposure of the vocal cords is difficult without the intubating airway, as the FOB is likely to dangle away from the midline position. Once the FOB is in mid-trachea, the ET is advanced with

a rotating motion into the trachea, the tip about 3 cm above the carina. The bevel-down orientation (Murphy eye up for a PVC ET tube) will facilitate entry into the trachea by slipping past the potentially obstructing right arytenoid cartilage. If the ET faces resistance and does not enter the trachea, it is pulled back, rotated 180 degrees to the right or left, and then advanced while the assistant continues to apply jaw thrust. Based on the duration of attempt, the FOB may be removed followed by ventilation or few types of ventilation provided to ET tube followed by its removal.

b. FOB Nasotracheal Intubation of the Anaesthetized Patient: Obstruction to passage of the FOB by nasal approach under G A by the tongue falling onto the posterior pharyngeal wall is prevented by placing oropharyngeal airway. Vasoconstrictor may be instilled into the nostril before or after induction of anaesthesia. As soon as the mask is removed from the patient's face, the FOB is inserted into the selected nostril and advanced toward the larynx and trachea. The assistant applies jaw thrust to keep the posterior pharyngeal space open. After the FOB is placed in the mid-trachea, the ET is threaded over the FOB into the trachea.

6.4 FOB and Special Airway / Intubation

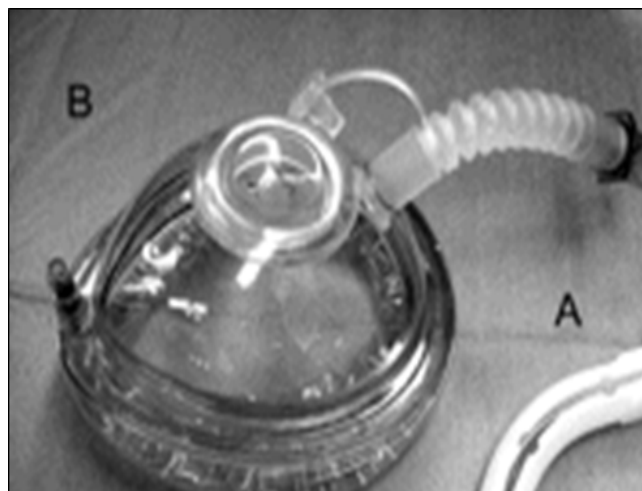


Figure 8. Endoscopy mask.

Applications

- i. FOB is used in as part of Rapid Sequence Induction and Intubation (RSI). ii. It can be used for intubation using an endoscopy mask. (Figure 8) The mask has endoscopy port for FOB intubation; it can also allow oxygen supplementation or positive-pressure ventilation of the anesthetized and paralyzed patient. Intubating airway is mandatory for success with this technique. Endoscopy mask can also be used for nasotracheal intubation.
- ii. Anaesthesia can be maintained through a nasopharyngeal airway to allow time for unhurried endotracheal intubation. For orotracheal intubation, a binasal airway is placed in the nostrils and connected to the anaesthesia breathing system. Using an intubating airway, FOB with the ET is inserted through the airway to perform the intubation. For nasotracheal intubation, a nasopharyngeal airway mounted with an ET adapter is inserted in one nostril and is used to maintain anaesthesia. The FOB with the ET is passed through the other nostril for ET intubation.

Table 2. Disadvantages of FOB⁶

<p>A. Related to the Fibreoptic Bronchoscope</p> <ul style="list-style-type: none"> Fragile Expensive Separate light source may be required Time consuming to clean and disinfect Vision is obscured easily by secretions or blood <p>Related to the Intubation Technique</p> <ul style="list-style-type: none"> Different skill is required than in rigid laryngoscopy Lack of expertise is a disadvantage if the practitioner is not taught during training. Most of the lumen of the endotracheal tube is blocked by the fibreoptic bronchoscope Passage of the endotracheal tube through the vocal cords is blind Advancement of the endotracheal tube into the trachea may pull the fibreoptic bronchoscope out of trachea Resistance during advancement of endotracheal tube into the trachea is more common
--

Combining Fiberoptic Intubation with Other Intubation or Airway Management Techniques: FOB can be used with a rigid laryngoscope, supraglottic airway devices, Combitube or in association with techniques such as retrograde intubation, blind nasal intubation and light wand intubation.

Disadvantages And Complications of Fiberoptic Intubation: Two major disadvantages of the FOB itself are the expense of the instrument and its size. (Table 2) Cleaning, sterilization, and storage are time consuming. Small amounts of secretions or blood may completely obscure the view and interfere with airway evaluation and endotracheal intubation. As the FOB is advanced through the tracheal ET, the effective lumen left for air exchange is compromised and airway resistance increases greatly when compared with the rigid bronchoscope, which provides a large lumen for air exchange.

6.5 Cleaning and Disinfecting

The FOB should be washed immediately and the working channel flushed with clear water to remove secretions before they dry. A cleaning brush should be inserted through the suction port downward toward the tip of the insertion cord (retrograde insertion increases the risk of damage to the internal lining of the suction channel). The FOB can be immersed in disinfecting solution after ensuring that there are no damages/ leaks (which must be checked) as the liquid can penetrate the scope. A leakage tester supplied by the manufacturer can be used.

Disinfection: The working channel may be flushed with a syringe of disinfecting solution. Such as 2% alkaline glutaraldehyde. Recommended immersion times after use in noninfected patients vary from 10 minutes for glutaraldehyde to 20 minutes for the iodine-containing solutions. Each solution is potentially caustic to the materials in the FOB; thus, the manufacturers' recommendations for disinfectant concentration and maximum soaking time should be carefully observed. The FOB should be washed and the working channel suctioned with water to remove all traces of the disinfectant solution. Suctioning air for 10 to 15 seconds dries the inside of the suction channel.

Sterilisation: This is needed if the patient has transmissible diseases like tuberculosis or if the next patient has immune deficiencies. Complete sterilization

of the FOB can be accomplished with ETO gas, which may take 24 hours.

7. Fiberoptic Intubation in Children and Infants

Smaller FOBs, including ultrathin fiberoptic endoscopes that have directable tips are available allowing FOB intubation in even preterm neonates (for ET tubes of 2.5 mm ID size). Pediatric FOBs have smaller working channels (1.2 mm internal diameter) and have a 2.8 mm external diameter so that they can accommodate an ET as small as 3.5 mm ID. All indications for fiberoptic endoscopic airway management in adult patients can also be applied to paediatric patients. Sedatives are used based on weight and child's condition and Benzodiazepines (BDZ) and short acting opioids may be beneficial; ketamine and propofol can be used alongside in increments. General anaesthesia with maintenance of spontaneous ventilation is an alternative when abnormal airway anatomy is present and difficulty with the patient's cooperation is anticipated. Both inhalational and intravenous induction and maintenance techniques have been described. Local anaesthesia in paediatrics can prevent laryngospasm and allows better patient acceptance and improves success rate. Doses have to be adjusted and nebulized lignocaine has special benefit in administration.

8. References

1. Ikeda S. Atlas of Flexible Bronchofiberscopy, Baltimore, University Park, 1974.
2. Murphy P. A fibre-optic endoscope used for nasal intubation. *Anaesthesia*, 1967; 22:489-491. <https://doi.org/10.1111/j.1365-2044.1967.tb02771.x>. PMID:4951601.
3. Conyers AB, Wallace DH, Mulder DS. Use of the fiber optic bronchoscope for nasotracheal intubation: Case report. *Can Anaesth Soc J*, 1972; 19:654-656. <https://doi.org/10.1007/BF03006110>. PMID:4635833.
4. Taylor PA, Towey RM. The broncho-fiberscope as an aid to endotracheal intubation. *Br J Anaesth*, 1972; 44:611-612. <https://doi.org/10.1093/bja/44.6.611>. PMID:5045554.
5. Stiles CM, Stiles QR, Denson JS. A flexible fiber optic laryngoscope. *JAMA*, 1972; 221:1246-1247. <https://doi.org/10.1001/jama.221.11.1246>, <https://doi.org/10.1001/jama.1972.03200240028007>.

6. Melissa W, Andranik O. Fiberoptic endoscopy. In: Benumof's Airway Management, Ed. Hagberg; 2nd ed. Mosby Elsevier; 2007. p. 399-438. <https://doi.org/10.1016/B978-032302233-0.50025-1>. PMID:17110498 PMCID:PMC1775017.
7. Orebaugh, Steven L. Atlas of airway management: Tools and techniques: 1st Edition: Lippincot Williams and Wilkins; 2007. p. 122-134.
8. Darling JR, Keohane M, Murray JM. A split laryngeal mask as an aid to training in fibreoptic tracheal intubation. A comparison with the Berman II intubating airway. *Anaesthesia*, 1993; 48:1079-1082. <https://doi.org/10.1111/j.1365-2044.1993.tb07533.x>. PMID:8285331.
9. Ovassapian A, Yelich SJ, Dykes MH, Golman ME. Learning fibreoptic intubation: Use of simulators v. traditional teaching. *Br J Anaesth*, 1988; 61:217-220. <https://doi.org/10.1093/bja/61.2.217>. PMID:3415894.
10. Dykes MH, Ovassapian A. Dissemination of fibreoptic airway endoscopy skills by means of a workshop utilizing models. *Br J Anaesth*, 1989; 63:595-597. <https://doi.org/10.1093/bja/63.5.595>. PMID:2605077.