

# Comparison of Intrathecal Fentanyl and Femoral Nerve Block (FNB) for Post Operative Analgesia in Patients Undergoing Surgeries for Fracture Femur

Bhargavi Sanket\*, Swathi Nagaraja, Sudheesh Kannan and Nethra S. Surhonne

Department of Anaesthesiology, Bangalore Medical College and Research Institute, Bangalore – 560002, Karnataka, India; bhargavi\_doc@yahoo.com

## Abstract

**Background and Aims:** Femoral Nerve Block (FNB) has been advocated for pain relief in patients with fracture femur but its effect on post operative analgesia is less studied. The aim was to compare intrathecal fentanyl and FNB in terms of duration of complete analgesia and effective analgesia in the postoperative period and also for pain relief during positioning. **Material and Methods:** 64 ASA I-II patients, 18-60 years of age, with fracture shaft femur undergoing corrective surgery were randomly allocated to 2 groups, Group B and F. In the preoperative room, patients underwent FNB under ultrasound guidance. Group B patients were given bolus of 20 ml of 0.5% bupivacaine and Group F patients 20 ml normal saline. Following this, Group B patients received 2.5ml, 0.5% bupivacaine (heavy) with 0.5 ml normal saline. Group F patients received 2.5 ml, 0.5% bupivacaine (heavy) with 0.5 ml fentanyl (25 micrograms). Intraoperative and postoperative monitoring of vitals was done. Time of complete analgesia (VAS 0) and effective analgesia (VAS  $\geq$  4), perioperative complications were noted. **Results:** Demographic parameters were comparable. The mean duration of complete analgesia was  $273 \pm 49.22$  min in group F and  $384.28 \pm 89.04$  min in group B ( $p = 0.01^*$ ). The duration of effective analgesia was  $329.28 \pm 50.86$  min in group F compared to  $457.14 \pm 83.1$ min in group B ( $p = 0.004^*$ ). Postoperative VAS scores were significantly lower in group B than in group F. Incidence of nausea and vomiting was higher in group F (6 in group F and 1 in group B). **Conclusion:** FNB administered just before spinal anaesthesia provides better postoperative analgesia compared to intrathecal fentanyl.

**Keywords:** Femoral Nerve Block, Femur, Analgesia, Fentanyl

## 1. Introduction

The word 'fracture' is synonymous with severe pain irrespective of the bone involved. Femur being the longest bone in the human body is associated with intolerable fracture pain. The saga with pain continues even in the postoperative period and if the pain is poorly managed it can delay rehabilitation process and functional recovery. Multiple postoperative analgesic modalities have been undertaken with use of intravenous or intrathecal opioids

being a popular choice though associated with multiple side effects<sup>1</sup>. With peripheral nerve blocks gaining popularity in present day anesthesia practice as effective analgesic modalities<sup>2</sup>, Femoral Nerve Block (FNB)<sup>3</sup>, *Fascia iliaca* Compartment Nerve Block (FICNB)<sup>4</sup> and even Lumbar Plexus Block (LPB)<sup>5</sup> have been studied. Femoral Nerve Block (FNB) has been popularly evaluated in femur fracture patients to aid optimal positioning for subarachnoid block in the operating theatre<sup>6</sup> and few studies have evaluated the efficacy of single shot FNB as

\*Author for correspondence

a modality for early postoperative analgesia. Hence this study was undertaken to compare FNB and intrathecal fentanyl in decreasing postoperative pain in patients undergoing corrective surgery for fracture shaft femur.

## 2. Material and Methods

This prospective randomized double blind controlled study was undertaken between January and June 2018 after obtaining institutional ethical committee clearance. 64 ASA I and II patients, aged between 18 to 60 years with fracture shaft of femur posted for fracture fixation under subarachnoid block (SAB) and giving consent for the study were enrolled. Patients with coagulopathies [platelet count <50,000/ $\mu$ l, INR (International normalized ratio)>1], uncontrolled diabetes and hypertension, cardiorespiratory, renal, endocrine, hepatic disorders, neurological and psychiatric disturbances, skin lesions at the site of SAB/FNB, history of drug allergy were excluded from the study. The recruited patients were allocated randomly into 2 groups (Group B and F) using computer generated randomisation sequence [[www.random.org](http://www.random.org)]. Group B received FNB with 20 ml of 0.5 % bupivacaine followed by SAB with 0.5 % bupivacaine heavy and 0.5 ml normal saline. Group F received FNB with 20 ml normal saline followed by SAB with 0.5 % bupivacaine heavy and 25  $\mu$ gms fentanyl (0.5 ml). After preanesthetic examination, overnight fasting of 8 hours was advised and premedicated with oral 150 mg ranitidine and 0.25 mg alprazolam. Patients were shifted to the preoperative room on the morning of surgery and connected to routine monitors and basal Heart Rate (HR), Oxygen Saturation (SpO<sub>2</sub>), Noninvasive Blood Pressure (NIBP)

were recorded. 18 guage cannula was secured and ringer lactate at maintenance rate was initiated. The patients were trained to grade the pain with VAS (Visual analogue scale) (Table 1).

In the preoperative room, with patient in supine position, FNB was administered under ultrasonographic (USG) guidance<sup>7</sup>. For this a linear USG probe of 6-13MHz was placed in the femoral crease, over the femoral artery pulsations under aseptic precautions. The femoral nerve was identified lateral to the femoral artery. Under USG guidance, the tip of a 25 Guage spinal needle was placed lateral to femoral nerve between the two layers of *Fascia iliaca* that surround the nerve. In Group B patients 20 ml of 0.5 % bupivacaine was administered and in Group F patients 20 ml of normal saline. Confirmation of the correct deposition of local anesthetic was done by observing the femoral nerve being pushed away by the injection. VAS scores were recorded before, 5 and 10 minutes after block administration along with vitals.

The patient was then shifted to operation theatre and monitoring of vitals was continued with recording every 5 minutes till end of surgery. SAB was administered under aseptic precautions using a 25 Gauge spinal needle at L3 L4 space in sitting position in all patients. Group B patients received 2.5 ml of bupivacaine (heavy) with 0.5 ml normal saline and Group F 2.5 ml of bupivacaine (heavy) with 0.5ml (25 micrograms) fentanyl. The drug solutions for both SAB and FNB was prepared by a coinvestigator who was not further involved in the study.

Post operatively VAS scores for pain was recorded and rescue analgesia of 75 mg intramuscular injection diclofenac was administered when the VAS score was >3. Duration of Complete Analgesia (time from the administration of FNB till the VAS score becomes >1) and duration of effective analgesia (time from the administration of FNB till the patient demands rescue analgesia) was noted.

Recording of vitals was continued postoperatively every 30 minutes for first 2 hours, then hourly till the rescue analgesia was administered. Patients complaining of pain intraoperatively were converted to general anesthesia and excluded from the study. Occurrence of complications such as hypotension (fall in mean arterial pressure > 25 % from baseline values), bradycardia (Heart rate < 60 bpm) respiratory depression (respiratory rate <8/min), nausea, vomiting, headache, persistent weakness/

**Table 1.** VAS (Visual Analogue Scale)

VAS Score	Features
0	No Pain
1-2	Mild Pain
3-6	Moderate Pain
7-9	Severe Pain
10	Worst Possible Pain

paresthesia in the postoperative period for > 24 hours was noted. Hypotension was treated with intravenous mephenteramine 3mg and bradycardia with intravenous 0.6 mg atropine.

Sample size was calculated based on observations from previous studies. Keeping the power of the study at 80 % and confidence interval at 95 % to detect at least 30 minute difference in the duration of analgesia between the 2 groups a minimum of 29 patients was required for each group using [www.openepi.com](http://www.openepi.com). For a better validation and to compensate for drop outs 32 patients were included in each group.

### 3. Results

64 patients were included in the study. 2 patients (both from group F) were excluded from the study as they complained of intraoperative pain and were converted to general anesthesia. The demographic characteristics and mean duration of surgery was comparable between the 2 groups (Table 2).

The preoperative VAS scores were comparable and indicated a severe pain associated with the fracture. At 5 and 10 minutes following administration of FNB, the VAS scores are significantly lower in group B ( $p=0.004^*$  and

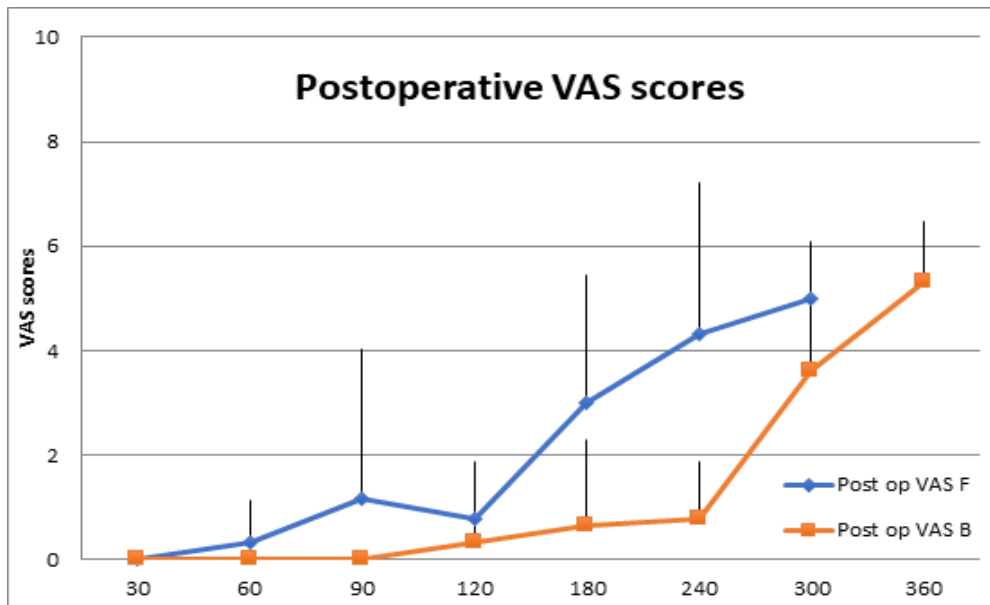
**Table 2.** Demographics

Parameters	Group B (n=32)	Group F (n=30)	P value
Age (yrs)	41.1 ± 11.19	49.14 ± 14.7	
Sex (M:F)	15:17	14:16	
ASA Grade (I:II)	24:8	26:4	
Duration of surgery (min)	137.14 ± 29.2	117.8 ± 48.1	0.38
Pre operative basal VAS score	9.3 ± 1.03	9.0 ± 1.09	0.6
Maximum cephalad spread of sensory block (median)	T7	T6	

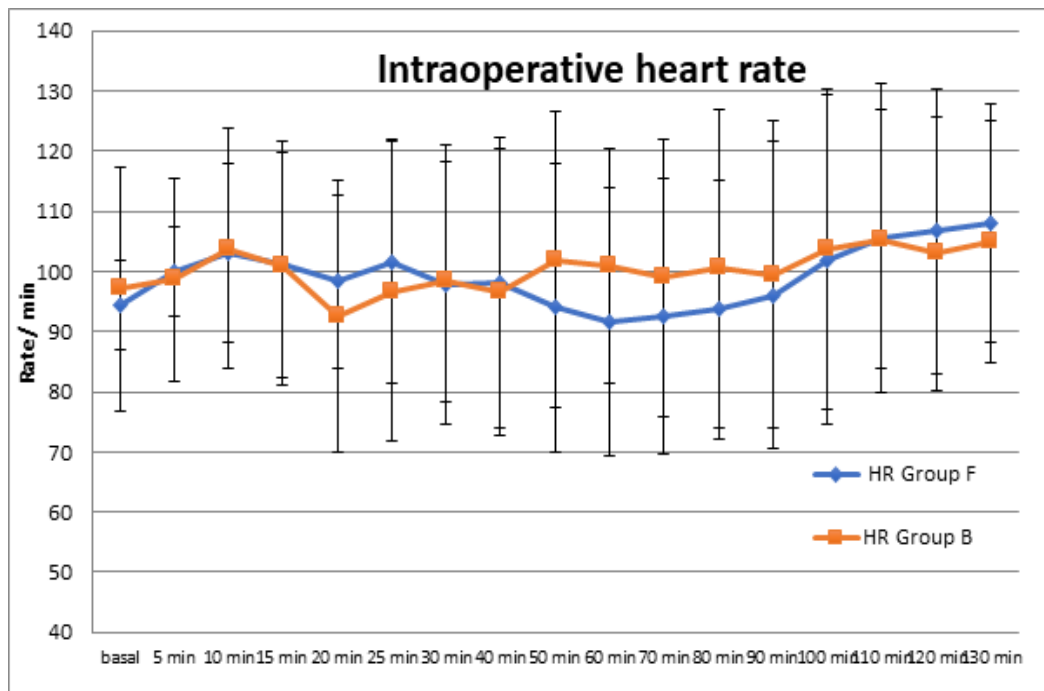
**Table 3.** Analgesic parameters

Parameters	Group B	Group F	P value
<b>VAS scores after block</b>			
5 min	6.66 ± 1.03	8.16 ± 0.48	0.004*
10 min	5.16 ± 1.32	8.33 ± 0.51	<0.001*
Duration of complete analgesia (VAS = 0) (min)	384.28 ± 89.04	273 ± 49.22	0.01*
Duration of effective analgesia (VAS < 4) (min)	457.14 ± 83.1	329.28 ± 50.86	0.004*

\* - statistically highly significant



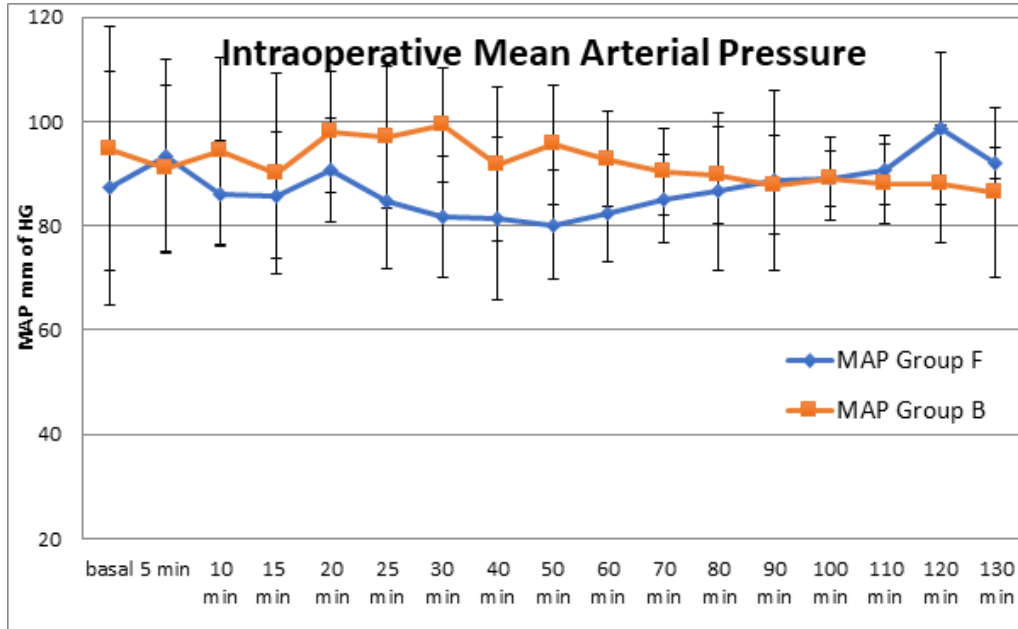
**Graph 1.** Post operative VAS scores



**Graph 2.** Intraoperative heart rate – there was no significant difference in heart rate at all time intervals.

$p < 0.001^*$  respectively). The post block and post operative VAS were significantly lower in group B (Graph 1) with

significantly longer duration of complete and effective analgesia. ( $p = 0.01^*$  and  $p = 0.004^*$  respectively) (Table 3).



**Graph 3.** Trends intraoperative mean arterial pressure. Mean arterial pressure was lower in group F from 15<sup>th</sup> min to 80<sup>th</sup> min, but was not statistically significant.

The hemodynamic parameters were comparable between the two groups (Graph 2). The Mean arterial pressure was lower in group F from 15<sup>th</sup> to 80<sup>th</sup> minute but was not statistically significant (Graph 3). Occurrence of adverse effects was not significant with 6 patients in group F and 1 patient in group B complained of nausea and vomiting.

## 4. Discussion

Subarachnoid block is the most popular anaesthetic modality for fracture femur fixation surgery<sup>8</sup>. Hence addition of intrathecal adjuvants became an easy and effective solution for postoperative analgesia. Intrathecal opioids provide segmental analgesia but are associated with systemic side effects with respiratory depression being the most dreaded. Fentanyl (10-30 µgms) became a popular choice having a fast onset of action of 10-20 minutes and short duration of action of 4-6 hours and hence minimal incidence of delayed respiratory depression<sup>9</sup>. Comparably, we observed a duration of complete analgesia of  $273 \pm 49.22$  minutes with

intrathecal fentanyl. This short duration of action was the only drawback as we did not observe any significant adverse effects of intrathecal opioid use<sup>9</sup>.

With FNB, we observed a significantly longer duration of complete analgesia of  $384.28 \pm 89.04$  minutes. With 20 ml of 0.75% Ropivacaine, Kulkarni *et al.*,<sup>3</sup> observed that FNB was associated with postoperative analgesia of upto 10 hours. The longer duration of action observed maybe attributed to the higher concentration of the local anaesthetic used. We restricted the dose and concentration of bupivacaine to minimize the cardiotoxic effects.

We observed a duration of effective analgesia of 6-9 hours with FNB though Amiri *et al.*,<sup>5</sup> observed that the demand for first analgesia postoperatively after a combined FNB and SAB was around 17 hours. This longer duration maybe again attributed to the combination of lignocaine and bupivacaine which was used and in larger volumes. Hence, we can prolong the analgesia duration of FNB by optimal selection of local anaesthetics with probable addition of adjuvants. However, this requires to be evaluated with further studies.

On the contrary, Rowlands and workers<sup>10</sup> observed that continuous FNB with placement of catheter was not beneficial in reducing pain on mobilization in the immediate post operative period and only a good analgesic at rest. This is probably because the study included fracture neck of femur patients in the study where the pain may also be mediated by sciatic and obturator nerves innervating the hip joint in close proximity to the fracture. Elsey *et al.*,<sup>11</sup> also reported lack of beneficial analgesic effect of FNB in pediatric patients with fracture femur postoperatively owing to the differences in mechanism of injury, type of fracture and surgical technique chosen. We included patients with fracture shaft femur where mainly femoral nerve is involved in the pain mechanism. Amiri *et al.*,<sup>5</sup> also studied patients with intertrochanteric fracture and observed FNB to be beneficial. Hence knowledge of the type of fracture femur and surgical technique before instituting the block is a must.

FICB which is an extension of the FNB and blocks both the femoral nerve and lateral femoral cutaneous nerve has been found to provide good analgesia post operatively in lower limb surgeries<sup>12</sup>. Kumie *et al.*,<sup>4</sup> observed that a single injection of FICB administered post operatively could provide long term analgesia with request for first analgesic dose delayed upto 5-8 hours and decreased diclofenac consumption.

Hence, the administration of FNB in the immediate post operative period may further prolong the duration of analgesia but we included FNB administration preoperatively in our protocol as earlier studies showed that FNB was effective in aiding positioning for SAB by significantly reducing fracture pain<sup>3,6</sup>. Kulkarni *et al.*,<sup>3</sup> observed that majority of the patients receiving FNB cooperated for SAB without the need for intravenous analgesics. Jadon *et al.*,<sup>6</sup> also observed that FNB was significantly better than intravenous fentanyl in providing analgesia preoperatively which aided in better quality of positioning for SAB. Also they found that after FNB, SAB was administered faster as compared to patients receiving Intravenous fentanyl. We observed similar results with VAS scores significantly reducing at 5 and 10 minutes after FNB was administered. Though we did not record the quality of positioning and time required for administration of SAB.

## 5. Conclusion

that FNB is a peripheral nerve block with good post operative analgesic potential in patients undergoing surgery for fracture shaft femur. It has the advantages of being associated with stable hemodynamics and minimal side effects. It is also beneficial in providing commendable analgesia during positioning for SAB. This maybe especially beneficial in the geriatric population. Prolongation of duration of analgesia by the choice of local anesthetics for a single injection approach or continuous approach with placement of a catheter maybe tried.

## 6. References

1. Andrew H. Intrathecal opioids in the management of acute post operative pain. BJACEACCP, 2008; 8(3):81-85.
2. Stein EB, Srikumaran U, Tan EW, Freehill MT, Wilckens JH. Lower- extremity peripheral nerve blocks in the perioperative pain management of orthopaedic patients. J Bone joint Surg Am, 2012; 94(22):e167.
3. Kulkarni A, Thatte WS, Tejeswi S. To know how Femoral Nerve Block (FNB) with 0.75% ropivacaine is an aid to Regional Anaesthesia (SAB) for femur and hip surgeries. Indian J App Res, 2015; 5(9):190-2
4. Kumie TH, Gebremedhn GE, Tawuye YH. Efficacy of *Fascia iliaca* compartment nerve block as a part of multimodal analgesia after surgery for femoral bone fracture. World J Emerg Med, 2015; 6(2):142-6.
5. Amiri HR, Safari S, Makarem J, Rahimi M, Jahanshahi B. Comparison of combined femoral nerve block and spinal anaesthesia with lumbar plexus block for postoperative analgesia in intertrochanteric fracture surgery. Anaesth pain, 2012; 2(2):32-5.
6. Jadon A, Kedia SK, Dixit S, Chakraborty S. Comparative evaluation of femoral nerve block and intravenous fentanyl for positioning during spinal anaesthesia in surgery for femur fracture. Indian J anaesth 2014; 58(6):705-8.
7. Hadzics textbook of Regional anaesthesia and acute pain management 2<sup>nd</sup> edition. 595-601.
8. Sandby-Thomas M, Sullivan G, Hall JE. A national survey into the perioperative anaesthetic management of patients for surgical correction of fractured neck of femur. Anaesthesia, 2008; 63:250-8.
9. Andrew HMB. Intrathecal opioids in the management of acute postoperative pain. CEACCP, 2008; 8(3):81-85.

10. Rowlands M, Walt Gv, Bradley J, Mannings A, Armstrong S *et al.*, Femoral Nerve Block Intervention in Neck of Femur Fracture (FINOF): a randomised controlled trial. *BMJ Open*, 2018; 8:e019650.
11. Elsey NM, Tobias JD, Klingele KE, Beltran RJ, Bhalla T *et al.*, A prospective, double-blinded, randomized comparison of ultrasound-guided femoral nerve block with lateral femoral cutaneous nerve block versus standard anesthetic management for pain control during and after traumatic femur fracture repair in the pediatric population. *J of Pain Res*, 2017; 10:2177-2182.
12. Yang L, Li M, Chen C, Shen J, Bu X. *Fascia iliaca* compartment block versus no block for pain control after lower limb surgery: A meta analysis. *J of Pain Res*, 2017; 10:2833-2841.